



**DATE PRESENTING CLINICAL SIGNS**

5/1/26 **History:** Yearly Echo as recommended per last echo. 4/10 - historic 2/6 murmur not heard; lungs clear  
**Pertinent abnormal PE/Chem/CBC/UA Results:** Labwork not attached.  
**Current medications:** None.

**PATIENT**

Ringo Idrovo **Blood Pressure:** N/A.  
**Sedation used:** Not required to complete full diagnostic ultrasound.  
**Pertinent previous ultrasound results:** 4/2025. See attached.  
**STAT:** Not requested.

**SPECIES**

Feline **Imaging performed by:** Stephanie Warga RDCS, RVT.

**BREED**

Domestic Shorthair

**SEX**

Neutered male

**AGE**

1/12/15

**WEIGHT**

13 lbs

**INTERPRETED BY**

Bradley Harris, DVM,  
DACVECC, DACVIM  
(cardiology)

**HOSPITAL NAME**

Banfield Abingdon

**REFERRING VET**

Dr. Simpson

**INVOICE**

75089

**ULTRASONOGRAPHIC EXAMINATION OF THE HEART**

The left atrium is normal in dimension. There are no distinct left atrial thrombi/clots or spontaneous echo contrast appreciated. The left ventricle is normal in dimension as well as wall thickness, and no evidence of restriction. Left ventricular systolic function is normal, with adequate contractility based on fractional shortening and systolic left ventricular dimensions. The right atrium and ventricle are subjectively normal in dimension and systolic function. There is evidence of systolic anterior motion of the mitral valve with trace mitral regurgitation. The tricuspid valve leaflets presented normal linear structure, extension in systole, and union in diastole without regurgitation. The left ventricular outflow tract demonstrated turbulent flow and subjective structural valvular integrity. The visible aorta is unremarkable. Pulmonary outflow tract assessment revealed normal valve structure, laminar flow, and appropriate diameter and distensibility. There is no evidence of semilunar valve insufficiency or pulmonary hypertension documented. There is no visible pericardial, pleural, or free peritoneal fluid noted.

FELINE CARDIAC PARAMETERS	BODY WEIGHT (kg)	HR (BPM)	IVSd (cm)	LVIDd (cm)	LVWd (cm)	FS (%)	EF (%)
NORMAL PARAMETER	-----	150-240	0.3-0.6	1.0-2.1	0.25-0.6	35-67	80-100
PATIENT	5.91 kg	200	0.47	1.43	0.51	42	88
FELINE CARDIAC PARAMETERS	LA/AO (M-mode)	LA/AO HEART BASE (Sisson)	LAD LA MAX 4 Chamber		LVOT VEL. (m/s)	RVOT VEL. (m/s)	IVRT (m/)
NORMAL PARAMETER	<1.5	1.6	0.7-1.7		<1.6	<1.3	40-60
PATIENT	NM	1.29	1.5		1.4	1.8	NM
Adapted from June Boon, Veterinary Echocardiography, 1998 Sisson D et al. JVIM 1991; 5: 232, Jacobs et al. Am J Vet Res 1985; 46:1705							

**ECG:**

The underlying rhythm is sinus in origin with an average rate of 200bpm. The R-R intervals are regular, with a uniform P-R interval that is within normal limits. There are rare (1) premature complexes with a wide QRS (>40ms), consistent with a ventricular origin. There are no ventricular couplets or runs of tachycardia documented. There is no evidence of atrioventricular block or atrial ectopy documented.

## ULTRASONOGRAPHIC FINDINGS

These findings are consistent with dynamic subaortic stenosis, as there is SAM present, but no convincing hypertrophy is identified. A ventricular arrhythmia is noted. In cats, ventricular arrhythmias are usually secondary to underlying structural heart disease. Causes include cardiomyopathy (e.g., hypertrophic, restrictive, arrhythmogenic, dilated) or secondary myocardial disease (e.g., hyperthyroidism, hypertension). Rarely, ventricular arrhythmias develop secondary to extracardiac conditions (e.g., neurologic disease, metabolic disease, fever, anemia, trauma, GI disease, DIC and sepsis).

## INTERPRETATION OF THE FINDINGS & FURTHER RECOMMENDATIONS

Given the absence of any underlying heart disease, no cardiac therapy will be recommended. In addition, there are no cardiac objections to fluid therapy or steroid use. Owing to the presence of an outflow tract obstruction, a follow up echo is recommended in another 6-12 months to make sure no progression has occurred. While therapy is not specifically indicated based on these findings, further diagnostics might help tailor therapeutic recommendations. Consider the following:

- Abdominal ultrasound to look for abdominal causes of VPCs (e.g., splenic/adrenal changes)
- Consider 24-48 hour ambulatory ECG (Holter) monitor to assess the severity of the arrhythmia

### Anesthesia considerations:

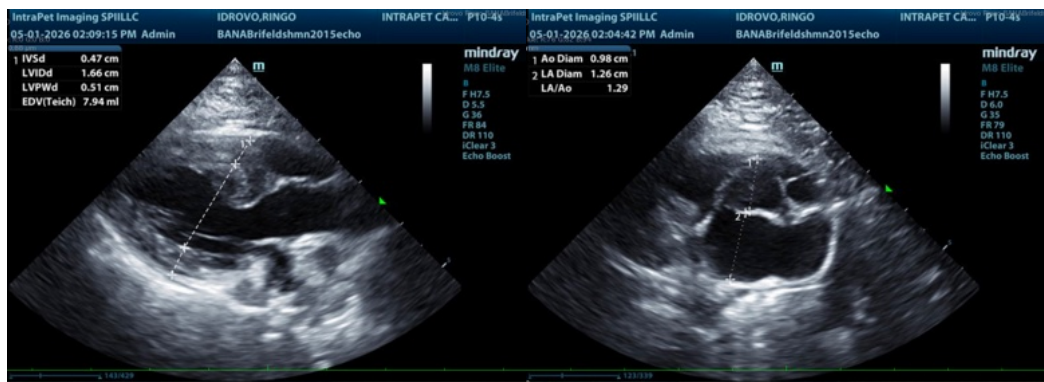
If anesthesia is necessary, then alpha-2 agonists, ketamine, high dose acepromazine, and Telazol should be avoided. Fluid therapy during anesthesia should be considered at a reduced rate (e.g., 5 ml/kg/hour) if possible (i.e., if not hypotensive). A shorter anesthetic duration will reduce the risk of complications. Pre-oxygenation is advised. Premedication with an opioid (i.e., butorphanol, hydromorphone, oxymorphone) with or without a benzodiazepine is generally the safest protocol. An induction agent such as Propofol, alfaxalone can be used to effect. Maintenance of anesthesia with isoflurane or sevoflurane is reasonable.

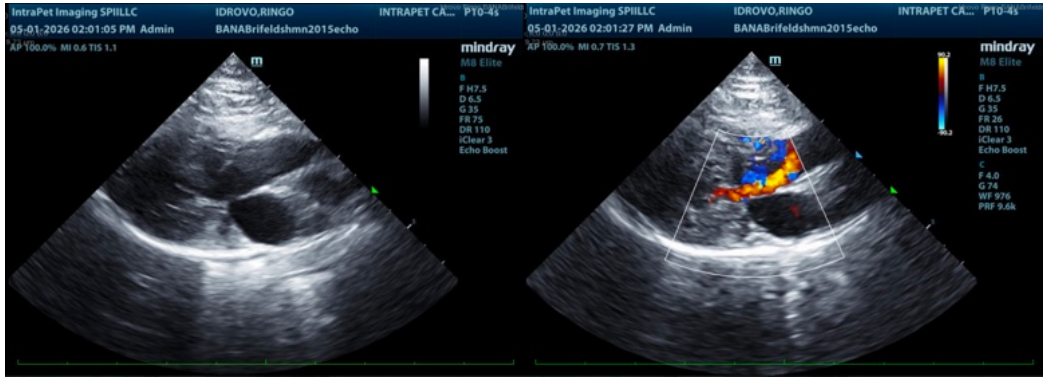
### Diet:

No special considerations are necessary. Any high-quality food from Hills, Royal Canin, Science Diet, Eukanuba, Iams, or Purina is reasonable.

### Activity:

No special considerations are necessary.





The information and recommendations provided are based on the images presented by the referring veterinarian/sonographer. No evaluation can be communicated regarding pathology that was not visible in the image/video clips provided.

Thank you for this referral. If the clinical or image interpretation does not parallel your findings or if I can be of any further assistance please contact me.

Bradley Harris, DVM, DACVECC, DACVIM (cardiology)  
[info@SonoPath.com](mailto:info@SonoPath.com)