



PATIENT

Milo Aguayo

SPECIES

Feline

BREED

DSH

SEX

MN

AGE

11 years

WEIGHT

16.7 lbs

INTERPRETED BY

Bradley Harris, DVM,
DACVECC, DACVIM
(cardiology)

IMAGING PERFORMED BY

Dr. Gabriel Ferrer

HOSPITAL NAME

Pulse Pet Ultrasound
Services

REFERRING VET

Dr. Giselle Bonnet

INVOICE

11655

DATE

4/9/2026

PRESENTING CLINICAL SIGNS

Px presented as a referral for an echocardiogram for an evaluation of a heart murmur and respiratory signs. Px presented with a history of decreased activity at home and episodes of shortness of breath. At physical examination, BCS 8/9, otitis externa which is being treated. On physical examination, cardiac auscultation revealed a grade II-III/VI heart murmur. No abnormal lung sounds were auscultated.

ULTRASONOGRAPHIC EXAMINATION OF THE HEART

FELINE CARDIAC PARAMETERS	BODY WEIGHT (kg)	HR (BPM)	IVSd (cm)	LVIDd (cm)	LVWd (cm)	FS (%)	EF (%)
NORMAL PARAMETER	-----	150-240	0.3-0.6	1.0-2.1	0.25-0.6	35-67	80-100
PATIENT	7.59 kg	NM	0.62	1.60	0.69	70	NM
FELINE CARDIAC PARAMETERS	LA/AO (M-mode)	LA/AO HEART BASE (Sisson)	LAD LA MAX 4 Chamber	LVOT VEL. (m/s)	RVOT VEL. (m/s)	IVRT (m/)	
NORMAL PARAMETER	<1.5	1.6	0.7-1.7	<1.6	<1.3	40-60	
PATIENT	NM	2.41	1.82	0.9	1.0	NM	
Adapted from June Boon, Veterinary Echocardiography, 1998							
Sisson D et al. JVIM 1991; 5: 232, Jacobs et al. Am J Vet Res 1985; 46:1705							

Cardiac Presentation

The left atrium is moderately enlarged. There are no distinct left atrial thrombi/clots or spontaneous echo contrast appreciated. The left ventricle is normal in dimension, with mild to moderate concentric hypertrophy, and no evidence of restriction. Left ventricular systolic function is normal, with adequate contractility based on fractional shortening and systolic left ventricular dimensions. The right atrium and ventricle are subjectively normal in dimension and systolic function. There is evidence of systolic anterior motion of the mitral valve with mild mitral regurgitation. The tricuspid valve leaflets presented normal linear structure, extension in systole, and union in diastole without regurgitation. The left ventricular outflow tract demonstrated turbulent flow and subjective structural valvular integrity. The visible aorta is unremarkable. Pulmonary outflow tract assessment revealed normal valve structure, laminar flow, and appropriate diameter and distensibility. There is no evidence of semilunar valve insufficiency or pulmonary hypertension documented. There is mild to moderate pericardial, suspected mild pleural, and no overt free peritoneal fluid noted.

ULTRASONOGRAPHIC FINDINGS

- These findings identify LV hypertrophy in the setting of an outflow tract obstruction, consistent with hypertrophic obstructive cardiomyopathy (HOCM). The presence of significant left atrial dilation makes CHF a likely explanation for the clinical/radiographic signs (effusion).

INTERPRETATION OF THE FINDINGS & FURTHER RECOMMENDATIONS



PATIENT

Milo Aguayo

SPECIES

Feline

BREED

DSH

SEX

MN

AGE

11 years

WEIGHT

16.7 lbs

INTERPRETED BY

Bradley Harris, DVM,
DACVECC, DACVIM
(cardiology)

IMAGING PERFORMED BY

Dr. Gabriel Ferrer

HOSPITAL NAME

Pulse Pet Ultrasound
Services

REFERRING VET

Dr. Giselle Bonnet

INVOICE

11655

DATE

4/9/2026

Therapy for CHF is indicated, and should include Lasix (2mg/kg q24 to BID) and enalapril (0.5mg/kg q24, assuming normal blood pressure and kidney function). There are significant dilemmas regarding additional therapy, as atenolol is often used in the setting of HOCM, and Vetmedin is indicated in patients with heart failure. Unfortunately, there are contraindications to the atenolol (heart failure) and the pimobendan carries a labeled contraindication in the setting of LV hypertrophy and outflow tract obstruction. Therefore, we will continue with just the furosemide and enalapril unless clinical signs change. A repeat evaluation is recommended in 1-2 weeks, at which time the blood pressure, chemistry, and thoracic radiographs should be repeated. At that time, the addition of Plavix (18.75mg q24) is recommended. Due to the bitter taste of this medication, it may be best to place it in an empty gelatin capsule or use products such as a Pill Pocket. A repeat echocardiogram, blood pressure, chemistry panel, and thoracic radiographs are indicated in another 3-6 months, or sooner if the condition worsens.

Anesthesia considerations:

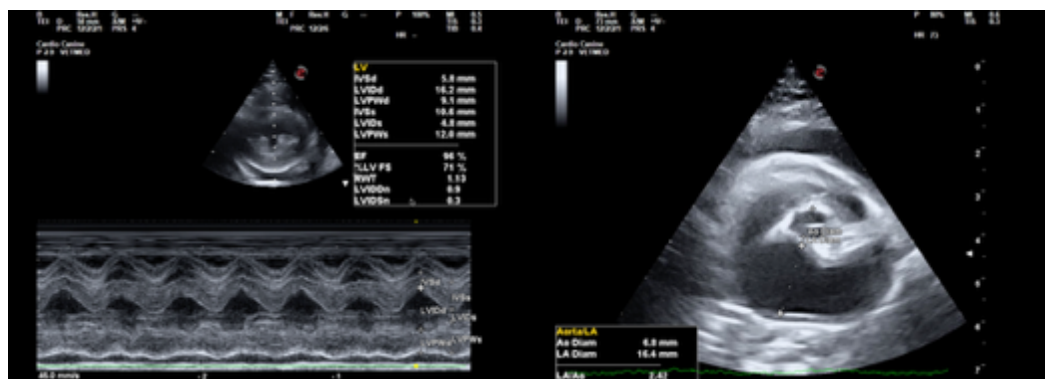Anesthesia should be avoided until signs of congestion have resolved. If anesthesia is necessary, then alpha-2 agonists, ketamine, high dose acepromazine, and Telazol should be avoided. If an ACE inhibitor (enalapril, benazepril) or spironolactone is being given, it should not be administered on the morning of general anesthesia. Other cardiac medications should be administered per the normal dosing schedule. Anesthetic IV fluid use should be limited to < 3 ml/kg/hr and, if IV fluid therapy is administered during the procedure, a 1 mg/kg dose of IM Lasix should be administered when the patient is awake and standing in recovery. A shorter anesthetic duration will reduce the risk of complications. Pre-oxygenation is advised. Premedication with an opioid (i.e., butorphanol, hydromorphone, oxymorphone) with or without a benzodiazepine is generally the safest protocol. An induction agent such as Propofol, alfaxalone, or diazepam/etomidate can be used to effect. Maintenance of anesthesia with isoflurane or sevoflurane is reasonable.

Diet:

A high-quality food from Hills, Royal Canin, Science Diet, Eukanuba, Iams, or Purina that is highly palatable with adequate protein and calories for maintaining optimal body condition with mild dietary sodium restriction (<100 mg/100 kcal) is recommended. Consider omega-3 fatty acid supplementation.

Activity:

Avoid strenuous activity.





PATIENT

Milo Aguayo

SPECIES

Feline

BREED

DSH

SEX

MN

AGE

11 years

WEIGHT

16.7 lbs

INTERPRETED BY

Bradley Harris, DVM,
DACVECC, DACVIM
(cardiology)

IMAGING PERFORMED BY

Dr. Gabriel Ferrer

HOSPITAL NAME

Pulse Pet Ultrasound
Services

REFERRING VET

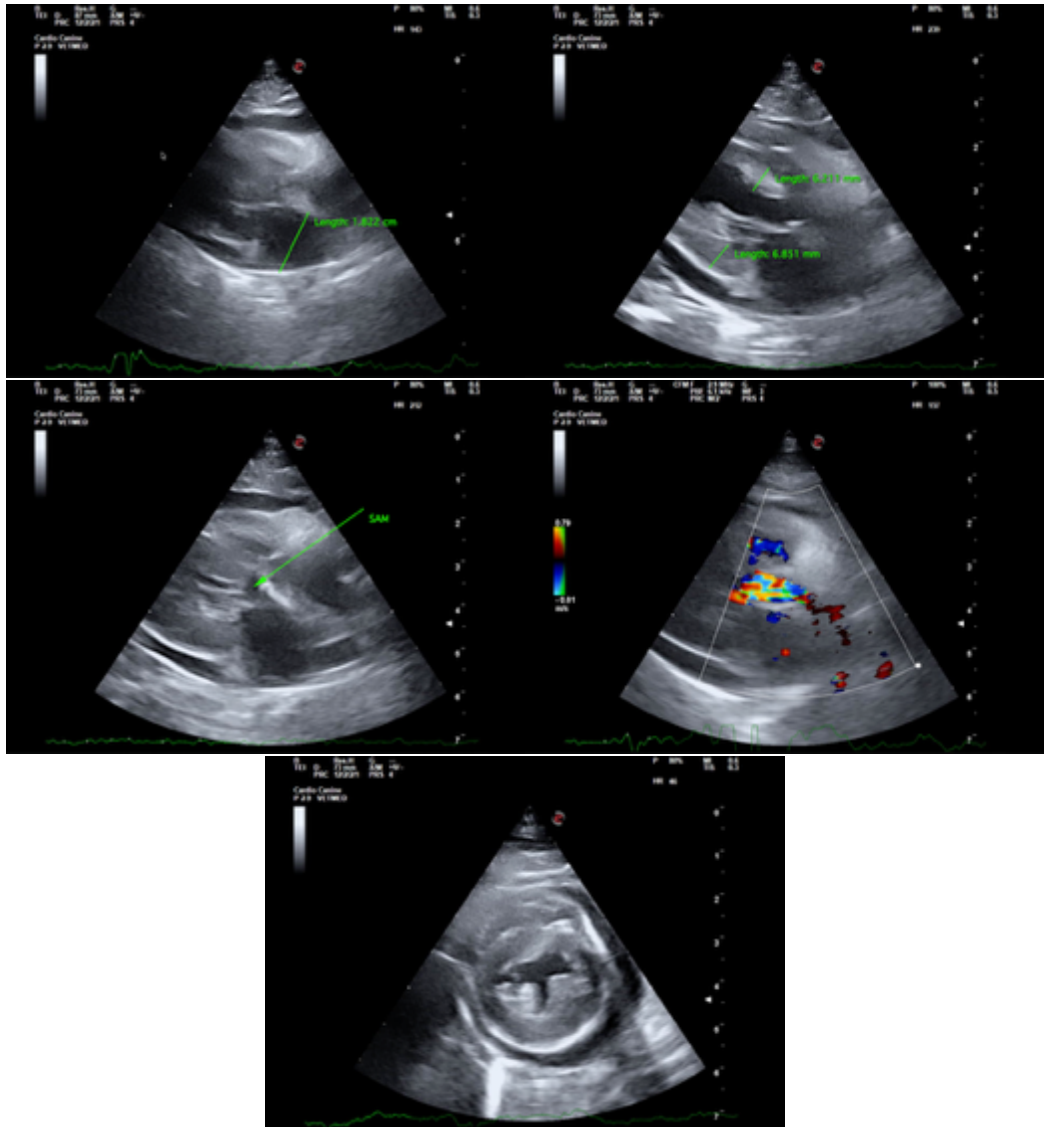
Dr. Giselle Bonnet

INVOICE

11655

DATE

4/9/2026



The information and recommendations provided are based on the images presented by the referring veterinarian/sonographer. No evaluation can be communicated regarding pathology that was not visible in the image/video clips provided.

Thank you for this referral. If the clinical or image interpretation does not parallel your findings or if I can be of any further assistance please contact me.

Bradley Harris, DVM, DACVECC, DACVIM (cardiology)

info@SonoPath.com