



**PATIENT**

Ixchel Banach

**SPECIES**

Canine

**BREED**

Doberman Pinscher

**SEX**

Intact Female

**AGE**

3 years 4 months

**WEIGHT**

64.2 lbs

**INTERPRETED BY**

Bradley Harris, DVM,  
 DACVECC, DACVIM  
 (cardiology)

**IMAGING PERFORMED BY**

Chloe Lowe, CVT

**HOSPITAL NAME**

Shohola VH

**REFERRING VET**

Dr. Demeo

**INVOICE**

11677

**DATE**

4/9/2026

**PRESENTING CLINICAL SIGNS**

Weight loss decreased. Up-to-date on vaccines, including Leto three weeks ago. Drips, dark watery fluid from vulva. Per Owner estrus in February did not occur.

MEDS: Amoxi/clav 500/125.

Abnormal PE/Chem/CBC/UA Results: UA trace protein USG 1.021 BUN, Creat, SDMA elevated Pro BNP gray zone 1,060.

**ULTRASONOGRAPHIC EXAMINATION OF THE HEART**

CANINE CARDIAC PARAMETERS	BW	HR BPM	LAD 4 ch Long	RAD 4 ch Long	La/Ao Heart Base	LVIDd	LVIDs
NORMAL PARAMETER		50-100			<1.6		
PATIENT	29.18 kg	120	3.88	2.43	1.45	4.24	3.14
CANINE CARDIAC PARAMETERS	FS	EPSS	PV V MAX (m/s)	AV V Max (m/sec)	MR Vmax	TR Vmax	RPA distensibility (normal >30%)
NORMAL PARAMETER	28-40	<0.6	0.7-1.6	0.7-1.7	4.5-5.5	< 2.7	
PATIENT	26	0.5	1.5	1.5	NM	NM	NM

**Cardiac Presentation**

The left atrium is normal in dimension. The left ventricle is normal in dimension with normal systolic function. The right atrium and ventricle are normal in dimension with marginal systolic function. The anterior and posterior mitral valve leaflets are appropriately thin with adequate apposition and intact chordae, and there is no significant prolapse. There is no significant mitral regurgitation identified. The tricuspid valve leaflets are appropriately thin with adequate apposition and intact chordae, with trivial tricuspid regurgitation and no evidence of pulmonary hypertension. The left ventricular outflow tract demonstrated normal laminar flow and the visible aorta is unremarkable. The right ventricular outflow tract assessment revealed normal laminar flow, with appropriate main pulmonary artery diameter and right pulmonary artery distensibility. There is no pulmonic and mild aortic valve insufficiency identified. There is no visible pericardial, pleural, or free peritoneal fluid documented. No evidence of hepatic venous congestion is noted. The cardiac chambers, pericardial, and visible extra-cardiac regions were free of masses, spontaneous echo contrast, or thrombi.

**ULTRASONOGRAPHIC FINDINGS**

- These findings are consistent with an essentially normal echocardiogram. Any murmur will be considered functional in origin. No cardiac cause of the morbidity is identified.



**PATIENT**

Ixchel Banach

**SPECIES**

Canine

**BREED**

Doberman Pinscher

**SEX**

Intact Female

**AGE**

3 years 4 months

**WEIGHT**

64.2 lbs

**INTERPRETED BY**

Bradley Harris, DVM,  
DACVECC, DACVIM  
(cardiology)

**IMAGING PERFORMED BY**

Chloe Lowe, CVT

**HOSPITAL NAME**

Shohola VH

**REFERRING VET**

Dr. Demeo

**INVOICE**

11677

**DATE**

4/9/2026

**INTERPRETATION OF THE FINDINGS & FURTHER RECOMMENDATIONS**

Given these findings, no cardiac therapy is recommended. There are no cardiac contraindications to fluid therapy or corticosteroid therapy, as indicated for further assessment and treatment. A recheck echocardiogram is recommended in 6-12 months given the breed and grey zone BNP, or sooner if a murmur or clinical signs of heart disease develop.

Anesthesia considerations:

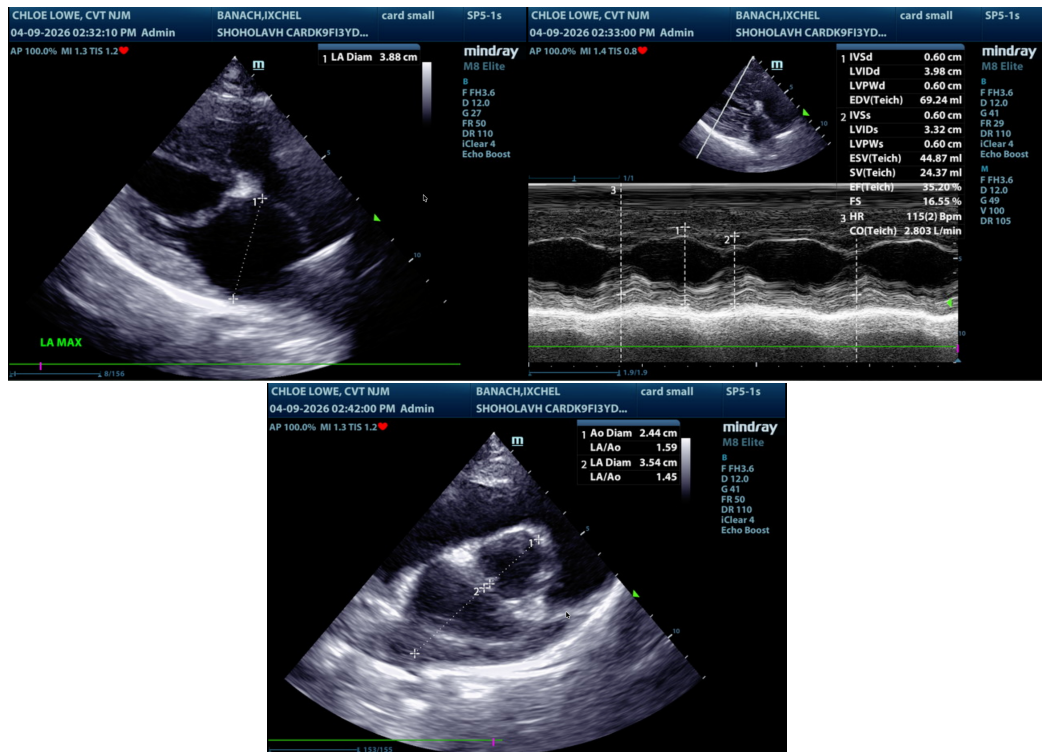
No special considerations are necessary.

Diet:

No special considerations are necessary. Any high-quality food from Hills, Royal Canin, Science Diet, Eukanuba, Iams, or Purina is reasonable.

Activity:

No special considerations are necessary.



The information and recommendations provided are based on the images presented by the referring veterinarian/sonographer. No evaluation can be communicated regarding pathology that was not visible in the image/video clips provided.

Thank you for this referral. If the clinical or image interpretation does not parallel your findings or if I can be of any further assistance please contact me.

**Bradley Harris, DVM, DACVECC, DACVIM (cardiology)**

[info@SonoPath.com](mailto:info@SonoPath.com)