



**PATIENT**

Gizmo Davis

**PRESENTING CLINICAL SIGNS**

Presented after vomiting and collapsed. Hypotensive and tachycardia on arrival.

**SPECIES**

Canine

**BREED**

Pitbull

**SEX**

MN

**AGE**

9 years

**WEIGHT**

31.5 kg

**ULTRASONOGRAPHIC EXAMINATION OF THE HEART**

CANINE CARDIAC PARAMETERS	BW	HR BPM	LAD 4 ch Long	RAD 4 ch Long	La/Ao Heart Base	LVIDd	LVIDs
NORMAL PARAMETER		50-100			<1.6		
PATIENT	31.5 kg	180	3.31	2.13	0.99	2.92	2.21
CANINE CARDIAC PARAMETERS	FS	EPSS	PV V MAX (m/s)	AV V Max (m/sec)	MR Vmax	TR Vmax	RPA distensibility (normal >30%)
NORMAL PARAMETER	28-40	<0.6	0.7-1.6	0.7-1.7	4.5-5.5	< 2.7	
PATIENT	21=4	NM	NM	NM	NM	NM	NM

**INTERPRETED BY**

Bradley Harris, DVM,  
DACVECC, DACVIM  
(cardiology)

**IMAGING PERFORMED BY**

Dr. Sarah Barthelemy

**HOSPITAL NAME**

Petzoic Vet

**REFERRING VET**

Dr. Almeida

**INVOICE**

11654

**DATE**

4/9/2026

**Cardiac Presentation**

The left atrium is normal in dimension. The left ventricle is small/underfilled, with reduced systolic function and pseudohypertrophy. The right atrium and ventricle are subjectively small and display evidence of diastolic collapse/compression. The anterior and posterior mitral and tricuspid valve leaflets presented normal linear structure, extension in systole, and union in diastole without prolapse or myxomatous changes noted. There is no mitral or tricuspid valve regurgitation noted. The left ventricular outflow tract demonstrated normal laminar flow and the visible aorta is unremarkable. The right ventricular outflow tract assessment revealed normal laminar flow, and appropriate diameter and distensibility. There is no evidence of semilunar valve insufficiency. There is moderate to severe pericardial, no pleural, and scant free peritoneal fluid noted. There is a hypochoic mass at the right auricle/atrioventricular junction.

**ULTRASONOGRAPHIC FINDINGS**

- These findings identify pericardial effusion in the setting of a mass lesion in the wall of the right atrium. The location/appearance of the mass is consistent with hemangiosarcoma. The pericardial effusion is most likely neoplastic in origin.

**INTERPRETATION OF THE FINDINGS & FURTHER RECOMMENDATIONS**

There is a therapeutic benefit to tapping the pericardium (if there is enough fluid). Evaluation of the fluid will occasionally be of diagnostic value, but in most cases the results are simply compatible with hemorrhage. If it is hemangiosarcoma, the prognosis is very poor, as recurrent effusions are likely, as is the presence of neoplasia elsewhere in the body. Ideally, an abdominal ultrasound should be considered to identify evidence of neoplasia elsewhere in the body, which (or may not) affect prognosis. If no additional masses can be identified, there may be merit to considering surgical intervention, either by taking the entire pericardium (subtotal pericardiectomy), or creation of a smaller



## PATIENT

Gizmo Davis

## SPECIES

Canine

## BREED

Pitbull

## SEX

MN

## AGE

9 years

## WEIGHT

31.5 kg

## INTERPRETED BY

Bradley Harris, DVM,  
DACVECC, DACVIM  
(cardiology)

## IMAGING PERFORMED BY

Dr. Sarah Barthelemy

## HOSPITAL NAME

Petzoic Vet

## REFERRING VET

Dr. Almeida

## INVOICE

11654

## DATE

4/9/2026

hole via approaches less invasive than a median sternotomy. The value of surgery is simply to avoid the effects of recurrent effusion and need for multiple taps; unfortunately, surgery does not alter the natural course of disease, which usually only affords a prognosis of a few months. Chemotherapy concurrent with surgery can be associated with a prognosis of up to 4-5 months, but this path is considered too aggressive by many owners who will elect to euthanize rather than pursue surgery/chemotherapy.

### Anesthesia considerations:

Anesthesia should be avoided until any signs of CHF and pericardial effusion have resolved. If anesthesia is necessary after that time, then alpha-2 agonists, ketamine, high dose acepromazine, and Telazol should be avoided. Fluid therapy is often necessary in the setting of cardiac tamponade to improve venous return. A shorter anesthetic duration will reduce the risk of complications. Pre-oxygenation is advised. Premedication with an opioid (e.g., butorphanol, hydromorphone, oxymorphone) with or without a benzodiazepine is generally the safest protocol. An induction agent such as Propofol, alfaxalone, or diazepam/etomidate can be used to effect. Maintenance of anesthesia with isoflurane or sevoflurane is reasonable.

### Diet:

No special considerations are necessary. Any high-quality food from Hills, Royal Canin, Science Diet, Eukanuba, Iams, or Purina is reasonable.

### Activity:

Moderate physical activity (meandering walks, exploring the back yard, playing with toys inside, getting excited when family gets home, etc.) is encouraged, but periods of strenuous aerobic activity (jogging, strenuous outdoor ball play, prolonged play at the dog park, etc.) should be avoided, especially during periods of high heat (> 80 F) and humidity. Dogs with heart disease tend to tolerate cool and cold temperatures much better than high temperatures. Avoid sudden increases in activity (e.g. 2 block walks during the week but 2 mile walks followed by 30 minutes at the dog park on the weekends) as this may be difficult for the cardiovascular system to deal with.



### PATIENT

Gizmo Davis

### SPECIES

Canine

### BREED

Pitbull

### SEX

MN

### AGE

9 years

### WEIGHT

31.5 kg

### INTERPRETED BY

Bradley Harris, DVM,  
DACVECC, DACVIM  
(cardiology)

### IMAGING PERFORMED BY

Dr. Sarah Barthelemy

### HOSPITAL NAME

Petzoic Vet

### REFERRING VET

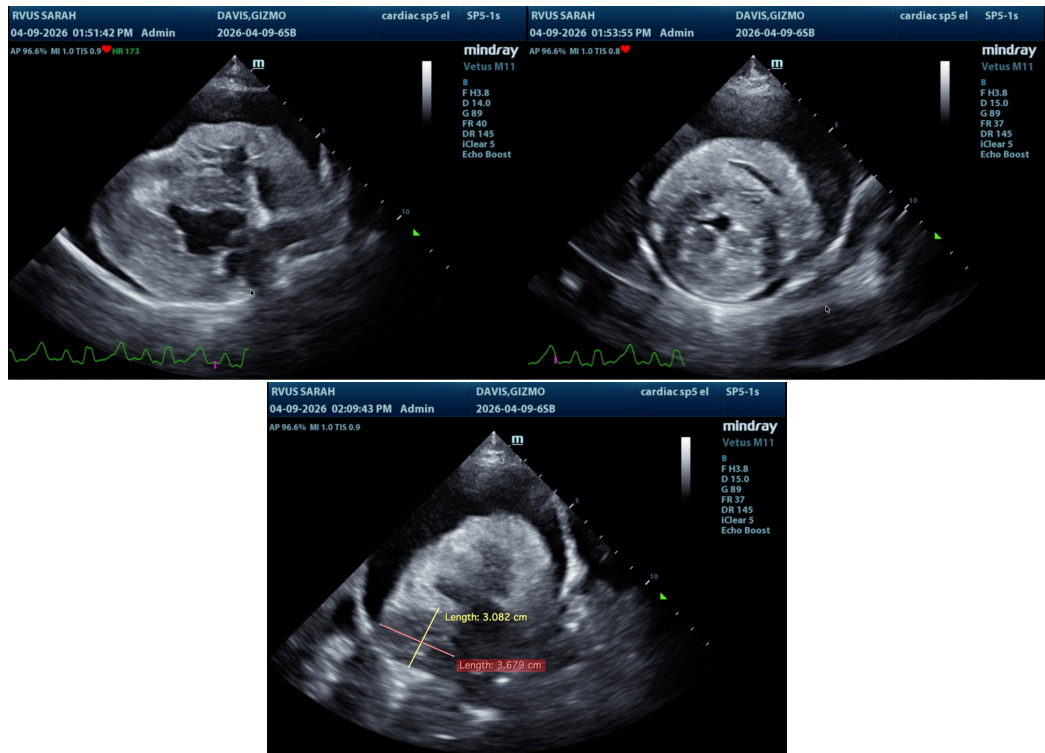
Dr. Almeida

### INVOICE

11654

### DATE

4/9/2026



The information and recommendations provided are based on the images presented by the referring veterinarian/sonographer. No evaluation can be communicated regarding pathology that was not visible in the image/video clips provided.

Thank you for this referral. If the clinical or image interpretation does not parallel your findings or if I can be of any further assistance please contact me.

**Bradley Harris, DVM, DACVECC, DACVIM (cardiology)**

[info@SonoPath.com](mailto:info@SonoPath.com)