



**PATIENT**

Lily Winik

**SPECIES**

Feline

**BREED**

Domestic Shorthair

**SEX**

Spayed female

**AGE**

11 years

**WEIGHT**

9.6 lbs

**INTERPRETED BY**

Bradley Harris, DVM,  
DACVECC, DACVIM  
(cardiology)

**IMAGING PERFORMED BY**

Christopher Roberts

**HOSPITAL NAME**

Kentown AH

**REFERRING VET**

Dr. Roberts

**INVOICE**

75009

**DATE**

4/30/26

**PRESENTING CLINICAL SIGNS**

History: P has long history of allergies. Recently changed clinics. Presented to DVM for annual wellness and refill of immunotherapy and dexamethasone tablets. P receives Heska Allercept Immunotherapy shots every 2 weeks and also receives Dexamethasone 0.75 mg tablets- 1/2 tablet by mouth once a week. Has been on this treatment plan for since 2018. Recent wellness BW revealed significant elevation of BNP. Referred for echo.

Abnormal PE/Chem/CBC/UA Results: BAR, H/L-WNL, no auscultable murmur at time of PE No BP performed CBC- WNL Chem- WNL BNP- 1500 (0-100) T4- 2.2 FIV/FelLV- neg/neg UA- WNL- USG- 1.047

**ULTRASONOGRAPHIC EXAMINATION OF THE HEART**

The left atrium is normal in dimension. There are no distinct left atrial thrombi/clots or spontaneous echo contrast appreciated. The left ventricle is normal in dimension as well as wall thickness, and no evidence of restriction. Left ventricular systolic function is normal, with adequate contractility based on fractional shortening and systolic left ventricular dimensions. The right atrium and ventricle are subjectively normal in dimension and systolic function. The anterior and posterior mitral and tricuspid valve leaflets presented normal linear structure, extension in systole, and union in diastole without regurgitation. There is no evidence of systolic anterior mitral valve motion documented. The left ventricular outflow tract demonstrated normal laminar flow and subjective structural valvular integrity. The visible aorta is unremarkable. Pulmonary outflow tract assessment revealed normal valve structure, laminar flow, and appropriate diameter and distensibility. There is no evidence of pulmonary hypertension documented. There is no visible pericardial, pleural, or free peritoneal fluid noted.

FELINE CARDIAC PARAMETERS	BODY WEIGHT (kg)	HR (BPM)	IVSd (cm)	LVIDd (cm)	LVWd (cm)	FS (%)	EF (%)
NORMAL PARAMETER	-----	150-240	0.3-0.6	1.0-2.1	0.25-0.6	35-67	80-100
PATIENT	4.36 kg	200	0.53	0.97	0.46	37	62
FELINE CARDIAC PARAMETERS	LA/AO (M-mode)	LA/AO HEART BASE (Sisson)	LAD LA MAX 4 Chamber		LVOT VEL. (m/s)	RVOT VEL. (m/s)	IVRT (m/)
NORMAL PARAMETER	<1.5	1.6	0.7-1.7		<1.6	<1.3	40-60
PATIENT	1.34	1.25	1.31		0.8	0.7	NM
Adapted from June Boon, Veterinary Echocardiography, 1998 Sisson D et al. JVIM 1991; 5: 232, Jacobs et al. Am J Vet Res 1985; 46:1705							



## PATIENT

Lily Winik

## SPECIES

Feline

## BREED

Domestic Shorthair

## SEX

Spayed female

## AGE

11 years

## WEIGHT

9.6 lbs

## INTERPRETED BY

Bradley Harris, DVM,  
DACVECC, DACVIM  
(cardiology)

## IMAGING PERFORMED BY

Christopher Roberts

## HOSPITAL NAME

Kentown AH

## REFERRING VET

Dr. Roberts

## INVOICE

75009

## DATE

4/30/26

## ULTRASONOGRAPHIC FINDINGS

These findings are consistent with an essentially normal echocardiogram. The presence of an elevated BNP is often associated with underlying heart disease, but can be seen in animals without heart disease. In addition, changes on chest X-rays can occur without significant underlying disease. The absence of any abnormalities on the echo excludes any meaningful cardiac disease at this time. Any murmur will be considered functional in origin at this time.

## INTERPRETATION OF THE FINDINGS & FURTHER RECOMMENDATIONS

Given these findings, no cardiac therapy is recommended. There are no cardiac contraindications to corticosteroids or fluid therapy as indicated for further treatment. No specific recheck echocardiogram is recommended.

### Anesthesia considerations:

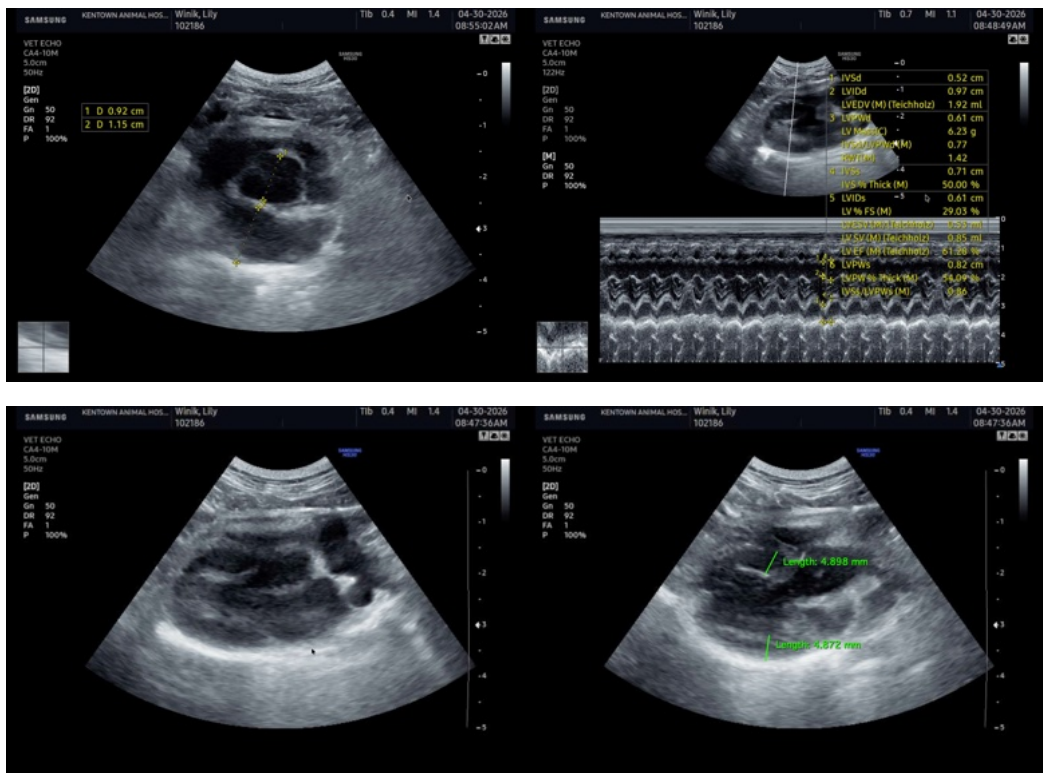
No special cardiac considerations are necessary

### Diet:

No special considerations are necessary. Any high-quality food from Hills, Royal Canin, Science Diet, Eukanuba, Iams, or Purina is reasonable.

### Activity:

No special considerations are necessary.





## PATIENT

Lily Winik

## SPECIES

Feline

## BREED

Domestic Shorthair

## SEX

Spayed female

## AGE

11 years

## WEIGHT

9.6 lbs

## INTERPRETED BY

Bradley Harris, DVM,  
DACVECC, DACVIM  
(cardiology)

## IMAGING PERFORMED BY

Christopher Roberts

## HOSPITAL NAME

Kentown AH

## REFERRING VET

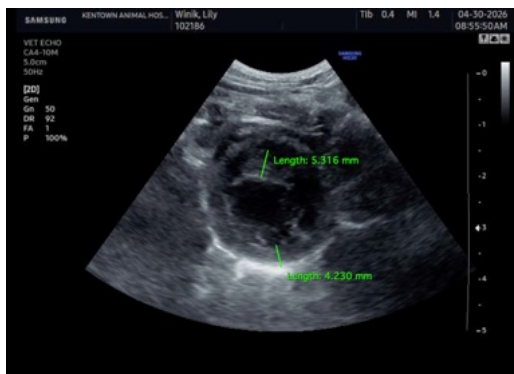
Dr. Roberts

## INVOICE

75009

## DATE

4/30/26



The information and recommendations provided are based on the images presented by the referring veterinarian/sonographer. No evaluation can be communicated regarding pathology that was not visible in the image/video clips provided.

Thank you for this referral. If the clinical or image interpretation does not parallel your findings or if I can be of any further assistance please contact me.

Bradley Harris, DVM, DACVECC, DACVIM (cardiology)

[info@SonoPath.com](mailto:info@SonoPath.com)