



## PATIENT

Hazel Gillingham

## SPECIES

Canine

## BREED

Chihuahua

## SEX

Spayed female

## AGE

12 years

## WEIGHT

8.4 lbs

## INTERPRETED BY

Bradley Harris, DVM,  
DACVECC, DACVIM  
(cardiology)

## IMAGING PERFORMED BY

Trish Turner, CVT

## HOSPITAL NAME

Straley Veterinary  
Associates

## REFERRING VET

Dr. Geyer

## INVOICE

74919

## DATE

4/28/26

## PRESENTING CLINICAL SIGNS

History: New client, did not bring any good vet history. Wanted mouth examined Eating and drinking normal. No vomiting or diarrhea. Will hack a little if she is sprinting around the yard for a prolonged period of time.  
Abnormal PE/Chem/CBC/UA Results: Heart murmur- 5/6 Left sided. mild elevation in inflammatory cells and mild elevation in BUN, could be due to teeth, Dr Geyer rec catching urine to bring in to check. Urine specific gravity 1045. Significant calculus and periodontal disease blood pressure 140/150/160 with doppler. Chest rads= nothing significant noted

## ULTRASONOGRAPHIC EXAMINATION OF THE HEART

The left atrium is normal in dimension. The left ventricle is normal in dimension, with normal systolic function. The right atrium and ventricle are normal in dimension, with normal systolic function. The anterior and posterior mitral valve leaflets are thickened and redundant consistent with myxomatous changes, and there is moderate prolapse. There is mild mitral regurgitation identified. The tricuspid valve leaflets are thickened and redundant, with mild tricuspid regurgitation and no evidence of pulmonary hypertension. The left ventricular outflow tract demonstrated normal laminar flow and the visible aorta is unremarkable. The right ventricular outflow tract assessment revealed normal laminar flow, with appropriate main pulmonary artery diameter and right pulmonary artery distensibility. There is no pulmonic and no aortic valve insufficiency identified. There is no visible pericardial, pleural, or free peritoneal fluid documented. No evidence of hepatic venous congestion is noted. The cardiac chambers, pericardial and visible extra-cardiac regions were free of masses, spontaneous echo contrast, or thrombi.

CANINE CARDIAC PARAMETERS	Body Weight kg	HR BPM	LAD 4 ch Long	RAD 4 ch Long	La/Ao Heart Base	LVIDd	LVIDs
NORMAL PARAMETER		50-100			<1.6		
PATIENT	3.82 kg	NM	2.29	1.34	1.36	2.48	1.11
CANINE CARDIAC PARAMETERS	FS	EPSS	PV V MAX (m/s)	AV V Max (m/sec)	MR Vmax	TR Vmax	RPA distensibility (normal >30%)
NORMAL PARAMETER	28-40	<0.6	0.7-1.6	0.7-1.7	4.5-5.5	< 2.7	
PATIENT	55	NM	0.8	1.1	NM	NM	NM

## ULTRASONOGRAPHIC FINDINGS

These findings are consistent with degenerative/myxomatous mitral valve disease with minimal to mild hemodynamic effects consistent with ACVIM Stage B1 disease. It is unlikely that any current morbidity is of cardiac origin.



**PATIENT**

Hazel Gillingham

**SPECIES**

Canine

**BREED**

Chihuahua

**SEX**

Spayed female

**AGE**

12 years

**WEIGHT**

8.4 lbs

**INTERPRETED BY**

Bradley Harris, DVM,  
DACVECC, DACVIM  
(cardiology)

**IMAGING PERFORMED BY**

Trish Turner, CVT

**HOSPITAL NAME**

Straley Veterinary  
Associates

**REFERRING VET**

Dr. Geyer

**INVOICE**

74919

**DATE**

4/28/26

**INTERPRETATION OF THE FINDINGS & FURTHER RECOMMENDATIONS**

Given these findings, no cardiac therapy is recommended. There are no cardiac contraindications to anesthesia, fluid therapy, vasopressor therapy, or corticosteroids as indicated for further assessment and treatment. If not already performed, baseline thoracic radiographs and blood pressure are recommended. A recheck echocardiogram is recommended in 6 months.

Anesthesia considerations:

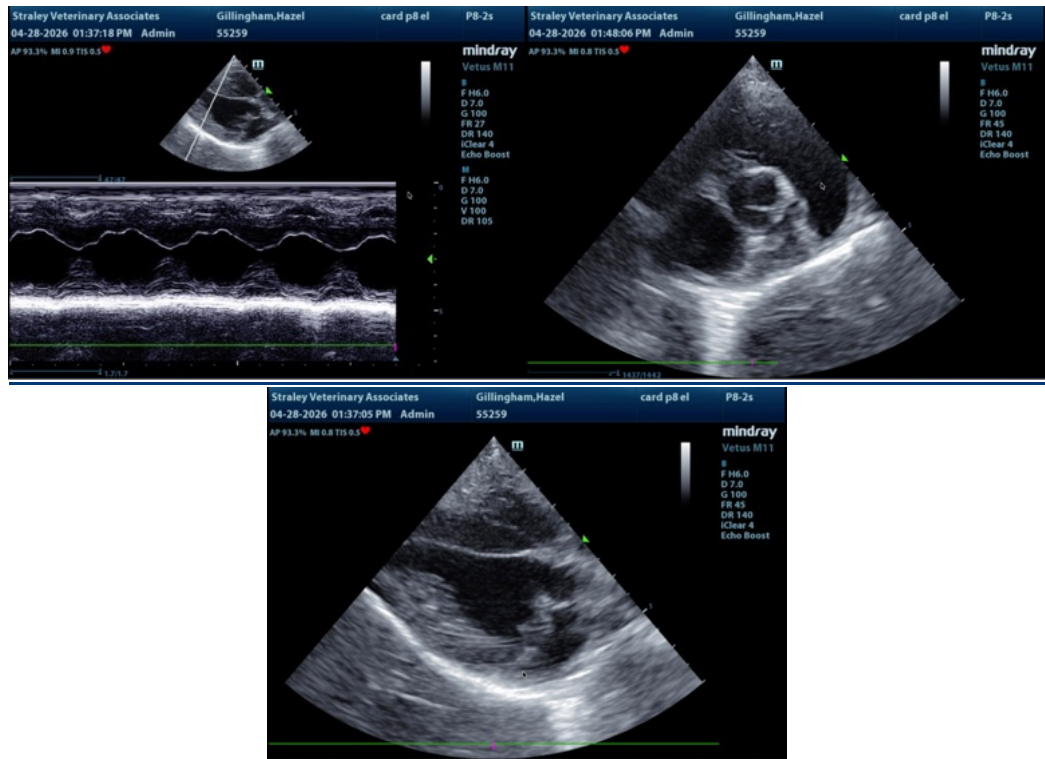
If anesthesia is necessary, alpha-2 agonists, ketamine, high dose acepromazine, and Telazol should be avoided. Fluid therapy during anesthesia should be considered at a conservative rate (e.g., 5 ml/kg/hour) if possible.

Diet:

A high-quality food from Hills, Royal Canin, Science Diet, Eukanuba, Iams, or Purina that is highly palatable with adequate protein and calories for maintaining optimal body condition is reasonable.

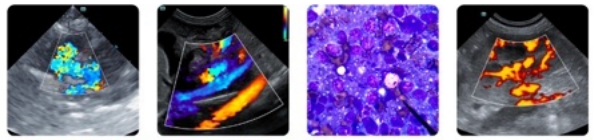
Activity:

No special considerations are necessary.



The information and recommendations provided are based on the images presented by the referring veterinarian/sonographer. No evaluation can be communicated regarding pathology that was not visible in the image/video clips provided.

Thank you for this referral. If the clinical or image interpretation does not parallel your findings or if I can be of any further assistance please contact me.



**PATIENT**

Bradley Harris, DVM, DACVECC, DACVIM (cardiology)

Hazel Gillingham

[info@SonoPath.com](mailto:info@SonoPath.com)

**SPECIES**

Canine

**BREED**

Chihuahua

**SEX**

Spayed female

**AGE**

12 years

**WEIGHT**

8.4 lbs

**INTERPRETED BY**

Bradley Harris, DVM,  
DACVECC, DACVIM  
(cardiology)

**IMAGING  
PERFORMED BY**

Trish Turner, CVT

**HOSPITAL NAME**

Straley Veterinary  
Associates

**REFERRING VET**

Dr. Geyer

**INVOICE**

74919

**DATE**

4/28/26