



**PATIENT**

Roscoe Chan

**SPECIES**

Canine

**BREED**

Lhasa Apso

**SEX**

Neutered Male

**AGE**

11 Years

**WEIGHT**

25 pounds

**INTERPRETED BY**

Bradley Harris, DVM,  
DACVECC, DACVIM  
(cardiology)

**IMAGING PERFORMED BY**

Julia Bakker DVM

**HOSPITAL NAME**

Orange Blossom  
Veterinary Imaging

**REFERRING VET**

Steven Pepper, DVM

**INVOICE**

15192

**DATE**

04/17/26

**PRESENTING CLINICAL SIGNS**

Recent diagnosis of left sided systolic heart murmur grade 2/6

Abnormal PE/Chem/CBC/UA Results: BP today: 145/72 MAP 91 and HR 93

**ULTRASONOGRAPHIC EXAMINATION OF THE HEART**

| CANINE CARDIAC PARAMETERS | BW    | HR BPM | LAD 4 ch Long  | RAD 4 ch Long    | La/Ao Heart Base | LVIDd   | LVIDs                            |
|---------------------------|-------|--------|----------------|------------------|------------------|---------|----------------------------------|
| NORMAL PARAMETER          |       | 50-100 |                |                  | <1.6             |         |                                  |
| PATIENT                   | 11.36 | NM     | 3.67           | 1.88             | 1.49             | 3.25    | 1.4                              |
| CANINE CARDIAC PARAMETERS | FS    | EPSS   | PV V MAX (m/s) | AV V Max (m/sec) | MR Vmax          | TR Vmax | RPA distensibility (normal >30%) |
| NORMAL PARAMETER          | 28-40 | <0.6   | 0.7-1.6        | 0.7-1.7          | 4.5-5.5          | < 2.7   |                                  |
| PATIENT                   | 57    | 0.3    | 0.6            | 1.3              | 6.7              | --      | 32                               |

**Cardiac Presentation**

The left atrium is normal in dimension. The left ventricle is normal in dimension with normal systolic function. The right atrium and ventricle are normal in dimension with normal systolic function. The anterior and posterior mitral valve leaflets are thickened and redundant consistent with myxomatous changes, and there is mild prolapse. There is mild to moderate mitral regurgitation identified. The tricuspid valve leaflets are appropriately thin with adequate apposition and intact chordae, no significant tricuspid regurgitation, and no evidence of pulmonary hypertension. The left ventricular outflow tract demonstrated normal laminar flow and the visible aorta is unremarkable. The right ventricular outflow tract assessment revealed normal laminar flow, with appropriate main pulmonary artery diameter and right pulmonary artery distensibility. There is no pulmonic and no aortic valve insufficiency identified. There is no visible pericardial, pleural, or free peritoneal fluid documented. No evidence of hepatic venous congestion is noted. The cardiac chambers, pericardial, and visible extra-cardiac regions were free of masses, spontaneous echo contrast, or thrombi.

**ULTRASONOGRAPHIC FINDINGS**

- These findings are consistent with degenerative/myxomatous mitral valve disease with minimal to mild hemodynamic effects consistent with ACVIM Stage B1 disease. It is unlikely that any current morbidity is of cardiac origin.

**INTERPRETATION OF THE FINDINGS & FURTHER RECOMMENDATIONS**



**PATIENT**

Roscoe Chan

**SPECIES**

Canine

**BREED**

Lhasa Apso

**SEX**

Neutered Male

**AGE**

11 Years

**WEIGHT**

25 pounds

**INTERPRETED BY**

Bradley Harris, DVM,  
DACVECC, DACVIM  
(cardiology)

**IMAGING PERFORMED BY**

Julia Bakker DVM

**HOSPITAL NAME**

Orange Blossom  
Veterinary Imaging

**REFERRING VET**

Steven Pepper, DVM

**INVOICE**

15192

**DATE**

04/17/26

Given these findings, no cardiac therapy is recommended. There are no cardiac contraindications to anesthesia, fluid therapy, vasopressor therapy, or corticosteroids as indicated for further assessment and treatment. If not already performed, baseline thoracic radiographs and blood pressure are recommended. A recheck echocardiogram is recommended in 6 months.

**Anesthesia considerations:**

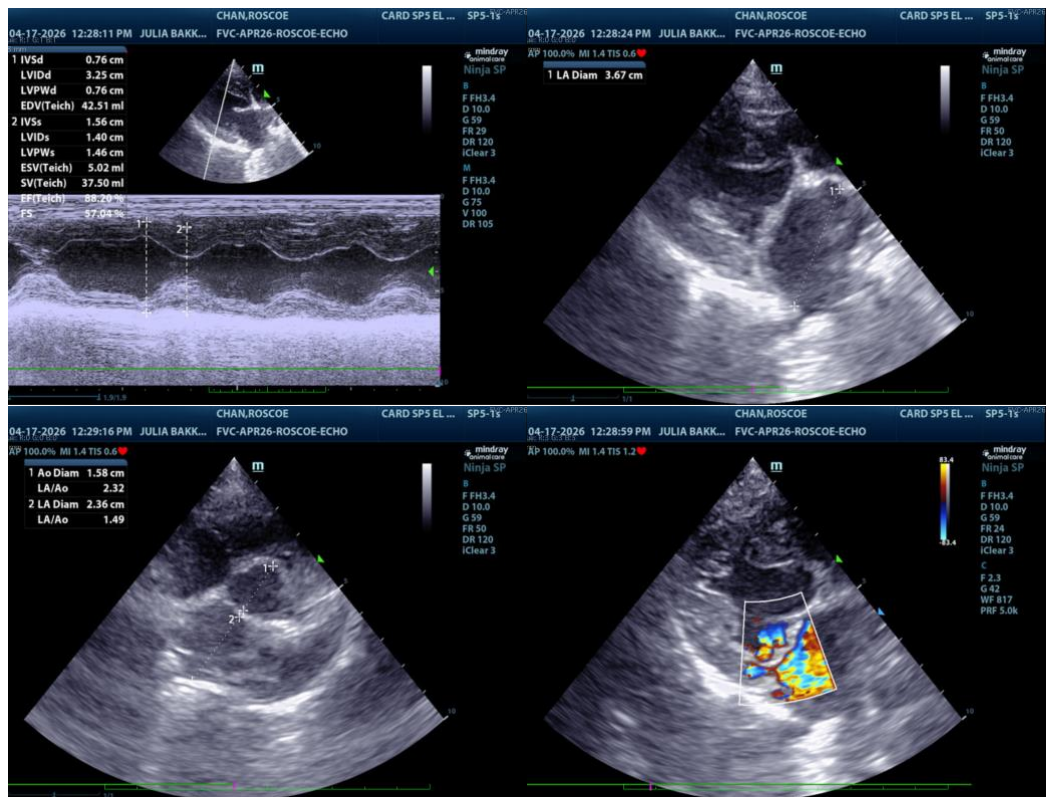
If anesthesia is necessary, alpha-2 agonists, ketamine, high dose acepromazine, and Telazol should be avoided. Fluid therapy during anesthesia should be considered at a conservative rate (e.g., 5 ml/kg/hour) if possible.

**Diet:**

A high-quality food from Hills, Royal Canin, Science Diet, Eukanuba, Iams, or Purina that is highly palatable with adequate protein and calories for maintaining optimal body condition is reasonable.

**Activity:**

No special considerations are necessary.



The information and recommendations provided are based on the images presented by the referring veterinarian/sonographer. No evaluation can be communicated regarding pathology that was not visible in the image/video clips provided.

Thank you for this referral. If the clinical or image interpretation does not parallel your findings or if I can be of any further assistance please contact me.



## PATIENT

Bradley Harris, DVM, DACVECC, DACVIM (cardiology)

Roscoe Chan

[info@SonoPath.com](mailto:info@SonoPath.com)

## SPECIES

Canine

## BREED

Lhasa Apso

## SEX

Neutered Male

## AGE

11 Years

## WEIGHT

25 pounds

## INTERPRETED BY

Bradley Harris, DVM,  
DACVECC, DACVIM  
(cardiology)

## IMAGING PERFORMED BY

Julia Bakker DVM

## HOSPITAL NAME

Orange Blossom  
Veterinary Imaging

## REFERRING VET

Steven Pepper, DVM

## INVOICE

15192

## DATE

04/17/26