

PATIENT

Mochi Cermanski

SPECIES

Feline

BREED

DLH

SEX

Neutered Male

AGE

7 Months

WEIGHT

6.67 pounds

INTERPRETED BY

Bradley Harris, DVM,
 DACVECC, DACVIM
 (Cardiology)

IMAGING PERFORMED BY

Vincent Ravancho CVT

HOSPITAL NAME

Summit Dog and Cat
 Hospital

REFERRING VET

Dr. Nada

INVOICE

15237

DATE

04/17/26

PRESENTING CLINICAL SIGNS

Heart murmur 4/6. Current medications - probiotics for diarrhea, hx of intestinal parasites +v and tx

Abnormal PE/Chem/CBC/UA Results: NA bloodwork, recommended at rescan day. Fecal panel -ve 4/5/2026 FIV/FELV negative

ULTRASONOGRAPHIC EXAMINATION OF THE HEART

FELINE CARDIAC PARAMETERS	BODY WEIGHT (kg)	HR (BPM)	IVSd (cm)	LVIDd (cm)	LVWd (cm)	FS (%)	EF (%)
NORMAL PARAMETER	-----	150-240	0.3-0.6	1.0-2.1	0.25-0.6	35-67	80-100
PATIENT	3.03	290	0.66	1.21	0.57	40	75
FELINE CARDIAC PARAMETERS	LA/AO (M-mode)	LA/AO HEART BASE (Sisson)	LAD LA MAX 4 Chamber		LVOT VEL. (m/s)	RVOT VEL. (m/s)	IVRT (m/)
NORMAL PARAMETER	<1.5	1.6	0.7-1.7		<1.6	<1.3	40-60
PATIENT	NM	1.2	1.17		3.0	2.0	NM
Adapted from June Boon, Veterinary Echocardiography, 1998							
Sisson D et al. JVIM 1991; 5: 232, Jacobs et al. Am J Vet Res 1985; 46:1705							

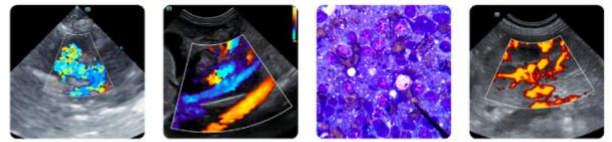
Cardiac Presentation

The left atrium is normal in dimension. There are no distinct left atrial thrombi/clots or spontaneous echo contrast appreciated. The left ventricle is normal in dimension, with mild concentric hypertrophy, and no evidence of restriction. Left ventricular systolic function is normal, with adequate contractility based on fractional shortening and systolic left ventricular dimensions. The right atrium and ventricle are subjectively normal in dimension and systolic function. There is evidence of systolic anterior motion of the mitral valve with moderate mitral regurgitation. The tricuspid valve leaflets presented normal linear structure, extension in systole, and union in diastole without regurgitation. The left ventricular outflow tract demonstrated turbulent flow and subjective structural valvular integrity. The visible aorta is unremarkable. Pulmonary outflow tract assessment revealed normal valve structure, laminar flow, and appropriate diameter and distensibility. There is no evidence of semilunar valve insufficiency or pulmonary hypertension documented. There is no visible pericardial, pleural, or free peritoneal fluid noted.

ULTRASONOGRAPHIC FINDINGS

- These findings identify left ventricular hypertrophy in the setting of an outflow tract obstruction and absence of any chamber dilation, consistent with occult hypertrophic obstructive cardiomyopathy (HOCM).

INTERPRETATION OF THE FINDINGS & FURTHER RECOMMENDATIONS



PATIENT

Mochi Cermanski

SPECIES

Feline

BREED

DLH

SEX

Neutered Male

AGE

7 Months

WEIGHT

6.67 pounds

INTERPRETED BY

Bradley Harris, DVM,
DACVECC, DACVIM
(Cardiology)

**IMAGING
PERFORMED BY**

Vincent Ravancho CVT

HOSPITAL NAME

Summit Dog and Cat
Hospital

REFERRING VET

Dr. Nada

INVOICE

15237

DATE

04/17/26

The presence of hypertrophy and an outflow tract obstruction make the use of a beta blocker worth considering. However, the challenge of treating these cats is the lack of any real data to support a meaningful benefit (most of the rationale for their use is theoretical), coupled with the potential for adverse effects (low BP, renal impairment, potential exacerbation of CHF). If atenolol is used, the atenolol dose would be 1-2mg/kg once daily (with the potential of increasing to BID if well tolerated after the first week). A recheck heart rate, BP, and chemistry would be indicated 1-2 weeks after starting therapy; at that time the need for higher doses of atenolol can be assessed. A repeat echo is warranted in another 6 months, regardless of whether or not therapy is started. Ultimately, a conversation with the owner is necessary to determine what course of therapy is most suitable for them. Regardless, owners should monitor resting respiratory rate at home. Values above 30 breaths/minute or an increase in respiratory rate 10% above baseline should prompt veterinary re-evaluation.

Anesthesia considerations:

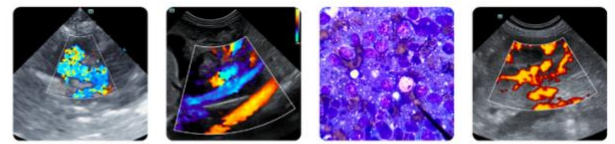
If anesthesia is necessary, then alpha-2 agonists, ketamine, high dose acepromazine, and Telazol should be avoided. If a beta-blocker (atenolol) is being given, it should not be administered on the morning of general anesthesia. Other cardiac medications should be administered per the normal dosing schedule. Fluid therapy during anesthesia should be considered at a conservative rate (e.g., 5 ml/kg/hour) if possible (i.e., if not hypotensive). A shorter anesthetic duration will reduce the risk of complications. Pre-oxygenation is advised. Premedication with an opioid (i.e., butorphanol, hydromorphone, oxymorphone) with or without a benzodiazepine is generally the safest protocol. An induction agent such as Propofol or alfaxalone can be used to effect. Maintenance of anesthesia with isoflurane or sevoflurane is reasonable.

Diet:

No special considerations are necessary. Any high-quality food from Hills, Royal Canin, Science Diet, Eukanuba, Iams, or Purina is reasonable.

Activity:

Avoid overly strenuous activity.



PATIENT

Mochi Cermanski

SPECIES

Feline

BREED

DLH

SEX

Neutered Male

AGE

7 Months

WEIGHT

6.67 pounds

INTERPRETED BY

Bradley Harris, DVM,
 DACVECC, DACVIM
 (Cardiology)

IMAGING PERFORMED BY

Vincent Ravancho CVT

HOSPITAL NAME

Summit Dog and Cat
 Hospital

REFERRING VET

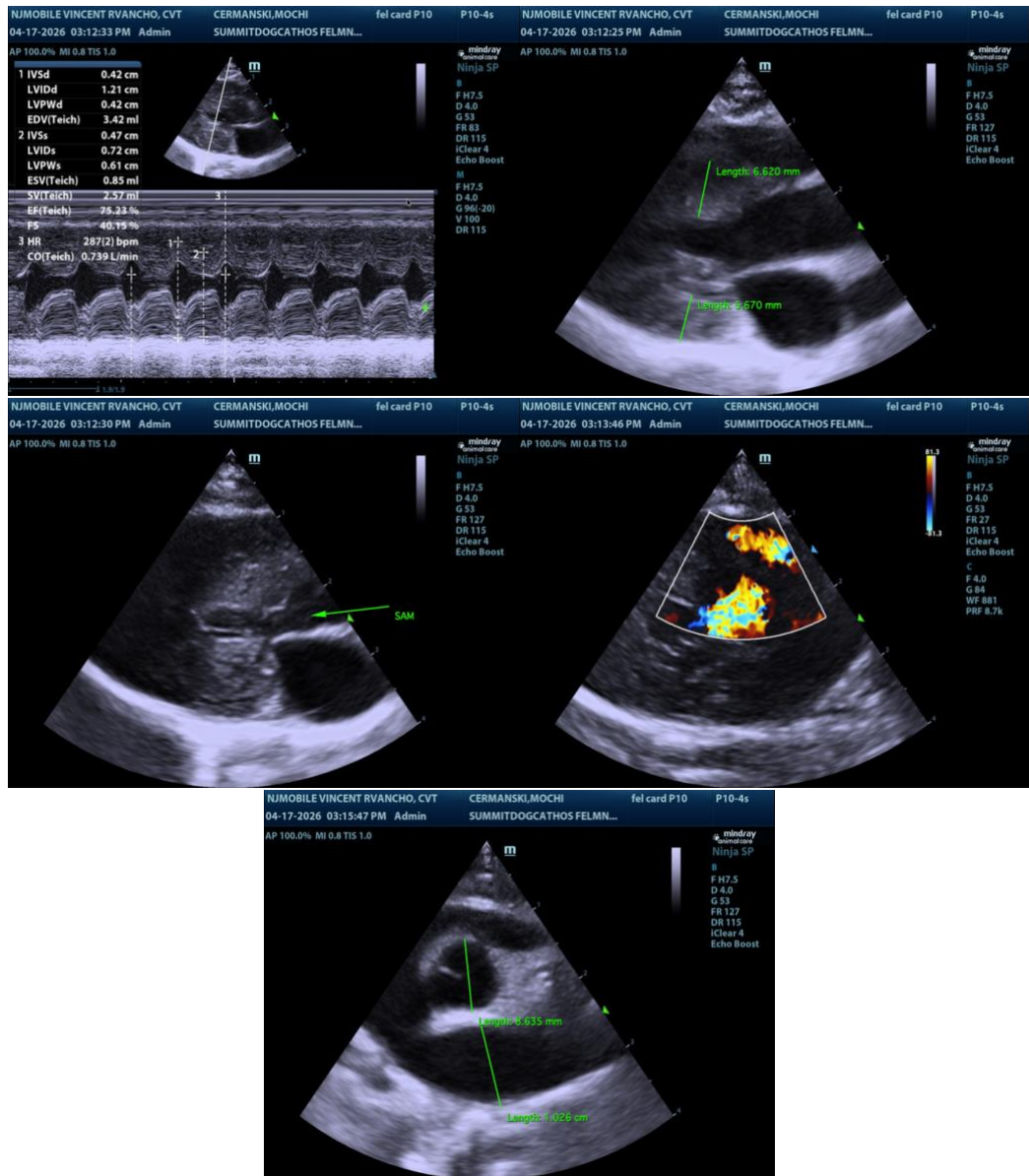
Dr. Nada

INVOICE

15237

DATE

04/17/26

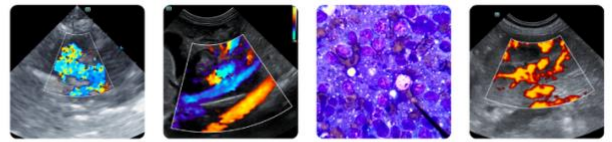


The information and recommendations provided are based on the images presented by the referring veterinarian/sonographer. No evaluation can be communicated regarding pathology that was not visible in the image/video clips provided.

Thank you for this referral. If the clinical or image interpretation does not parallel your findings or if I can be of any further assistance please contact me.

Bradley Harris, DVM, DACVECC, DACVIM (Cardiology)

info@SonoPath.com



PATIENT

Mochi Cermanski

SPECIES

Feline

BREED

DLH

SEX

Neutered Male

AGE

7 Months

WEIGHT

6.67 pounds

INTERPRETED BY

Bradley Harris, DVM,
DACVECC, DACVIM
(Cardiology)

**IMAGING
PERFORMED BY**

Vincent Ravancho CVT

HOSPITAL NAME

Summit Dog and Cat
Hospital

REFERRING VET

Dr. Nada

INVOICE

15237

DATE

04/17/26