

PATIENT

Connie Casella

SPECIES

Canine

BREED

American Pitbull
 Terrier

SEX

Spayed Female

AGE

10 Years 8 Months

WEIGHT

42 pounds

INTERPRETED BY

Bradley Harris, DVM,
 DACVECC, DACVIM
 (cardiology)

IMAGING PERFORMED BY

Rebecca Hamilton

HOSPITAL NAME

Andover Animal
 Hospital

REFERRING VET

Dr. Kotb

INVOICE

15218

DATE

04/17/26

PRESENTING CLINICAL SIGNS

New heart murmur noted: preop clearance for mass removal. Grade 2/6 heart murmur. Focal patches of alopecia w/ hyperpigmentation along dorsum. Dermal growth on dorsal L paw.

Abnormal PE/Chem/CBC/UA Results: Glob 3.8 (H) ALT 165 (H) Phos 2.1 (L) Chol 333 (H) Urine: PH 8, RBC 4-10, USG 1.021

ULTRASONOGRAPHIC EXAMINATION OF THE HEART

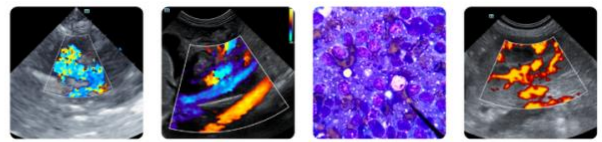
CANINE CARDIAC PARAMETERS	BW	HR BPM	LAD 4 ch Long	RAD 4 ch Long	La/Ao Heart Base	LVIDd	LVIDs
NORMAL PARAMETER		50-100			<1.6		
PATIENT	19.09	170	3.44	2.78	1.03	3.87	2.11
CANINE CARDIAC PARAMETERS	FS	EPSS	PV V MAX (m/s)	AV V Max (m/sec)	MR Vmax	TR Vmax	RPA distensibility (normal >30%)
NORMAL PARAMETER	28-40	<0.6	0.7-1.6	0.7-1.7	4.5-5.5	< 2.7	
PATIENT	45	0.2	1.2	2.5	--	--	33

Cardiac Presentation

The left atrium is normal in dimension. The left ventricle is normal in dimension with normal systolic function. The right atrium and ventricle are normal in dimension with normal systolic function. The anterior and posterior mitral valve leaflets are appropriately thin with adequate apposition and intact chordae, and there is no significant prolapse. There is no significant mitral regurgitation identified. The tricuspid valve leaflets are appropriately thin with adequate apposition and intact chordae, with no significant tricuspid regurgitation and no evidence of pulmonary hypertension. The left ventricular outflow tract demonstrated normal laminar flow and the visible aorta is unremarkable. The right ventricular outflow tract assessment revealed normal laminar flow, with appropriate main pulmonary artery diameter and right pulmonary artery distensibility. There is no pulmonic and no aortic valve insufficiency identified. There is no visible pericardial, pleural, or free peritoneal fluid documented. No evidence of hepatic venous congestion is noted. The cardiac chambers, pericardial, and visible extra-cardiac regions were free of masses, spontaneous echo contrast, or thrombi.

ULTRASONOGRAPHIC FINDINGS

- These findings are consistent with an essentially normal echocardiogram. Any murmur will be considered functional in origin (dynamic left ventricular outflow tract). No cardiac cause of the morbidity is identified.



PATIENT

Connie Casella

SPECIES

Canine

BREED

American Pitbull Terrier

SEX

Spayed Female

AGE

10 Years 8 Months

WEIGHT

42 pounds

INTERPRETED BY

Bradley Harris, DVM, DACVECC, DACVIM (cardiology)

IMAGING PERFORMED BY

Rebecca Hamilton

HOSPITAL NAME

Andover Animal Hospital

REFERRING VET

Dr. Kotb

INVOICE

15218

DATE

04/17/26

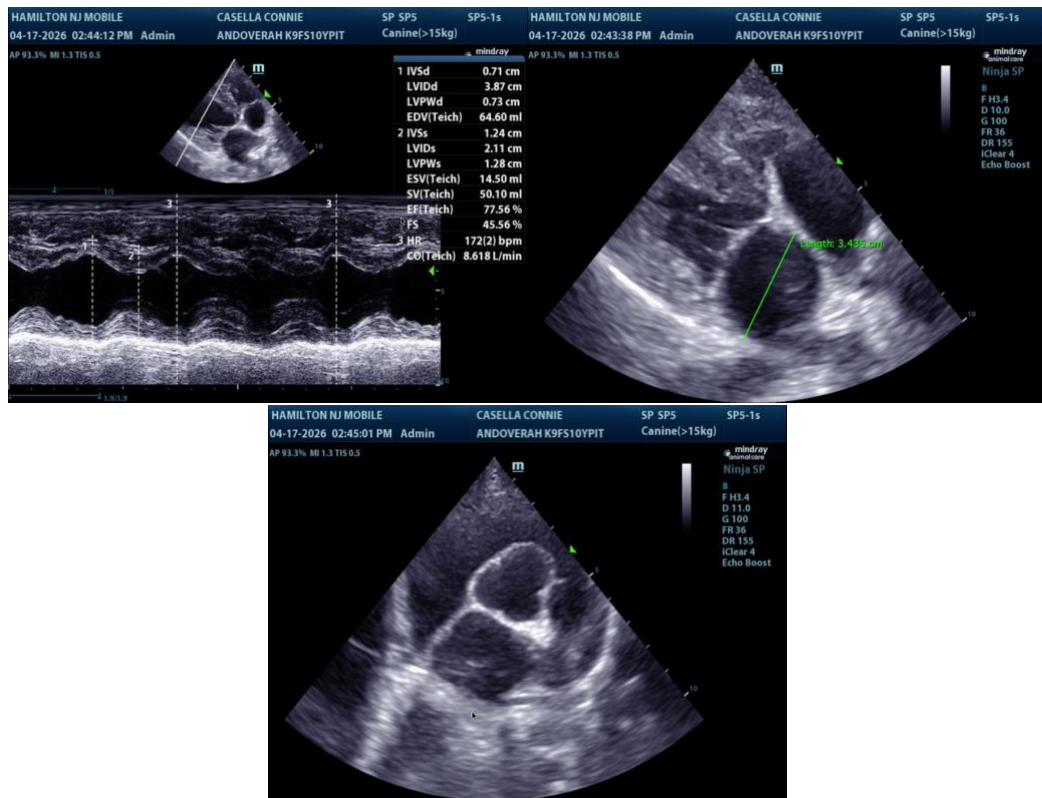
INTERPRETATION OF THE FINDINGS & FURTHER RECOMMENDATIONS

Given these findings, no cardiac therapy is recommended. There are no cardiac contraindications to fluid therapy or corticosteroid therapy, as indicated for further assessment and treatment. No specific cardiac recheck is recommended unless a murmur or clinical signs of heart disease develop.

Anesthesia considerations:
 No special considerations are necessary.

Diet:
 No special considerations are necessary. Any high-quality food from Hills, Royal Canin, Science Diet, Eukanuba, Iams, or Purina is reasonable.

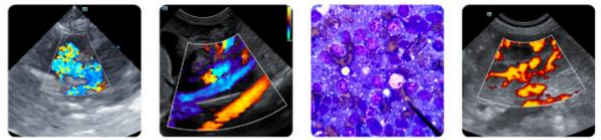
Activity:
 No special considerations are necessary.



The information and recommendations provided are based on the images presented by the referring veterinarian/sonographer. No evaluation can be communicated regarding pathology that was not visible in the image/video clips provided.

Thank you for this referral. If the clinical or image interpretation does not parallel your findings or if I can be of any further assistance please contact me.

Bradley Harris, DVM, DACVECC, DACVIM (cardiology)



PATIENT

info@SonoPath.com

Connie Casella

SPECIES

Canine

BREED

American Pitbull
Terrier

SEX

Spayed Female

AGE

10 Years 8 Months

WEIGHT

42 pounds

INTERPRETED BY

Bradley Harris, DVM,
DACVECC, DACVIM
(cardiology)

**IMAGING
PERFORMED BY**

Rebecca Hamilton

HOSPITAL NAME

Andover Animal
Hospital

REFERRING VET

Dr. Kotb

INVOICE

15218

DATE

04/17/26