

PATIENT

Billy Velazquez

SPECIES

Canine

BREED

Mix

SEX

Neutered Male

AGE

1 Year 4 Months

WEIGHT

28.6 pounds

INTERPRETED BY

Bradley Harris, DVM,
DACVECC, DACVIM
(cardiology)

IMAGING PERFORMED BY

Shari Reffi CVT

HOSPITAL NAME

Harmony Animal
Hospital

REFERRING VET

Dr. Gwon/Keefe

INVOICE

15143

DATE

04/16/26

PRESENTING CLINICAL SIGNS

BCS 7/9; Acute collapse on Saturday. HW (+); liver elevations, radiology consults wnl.

Current Medications; HG; Pred; Doxycycline; Denamarin; Ursodiol

Abnormal PE/Chem/CBC/UA Results: Phos-11.6; BUN-57; Glu-250; ALT too high to read. HW positive.

ULTRASONOGRAPHIC EXAMINATION OF THE HEART

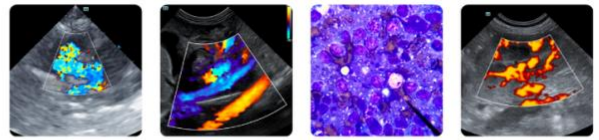
CANINE CARDIAC PARAMETERS	BW	HR BPM	LAD 4 ch Long	RAD 4 ch Long	La/Ao Heart Base	LVIDd	LVIDs
NORMAL PARAMETER		50-100			<1.6		
PATIENT	13.0	NM	3.02	1.85	1.09	2.7	1.9
CANINE CARDIAC PARAMETERS	FS	EPSS	PV V MAX (m/s)	AV V Max (m/sec)	MR Vmax	TR Vmax	RPA distensibility (normal >30%)
NORMAL PARAMETER	28-40	<0.6	0.7-1.6	0.7-1.7	4.5-5.5	< 2.7	
PATIENT	30	0.3	0.7	1.1	NM	NM	43

Cardiac Presentation

The left atrium is normal in dimension. The left ventricle is normal in dimension with normal systolic function. The right atrium and ventricle are normal in dimension with normal systolic function. The anterior and posterior mitral valve leaflets are appropriately thin with adequate apposition and intact chordae, and there is no significant prolapse. There is no significant mitral regurgitation identified. The tricuspid valve leaflets are appropriately thin with adequate apposition and intact chordae, no significant tricuspid regurgitation, and no evidence of pulmonary hypertension. The left ventricular outflow tract demonstrated normal laminar flow and the visible aorta is unremarkable. The right ventricular outflow tract assessment revealed normal laminar flow, with appropriate main pulmonary artery diameter and right pulmonary artery distensibility. There is no pulmonic and no aortic valve insufficiency identified. There is no visible pericardial, pleural, or free peritoneal fluid documented. No evidence of hepatic venous congestion is noted. The cardiac chambers, pericardial, and visible extra-cardiac regions were free of masses, spontaneous echo contrast, or thrombi.

ULTRASONOGRAPHIC FINDINGS

- These findings are consistent with an essentially normal echocardiogram. Any murmur will be considered functional in origin. No cardiac cause of the morbidity is identified.



PATIENT

Billy Velazquez

SPECIES

Canine

BREED

Mix

SEX

Neutered Male

AGE

1 Year 4 Months

WEIGHT

28.6 pounds

INTERPRETED BY

Bradley Harris, DVM,
DACVECC, DACVIM
(cardiology)

IMAGING PERFORMED BY

Shari Reffi CVT

HOSPITAL NAME

Harmony Animal
Hospital

REFERRING VET

Dr. Gwon/Keefe

INVOICE

15143

DATE

04/16/26

INTERPRETATION OF THE FINDINGS & FURTHER RECOMMENDATIONS

Given these findings, no cardiac therapy is recommended. There are no cardiac contraindications to fluid therapy or corticosteroid therapy, as indicated for further assessment and treatment. No specific cardiac recheck is recommended unless a murmur or clinical signs of heart disease develop.

Anesthesia considerations:

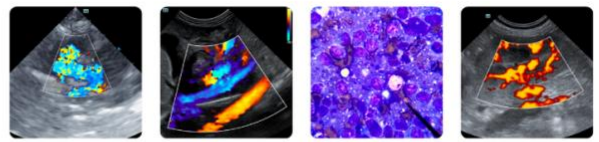
No special considerations are necessary.

Diet:

No special considerations are necessary. Any high-quality food from Hills, Royal Canin, Science Diet, Eukanuba, Iams, or Purina is reasonable.

Activity:

No special considerations are necessary.



PATIENT

Billy Velazquez

SPECIES

Canine

BREED

Mix

SEX

Neutered Male

AGE

1 Year 4 Months

WEIGHT

28.6 pounds

INTERPRETED BY

Bradley Harris, DVM,
 DACVECC, DACVIM
 (cardiology)

IMAGING PERFORMED BY

Shari Reffi CVT

HOSPITAL NAME

Harmony Animal
 Hospital

REFERRING VET

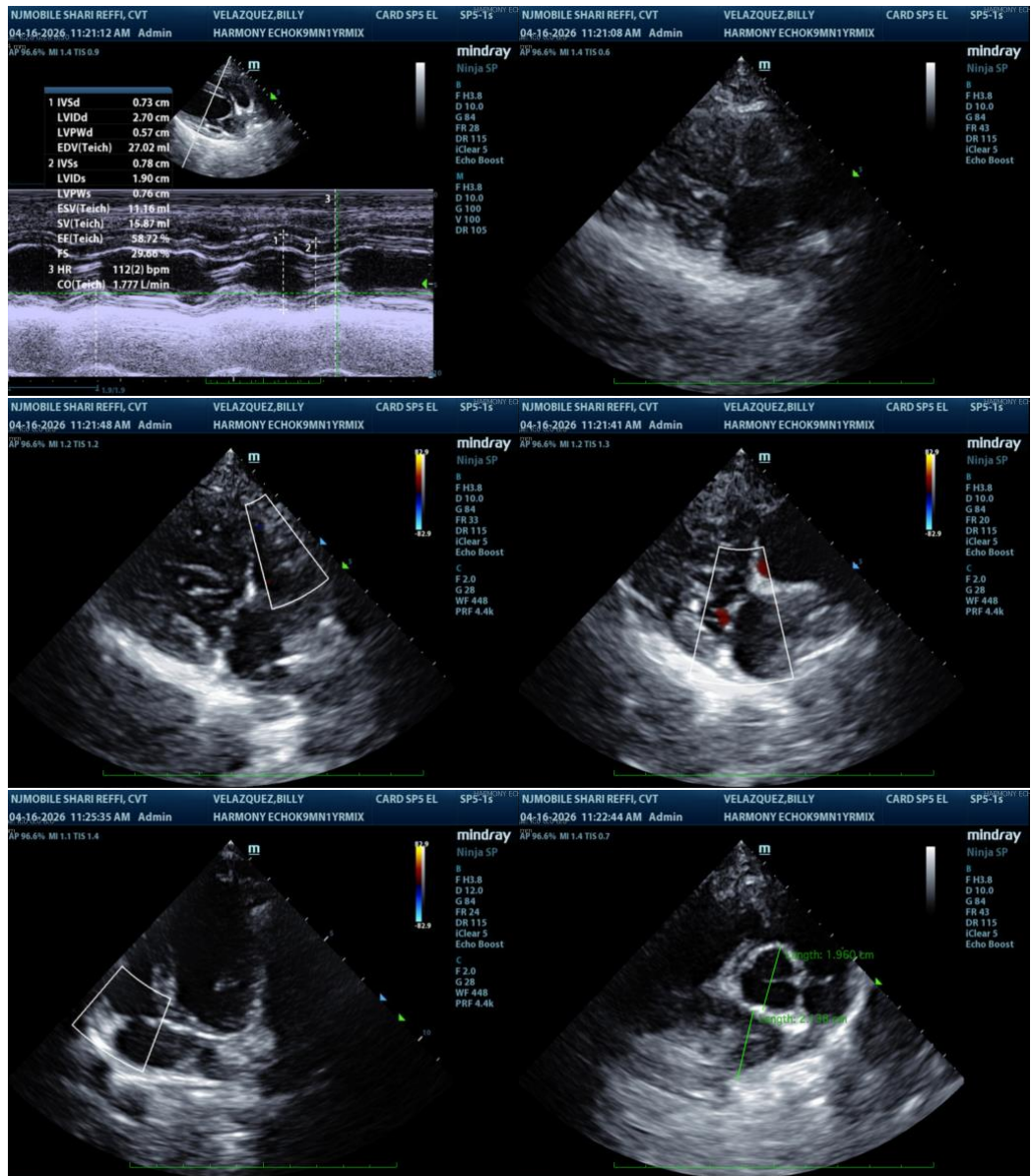
Dr. Gwon/Keefe

INVOICE

15143

DATE

04/16/26



The information and recommendations provided are based on the images presented by the referring veterinarian/sonographer. No evaluation can be communicated regarding pathology that was not visible in the image/video clips provided.

Thank you for this referral. If the clinical or image interpretation does not parallel your findings or if I can be of any further assistance please contact me.

Bradley Harris, DVM, DACVECC, DACVIM (cardiology)

info@SonoPath.com