



PATIENT

Laila Romeiro

SPECIES

Canine

BREED

Boxer

SEX

Spayed female

AGE

9 ½ year

WEIGHT

30 kg

INTERPRETED BY

Bradley Harris, DVM,
DACVECC, DACVIM
(cardiology)

IMAGING PERFORMED BY

Dr. Sorbo

HOSPITAL NAME

JM Pet Resort & VC

REFERRING VET

Dr. Sorbo

INVOICE

74407

DATE

4/13/26

PRESENTING CLINICAL SIGNS

History: Arrhythmia on auscultation during exam.
Mild SDMA elevation and pro-BNP 1701. EKG trace attached.

ULTRASONOGRAPHIC EXAMINATION OF THE HEART

The left atrium is normal in dimension. The left ventricle is normal in dimension with normal systolic function. The right atrium and ventricle are normal in dimension with normal systolic function. The anterior and posterior mitral valve leaflets are appropriately thin with adequate apposition and intact chordae, and there is no significant prolapse. There is no significant mitral regurgitation identified. The tricuspid valve leaflets are appropriately thin with adequate apposition and intact chordae, with no significant tricuspid regurgitation and no evidence of pulmonary hypertension. The left ventricular outflow tract demonstrated normal laminar flow and the visible aorta is unremarkable. The right ventricular outflow tract assessment revealed normal laminar flow, with appropriate main pulmonary artery diameter and right pulmonary artery distensibility. There is no pulmonic and no aortic valve insufficiency identified. There is no visible pericardial, pleural, or free peritoneal fluid documented. No evidence of hepatic venous congestion is noted. The cardiac chambers, pericardial, and visible extra-cardiac regions were free of masses, spontaneous echo contrast, or thrombi.

CANINE CARDIAC PARAMETERS	Body Weight kg	HR BPM	LAD 4 ch Long	RAD 4 ch Long	La/Ao Heart Base	LVIDd	LVIDs
NORMAL PARAMETER		50-100			<1.6		
PATIENT	30 kg	100	4.09	3.37	1.44	3.52	2.31
CANINE CARDIAC PARAMETERS	FS	EPSS	PV V MAX (m/s)	AV V Max (m/sec)	MR Vmax	TR Vmax	RPA distensibility (normal >30%)
NORMAL PARAMETER	28-40	<0.6	0.7-1.6	0.7-1.7	4.5-5.5	< 2.7	
PATIENT	34	0.3	0.9	2.1	Not present	Not present	Not Measured

EKG:

The underlying rhythm is sinus in origin with a varying R-R interval and average heart rate of 100 bpm. The majority of the QRS complexes are supraventricular in origin with consistent P-Q intervals. There are frequent QRS complexes that are prolonged in duration (>70ms), suggesting a ventricular origin, with several couplets. There is no evidence of atrioventricular block or atrial ectopy identified



PATIENT

Laila Romeiro

SPECIES

Canine

BREED

Boxer

SEX

Spayed female

AGE

9 ½ year

WEIGHT

30 kg

INTERPRETED BY

Bradley Harris, DVM,
DACVECC, DACVIM
(cardiology)

IMAGING PERFORMED BY

Dr. Sorbo

HOSPITAL NAME

JM Pet Resort & VC

REFERRING VET

Dr. Sorbo

INVOICE

74407

DATE

4/13/26

ULTRASONOGRAPHIC FINDINGS

These findings identify a ventricular arrhythmia in the setting of a normal echo. Given the breed, the most likely explanation is arrhythmogenic right ventricular cardiomyopathy (ARVC) of Boxers. Boxer ARVC (also called Boxer Cardiomyopathy) is a hereditary disease that affects the heart muscle. ARVC can result in arrhythmias, syncope/fainting, sudden death or the development of congestive heart failure. However, it is possible that the arrhythmia could be related to an unidentified intra-abdominal lesion (e.g., of the spleen and adrenal glands).

INTERPRETATION OF THE FINDINGS & FURTHER RECOMMENDATIONS

At this time, there are several options, to include (1) do nothing now, and simply monitor for progressive changes, especially as the dog is asymptomatic, (2) consider the merits of having a Holter performed to determine if the severity of the arrhythmia warrants therapy, or (3) go ahead and start therapy with sotalol (1-2 mg/kg orally every twelve hours), recognizing the reality that there is no current evidence documenting the ability of antiarrhythmics to reduce the risk of sudden death. If therapy is started (either with or without a Holter), a repeat echo, ECG and BP would be recommended to in 2-4 weeks to monitor for benefit/adverse effects of therapy. Otherwise, a repeat evaluation should be performed in another 3-6 months to determine if the arrhythmia has worsened.

Anesthesia considerations:

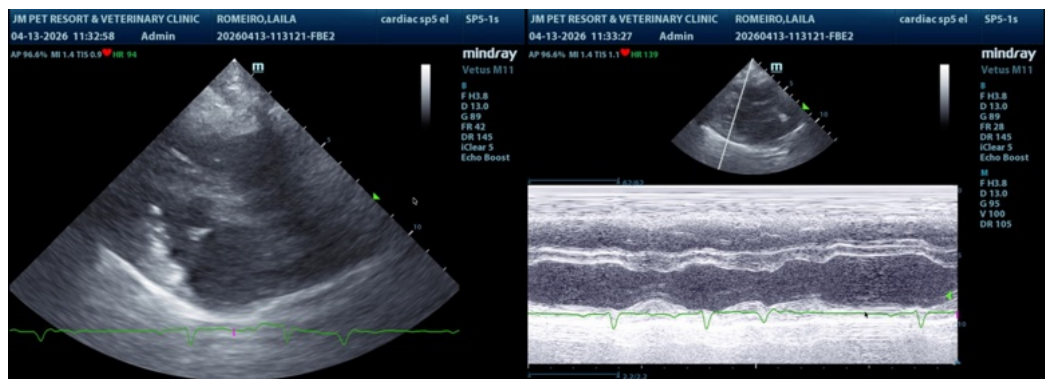
No special considerations are necessary.

Diet:

No special considerations are necessary. Any high-quality food from Hills, Royal Canin, Science Diet, Eukanuba, Iams, or Purina is reasonable.

Activity:

No special considerations are necessary.





PATIENT

Laila Romeiro

SPECIES

Canine

BREED

Boxer

SEX

Spayed female

AGE

9 ½ year

WEIGHT

30 kg

INTERPRETED BY

Bradley Harris, DVM,
DACVECC, DACVIM
(cardiology)

IMAGING PERFORMED BY

Dr. Sorbo

HOSPITAL NAME

JM Pet Resort & VC

REFERRING VET

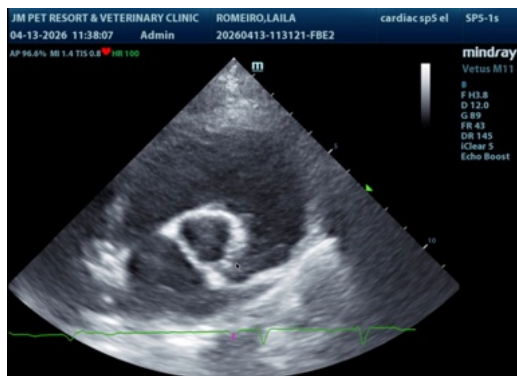
Dr. Sorbo

INVOICE

74407

DATE

4/13/26



The information and recommendations provided are based on the images presented by the referring veterinarian/sonographer. No evaluation can be communicated regarding pathology that was not visible in the image/video clips provided.

Thank you for this referral. If the clinical or image interpretation does not parallel your findings or if I can be of any further assistance please contact me.

Bradley Harris, DVM, DACVECC, DACVIM (cardiology)

info@SonoPath.com