



PATIENT

Shaila Escobar

SPECIES

Feline

BREED

DSH

SEX

FS

AGE

8 years

WEIGHT

11.16 lbs

INTERPRETED BY

Bradley Harris, DVM,
DACVECC, DACVIM
(cardiology)

IMAGING PERFORMED BY

Carla

HOSPITAL NAME

Animal Care Clinic of
Flanders

REFERRING VET

Dr. Villari

INVOICE

11675

DATE

4/10/2026

PRESENTING CLINICAL SIGNS

Walk in emergency exam 4/10/26. Cardiomyopathy, Tachypnea, Labored breathing, Respiratory wheezing. Sent to emergency clinic for overnight care.

Medications: Furosemide injection - 0.5ml IV after scan was completed.

Abnormal PE/Chem/CBC/UA Results: Hypokalemia Hyperglobulinemia.

ULTRASONOGRAPHIC EXAMINATION OF THE HEART

| FELINE CARDIAC PARAMETERS | BODY WEIGHT (kg) | HR (BPM) | IVSd (cm) | LVIDd (cm) | LVWd (cm) | FS (%) | EF (%) |
|--|------------------|---------------------------|----------------------|------------|-----------------|-----------------|-----------|
| NORMAL PARAMETER | ----- | 150-240 | 0.3-0.6 | 1.0-2.1 | 0.25-0.6 | 35-67 | 80-100 |
| PATIENT | 5.07 kg | NM | 0.61 | 1.44 | 0.70 | 40 | NM |
| FELINE CARDIAC PARAMETERS | LA/AO (M-mode) | LA/AO HEART BASE (Sisson) | LAD LA MAX 4 Chamber | | LVOT VEL. (m/s) | RVOT VEL. (m/s) | IVRT (m/) |
| NORMAL PARAMETER | <1.5 | 1.6 | 0.7-1.7 | | <1.6 | <1.3 | 40-60 |
| PATIENT | NM | 1.33 | 1.50 | | 1.0 | 0.8 | NM |
| Adapted from June Boon, Veterinary Echocardiography, 1998 Sisson D et al. JVIM 1991; 5: 232, Jacobs et al. Am J Vet Res 1985; 46:1705 | | | | | | | |

Cardiac Presentation

The left atrium is normal in dimension. There are no distinct left atrial thrombi/clots or spontaneous echo contrast appreciated. The left ventricle is normal in dimension, with mild to moderate concentric hypertrophy, and no evidence of restriction. Left ventricular systolic function is normal, with adequate contractility. The right atrium and ventricle are subjectively normal in dimension and systolic function. The anterior and posterior mitral and tricuspid valve leaflets presented normal linear structure, extension in systole, and union in diastole without regurgitation. There is no evidence of systolic anterior mitral valve motion documented. The left ventricular outflow tract demonstrated normal laminar flow and subjective structural valvular integrity. The visible aorta is unremarkable. Pulmonary outflow tract assessment revealed normal valve structure, laminar flow, and appropriate diameter and distensibility. There is no evidence of semilunar valve insufficiency or pulmonary hypertension documented. There is no visible pericardial, pleural, or free peritoneal fluid noted.

ULTRASONOGRAPHIC FINDINGS

- These findings identify left ventricular hypertrophy in the absence of an outflow tract obstruction, consistent with hypertrophic cardiomyopathy (HCM). The lack of significant atrial dilation makes congestive heart failure unlikely, however recent diuretic administration can artifactually alter results.



PATIENT

Shaila Escobar

SPECIES

Feline

BREED

DSH

SEX

FS

AGE

8 years

WEIGHT

11.16 lbs

INTERPRETED BY

Bradley Harris, DVM,
DACVECC, DACVIM
(cardiology)

IMAGING PERFORMED BY

Carla

HOSPITAL NAME

Animal Care Clinic of
Flanders

REFERRING VET

Dr. Villari

INVOICE

11675

DATE

4/10/2026

INTERPRETATION OF THE FINDINGS & FURTHER RECOMMENDATIONS

A systemic blood pressure and thyroid level are recommended to rule out systemic hypertension and hyperthyroidism as a cause for the left ventricular hypertrophy, respectively. If normal, then the left ventricular hypertrophy is secondary to primary hypertrophic cardiomyopathy.

Given that the hypertrophy is mild and there is no left atrial enlargement, no specific treatment is recommended at this time.

The clinical course for cats with HCM is incredibly variable. Results of future rechecks, especially the echocardiogram, will help us better determine the long-term prognosis. Cats with mild cardiac changes can live for years with static disease. Complications are more likely to occur in cats with advanced heart disease, and include congestive heart failure, sudden death due to arrhythmias, and thromboembolism.

Recently, the FDA authorized conditional approval of the medication Felycin (delayed-released rapamycin) in feline patients with sub-clinical HCM which in early studies has shown to reduce left ventricular wall thickening/hypertrophy. However, extensive information regarding the use/indications, potential side effects, and monitoring is still emerging, and the drug is still not largely available (<https://www.fda.gov/animal-veterinary/cvm-updates/fda-conditionally-approves-drug-management-ventricular-hypertrophy-cats>). In the absence of liver disease and/or diabetes mellitus, introduction of this medication is reasonable (0.3 mg/kg PO once weekly). If this is performed monitoring of patient bloodwork is advised at least on a 3-6 month basis unless clinically warranted sooner.

A recheck echocardiogram, thoracic radiographs, and blood pressure are recommended in 12 months to monitor for progression, or sooner, if new clinical signs are noted. Owners should begin monitoring the resting respiratory rate. A normal respiratory rate is less than 30 breaths per minute; however, the trend in breathing rate is most important. If a progressive increase in respiratory rate is seen, then evaluation by a veterinarian is necessary.

Anesthesia considerations:

If anesthesia is necessary, then alpha-2 agonists, ketamine, high dose acepromazine, and Telazol should be avoided. Fluid therapy during anesthesia should be considered at a conservative rate (e.g., 5 ml/kg/hour) if possible (i.e., if not hypotensive). A shorter anesthetic duration will reduce the risk of complications. Pre-oxygenation is advised. Premedication with an opioid (i.e., butorphanol, hydromorphone, oxymorphone) with or without a benzodiazepine is generally the safest protocol. An induction agent such as Propofol, alfaxalone, or diazepam/etomidate can be used to effect. Maintenance of anesthesia with isoflurane or sevoflurane is reasonable.

Diet:

No special considerations are necessary. Any high-quality food from Hills, Royal Canin, Science Diet, Eukanuba, Iams, or Purina is reasonable.

Activity:

No special considerations are necessary.



PATIENT

Shaila Escobar

SPECIES

Feline

BREED

DSH

SEX

FS

AGE

8 years

WEIGHT

11.16 lbs

INTERPRETED BY

Bradley Harris, DVM,
DACVECC, DACVIM
(cardiology)

IMAGING PERFORMED BY

Carla

HOSPITAL NAME

Animal Care Clinic of
Flanders

REFERRING VET

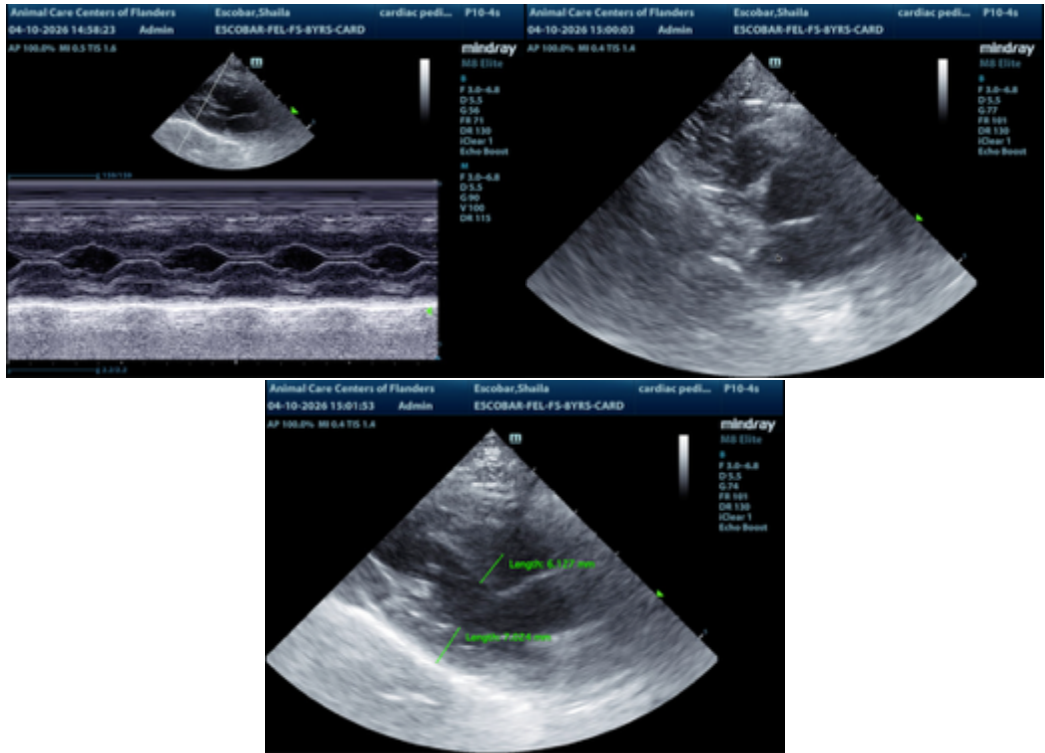
Dr. Villari

INVOICE

11675

DATE

4/10/2026



The information and recommendations provided are based on the images presented by the referring veterinarian/sonographer. No evaluation can be communicated regarding pathology that was not visible in the image/video clips provided.

Thank you for this referral. If the clinical or image interpretation does not parallel your findings or if I can be of any further assistance please contact me.

Bradley Harris, DVM, DACVECC, DACVIM (cardiology)

info@SonoPath.com