



PATIENT

Chloe Bulmer

SPECIES

Canine

BREED

Havanese

SEX

FS

AGE

9 years

WEIGHT

6.1 kg

PRESENTING CLINICAL SIGNS

Newly diagnosed 3/6 heart murmur, patient nonclinical.

ULTRASONOGRAPHIC EXAMINATION OF THE HEART

CANINE CARDIAC PARAMETERS	BW	HR BPM	LAD 4 ch Long	RAD 4 ch Long	La/Ao Heart Base	LVIDd	LVIDs
NORMAL PARAMETER		50-100			<1.6		
PATIENT	6.1 kg	100	2.99	NM	1.20	2.53	1.50
CANINE CARDIAC PARAMETERS	FS	EPSS	PV V MAX (m/s)	AV V Max (m/sec)	MR Vmax	TR Vmax	RPA distensibility (normal >30%)
NORMAL PARAMETER	28-40	<0.6	0.7-1.6	0.7-1.7	4.5-5.5	< 2.7	
PATIENT	41	0.3	0.6	1.5	5.0	2.3	NM

INTERPRETED BY

Bradley Harris, DVM, DACVECC, DACVIM (cardiology)

IMAGING PERFORMED BY

Dr. Gira

HOSPITAL NAME

Douglas Square PH

REFERRING VET

Dr. Singla

INVOICE

11693

DATE

4/10/2026

Cardiac Presentation

The left atrium is upper limits of normal to mildly enlarged. The left ventricle is normal in dimension with normal systolic function. The right atrium and ventricle are normal in dimension with normal systolic function. The anterior and posterior mitral valve leaflets are thickened and redundant consistent with myxomatous changes, and there is mild prolapse. There is moderate to severe mitral regurgitation identified. The tricuspid valve leaflets are thickened and redundant, with mild to moderate tricuspid regurgitation and no evidence of pulmonary hypertension. The left ventricular outflow tract demonstrated normal laminar flow and the visible aorta is unremarkable. The right ventricular outflow tract assessment revealed normal laminar flow, with appropriate main pulmonary artery diameter and right pulmonary artery distensibility. There is no pulmonic and mild aortic valve insufficiency identified. There is no visible pericardial, pleural, or free peritoneal fluid documented. No evidence of hepatic venous congestion is noted. The cardiac chambers, pericardial, and visible extra-cardiac regions were free of masses, spontaneous echo contrast, or thrombi.

ULTRASONOGRAPHIC FINDINGS

- These findings are consistent with degenerative/myxomatous mitral valve disease with minimal to mild hemodynamic effects consistent with ACVIM Stage B1 disease (MINE 2 score 3 - mild). It is unlikely that any current morbidity is of cardiac origin.

INTERPRETATION OF THE FINDINGS & FURTHER RECOMMENDATIONS

Given these findings, no cardiac therapy is recommended. There are no cardiac contraindications to anesthesia, fluid therapy, vasopressor therapy, or corticosteroids as indicated for further assessment and treatment. If not already performed, baseline thoracic radiographs and blood pressure are recommended. A recheck echocardiogram is recommended in 6 months.



PATIENT

Chloe Bulmer

SPECIES

Canine

BREED

Havanese

SEX

FS

AGE

9 years

WEIGHT

6.1 kg

INTERPRETED BY

Bradley Harris, DVM,
DACVECC, DACVIM
(cardiology)

IMAGING PERFORMED BY

Dr. Gira

HOSPITAL NAME

Douglas Square PH

REFERRING VET

Dr. Singla

INVOICE

11693

DATE

4/10/2026

Anesthesia considerations:

If anesthesia is necessary, alpha-2 agonists, ketamine, high dose acepromazine, and Telazol should be avoided. Fluid therapy during anesthesia should be considered at a conservative rate (e.g., 5 ml/kg/hour) if possible.

Diet:

A high-quality food from Hills, Royal Canin, Science Diet, Eukanuba, Iams, or Purina that is highly palatable with adequate protein and calories for maintaining optimal body condition is reasonable.

Activity:

No special considerations are necessary.



PATIENT

Chloe Bulmer

SPECIES

Canine

BREED

Havanese

SEX

FS

AGE

9 years

WEIGHT

6.1 kg

INTERPRETED BY

Bradley Harris, DVM,
DACVECC, DACVIM
(cardiology)

IMAGING PERFORMED BY

Dr. Gira

HOSPITAL NAME

Douglas Square PH

REFERRING VET

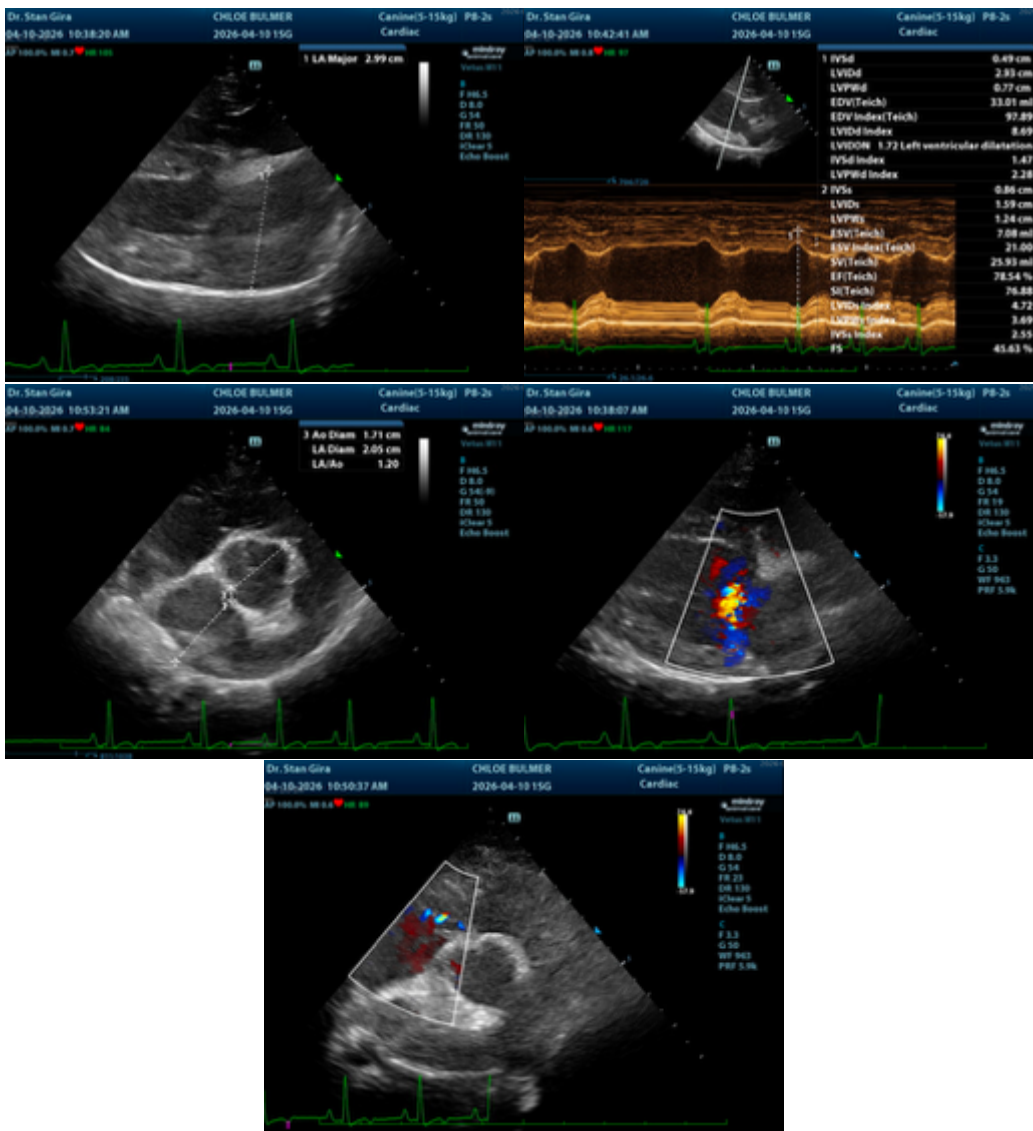
Dr. Singla

INVOICE

11693

DATE

4/10/2026



The information and recommendations provided are based on the images presented by the referring veterinarian/sonographer. No evaluation can be communicated regarding pathology that was not visible in the image/video clips provided.

Thank you for this referral. If the clinical or image interpretation does not parallel your findings or if I can be of any further assistance please contact me.

Bradley Harris, DVM, DACVECC, DACVIM (cardiology)

info@SonoPath.com