



PATIENT

Ziggy Paukovits

SPECIES

Canine

BREED

Mini American Eskimo

SEX

MN

AGE

16 years

WEIGHT

14 lbs

PRESENTING CLINICAL SIGNS

- New Heart murmur.
- BP: 194/47(163), 179/138(152), 225/145(172).
- Current meds: Credelio Quattro.

ULTRASONOGRAPHIC EXAMINATION OF THE HEART

CANINE CARDIAC PARAMETERS	BW	HR BPM	LAD 4 ch Long	RAD 4 ch Long	La/Ao Heart Base	LVIDd	LVIDs
NORMAL PARAMETER		50-100			<1.6		
PATIENT	6.36 kg	NM	2.78	NM	1.21	2.51	1.28
CANINE CARDIAC PARAMETERS	FS	EPSS	PV V MAX (m/s)	AV V Max (m/sec)	MR Vmax	TR Vmax	RPA distensibility (normal >30%)
NORMAL PARAMETER	28-40	<0.6	0.7-1.6	0.7-1.7	4.5-5.5	< 2.7	
PATIENT	49	0.3	0.8	1.0	6.0	NM	NM

INTERPRETED BY

Bradley Harris, DVM,
 DACVECC, DACVIM
 (cardiology)

IMAGING PERFORMED BY

Meghan Morse, LVT,
 CVT

HOSPITAL NAME

Village Vets

REFERRING VET

Dr. Kiselak

INVOICE

11534

DATE

3/19/2026

Cardiac Presentation

The left atrium is normal in dimension. The left ventricle is normal in dimension with normal systolic function. The right atrium and ventricle are normal in dimension with normal systolic function. The anterior and posterior mitral valve leaflets are thickened and redundant consistent with myxomatous changes, and there is moderate prolapse. There is mild mitral regurgitation identified. The tricuspid valve leaflets are appropriately thin with adequate apposition and intact chordae, with no significant tricuspid regurgitation and no evidence of pulmonary hypertension. The left ventricular outflow tract demonstrated normal laminar flow and the visible aorta is unremarkable. The right ventricular outflow tract assessment revealed normal laminar flow and appropriate diameter and distensibility. There is no pulmonic and trivial aortic valve insufficiency identified. There is no visible pericardial, pleural, or free peritoneal fluid documented. No evidence of hepatic venous congestion is noted. The cardiac chambers, pericardial and visible extra-cardiac regions were free of masses, spontaneous echo contrast, or thrombi.

ECG

There is a six-lead ECG with significant baseline artifact available for review. The underlying rhythm is regular at an average rate of 180bpm. The rhythm appears to be sinus in origin with narrow QRS complexes (<70ms). There is no atrial or ventricular ectopy and no conduction delay or block identified. This is most consistent with a normal sinus tachycardia.

ULTRASONOGRAPHIC FINDINGS



PATIENT

Ziggy Paukovits

- These findings are consistent with degenerative/myxomatous mitral valve disease with minimal to mild hemodynamic effects consistent with ACVIM Stage B1 disease. It is unlikely that any current morbidity is of cardiac origin.

SPECIES

Canine

INTERPRETATION OF THE FINDINGS & FURTHER RECOMMENDATIONS

Given these findings, no cardiac therapy is recommended. There are no cardiac contraindications to anesthesia, fluid therapy, vasopressor therapy, or corticosteroids as indicated for further assessment and treatment. A recheck echocardiogram is recommended in 6 months.

BREED

Mini American Eskimo

Anesthesia considerations:

If anesthesia is necessary, alpha-2 agonists, ketamine, high dose acepromazine, and Telazol should be avoided. Fluid therapy during anesthesia should be considered at a conservative rate (e.g., 5 ml/kg/hour) if possible.

SEX

MN

Diet:

A high-quality food from Hills, Royal Canin, Science Diet, Eukanuba, Iams, or Purina that is highly palatable with adequate protein and calories for maintaining optimal body condition is reasonable.

AGE

16 years

WEIGHT

14 lbs

Activity:

No special considerations are necessary.

INTERPRETED BY

Bradley Harris, DVM,
 DACVECC, DACVIM
 (cardiology)

IMAGING PERFORMED BY

Meghan Morse, LVT,
 CVT

HOSPITAL NAME

Village Vets

REFERRING VET

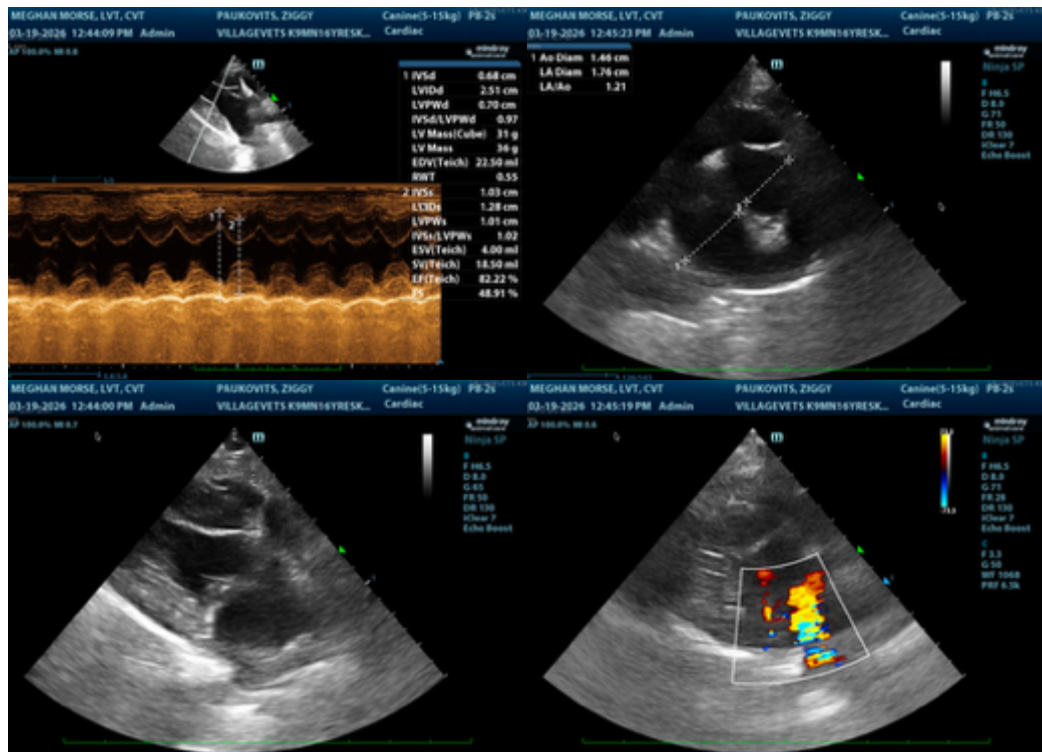
Dr. Kiselak

INVOICE

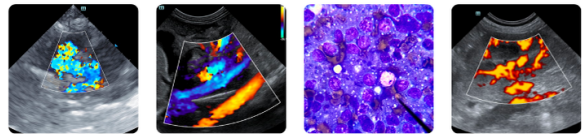
11534

DATE

3/19/2026



The information and recommendations provided are based on the images presented by the referring veterinarian/sonographer. No evaluation can be communicated regarding pathology that was not visible in the image/video clips provided.



PATIENT

Ziggy Paukovits

Thank you for this referral. If the clinical or image interpretation does not parallel your findings or if I can be of any further assistance please contact me.

SPECIES

Canine

Bradley Harris, DVM, DACVECC, DACVIM (cardiology)
info@SonoPath.com

BREED

Mini American Eskimo

SEX

MN

AGE

16 years

WEIGHT

14 lbs

INTERPRETED BY

Bradley Harris, DVM,
DACVECC, DACVIM
(cardiology)

**IMAGING
PERFORMED BY**

Meghan Morse, LVT,
CVT

HOSPITAL NAME

Village Vets

REFERRING VET

Dr. Kiselak

INVOICE

11534

DATE

3/19/2026