



PATIENT

Zelda Lepera

SPECIES

Canine

BREED

Pitbull Mix

SEX

Spayed female

AGE

12 years

WEIGHT

35.2 kg

INTERPRETED BY

Bradley Harris, DVM,
DACVECC, DACVIM
(cardiology)

IMAGING PERFORMED BY

Renee Trionfetti, VMD

HOSPITAL NAME

Blue Pearl Wyomissing

REFERRING VET

Dr. Trionfetti

INVOICE

73563

DATE

3/18/26

PRESENTING CLINICAL SIGNS

- Echo to further evaluate a chronic grade 2/6 HM and now coughing (~month). Trial of antibiotics did not relieve cough (Doxycycline/ Enrofloxacin). Initially presented to rDVM in Feb 2026 for vomiting while trying to eat and coughing. Coughing has persisted. CXR- concern for right heart enlargement.
- BP: 167/76, 167/75 mmHg CXR/AXR (DACVR): Cardiac silhouette is mildly enlarged and rounded, increased sternal contact. RA and RV enlargement suspected. Pulm vasculature normal. Mild right heart enlargement - DDX- tricuspid insuff vs pulm HTN vs anatomic variation - 4Dx: Neg x 4 - Chem: Glob 3.7 H, Alb 3.3-n, normal LES, normal BUN/Cr/SDMA, remainder NSF - CBC: Hct 43%, Plts 209-n, Neut 12,320 mild H, remainder NSF - UA; USG 1.028, pH 8.5 H, Struvite 21-50/hpf, pro 1+ - T4: 1.5-n

ULTRASONOGRAPHIC EXAMINATION OF THE HEART

The left atrium is normal in dimension. The left ventricle is normal in dimension with normal systolic function. The right atrium and ventricle are normal in dimension with normal systolic function. The anterior and posterior mitral valve leaflets are thickened and redundant consistent with myxomatous changes, and there is no significant prolapse. There is mild mitral regurgitation identified. The tricuspid valve leaflets are minimally thickened with trivial tricuspid regurgitation and no evidence of pulmonary hypertension. The left ventricular outflow tract demonstrated normal laminar flow and the visible aorta is unremarkable. The right ventricular outflow tract assessment revealed normal laminar flow and appropriate diameter and distensibility. There is no pulmonic and no aortic valve insufficiency identified. There is no visible pericardial, pleural, or free peritoneal fluid documented. No evidence of hepatic venous congestion is noted. The cardiac chambers, pericardial and visible extra-cardiac regions were free of masses, spontaneous echo contrast, or thrombi.

CANINE CARDIAC PARAMETERS	Body Weight kg	HR BPM	LAD 4 ch Long	RAD 4 ch Long	La/Ao Heart Base	LVIDd	LVIDs
NORMAL PARAMETER		50-100			<1.6		
PATIENT	35.2 kg	90	4.07	3.53	1.19	3.59	1.54
CANINE CARDIAC PARAMETERS	FS	EPSS	PV V MAX (m/s)	AV V Max (m/sec)	MR Vmax	TR Vmax	RPA distensibility (normal >30%)
NORMAL PARAMETER	28-40	<0.6	0.7-1.6	0.7-1.7	4.5-5.5	< 2.7	
PATIENT	57	0.4	0.9	2.0	4.9	1.9	30

ULTRASONOGRAPHIC FINDINGS

These findings are consistent with degenerative/myxomatous mitral valve disease with minimal to mild hemodynamic effects consistent with ACVIM Stage B1 disease. It is unlikely that any current morbidity is of cardiac origin.



PATIENT

Zelda Lepera

SPECIES

Canine

BREED

Pitbull Mix

SEX

Spayed female

AGE

12 years

WEIGHT

35.2 kg

INTERPRETED BY

Bradley Harris, DVM,
DACVECC, DACVIM
(cardiology)

IMAGING PERFORMED BY

Renee Trionfetti, VMD

HOSPITAL NAME

Blue Pearl Wyomissing

REFERRING VET

Dr. Trionfetti

INVOICE

73563

DATE

3/18/26

INTERPRETATION OF THE FINDINGS & FURTHER RECOMMENDATIONS

Given these findings, no cardiac therapy is recommended. There are no cardiac contraindications to anesthesia, fluid therapy, vasopressor therapy, or corticosteroids as indicated for further assessment and treatment. If not already performed, baseline thoracic radiographs and blood pressure are recommended. A recheck echocardiogram is recommended in 6 months.

Anesthesia considerations:

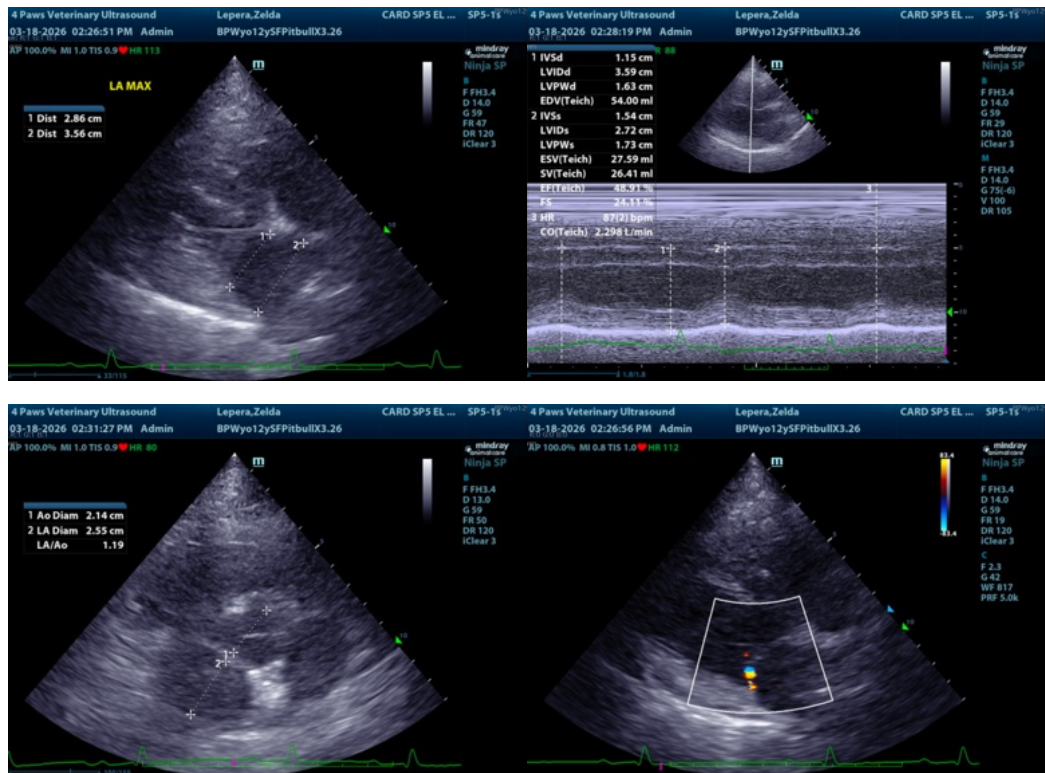
If anesthesia is necessary, alpha-2 agonists, ketamine, high dose acepromazine, and Telazol should be avoided. Fluid therapy during anesthesia should be considered at a conservative rate (e.g., 5 ml/kg/hour) if possible.

Diet:

A high-quality food from Hills, Royal Canin, Science Diet, Eukanuba, Iams, or Purina that is highly palatable with adequate protein and calories for maintaining optimal body condition is reasonable.

Activity:

No special considerations are necessary.





PATIENT

Zelda Lepera

SPECIES

Canine

BREED

Pitbull Mix

SEX

Spayed female

AGE

12 years

WEIGHT

35.2 kg

INTERPRETED BY

Bradley Harris, DVM,
DACVECC, DACVIM
(cardiology)

IMAGING PERFORMED BY

Renee Trionfetti, VMD

HOSPITAL NAME

Blue Pearl Wyomissing

REFERRING VET

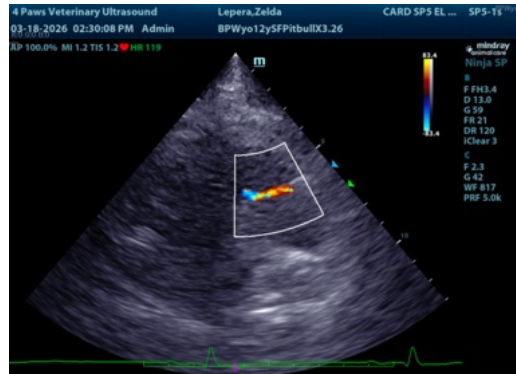
Dr. Trionfetti

INVOICE

73563

DATE

3/18/26



The information and recommendations provided are based on the images presented by the referring veterinarian/sonographer. No evaluation can be communicated regarding pathology that was not visible in the image/video clips provided.

Thank you for this referral. If the clinical or image interpretation does not parallel your findings or if I can be of any further assistance please contact me.

Bradley Harris, DVM, DACVECC, DACVIM (cardiology)

info@SonoPath.com