

## PATIENT

Asher Filatava

## SPECIES

Feline

## BREED

Domestic Shorthair

## SEX

Neutered male

## AGE

7 years

## WEIGHT

16.9 lbs

## INTERPRETED BY

Bradley Harris, DVM,  
DACVECC, DACVIM  
(cardiology)

## IMAGING PERFORMED BY

Melinda Persson

## HOSPITAL NAME

At Home Veterinary

## REFERRING VET

Dr. Persson

## INVOICE

73590

## DATE

3/18/26

## PRESENTING CLINICAL SIGNS

- Check heart to rule out thromboembolic cause of recent onset seizure disorder. No murmur
- Echocardiogram in May 2024 at ER visit for tachypnea and increased respiratory effort: Mild LV remodeling with equivocal LV free wall thickening and mildly increased LV dimensions; normal LA size.
- Asthma treated and controlled with inhaler. Normotensive. Euthyroid

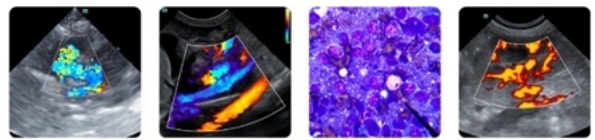
## ULTRASONOGRAPHIC EXAMINATION OF THE HEART

The left atrium is normal in dimension. There are no distinct left atrial thrombi/clots or spontaneous echo contrast appreciated. The left ventricle is normal in dimension as well as wall thickness, and no evidence of restriction. Left ventricular systolic function is normal, with adequate contractility. The right atrium and ventricle are subjectively normal in dimension and systolic function. The anterior and posterior mitral and tricuspid valve leaflets presented normal linear structure, extension in systole, and union in diastole with equivocal mitral regurgitation. There is no evidence of systolic anterior mitral valve motion documented. The left ventricular outflow tract demonstrated normal laminar flow and subjective structural valvular integrity. The visible aorta is unremarkable. Pulmonary outflow tract assessment revealed normal valve structure, laminar flow, and appropriate diameter and distensibility. There is no evidence of pulmonary hypertension documented. There is no visible pericardial, pleural, or free peritoneal fluid noted.

FELINE CARDIAC PARAMETERS	BODY WEIGHT (kg)	HR (BPM)	IVSd (cm)	LVIDd (cm)	LVWd (cm)	FS (%)	EF (%)
NORMAL PARAMETER	-----	150-240	0.3-0.6	1.0-2.1	0.25-0.6	35-67	80-100
PATIENT	7.68 kg	NM	0.39	1.59	0.47	52	86
FELINE CARDIAC PARAMETERS	LA/AO (M-mode)	LA/AO HEART BASE (Sisson)	LAD LA MAX 4 Chamber		LVOT VEL. (m/s)	RVOT VEL. (m/s)	IVRT (m/)
NORMAL PARAMETER	<1.5	1.6	0.7-1.7		<1.6	<1.3	40-60
PATIENT	NM	1.22	1.42		0.9	0.8	NM
Adapted from June Boon, Veterinary Echocardiography, 1998 Sisson D et al. JVIM 1991; 5: 232, Jacobs et al. Am J Vet Res 1985; 46:1705							

## ULTRASONOGRAPHIC FINDINGS

These findings are consistent with an essentially normal echocardiogram. Any murmur auscultated will be considered functional in origin.



**PATIENT**

Asher Filatava

**SPECIES**

Feline

**BREED**

Domestic Shorthair

**SEX**

Neutered male

**AGE**

7 years

**WEIGHT**

16.9 lbs

**INTERPRETED BY**

Bradley Harris, DVM,  
DACVECC, DACVIM  
(cardiology)

**IMAGING PERFORMED BY**

Melinda Persson

**HOSPITAL NAME**

At Home Veterinary

**REFERRING VET**

Dr. Persson

**INVOICE**

73590

**DATE**

3/18/26

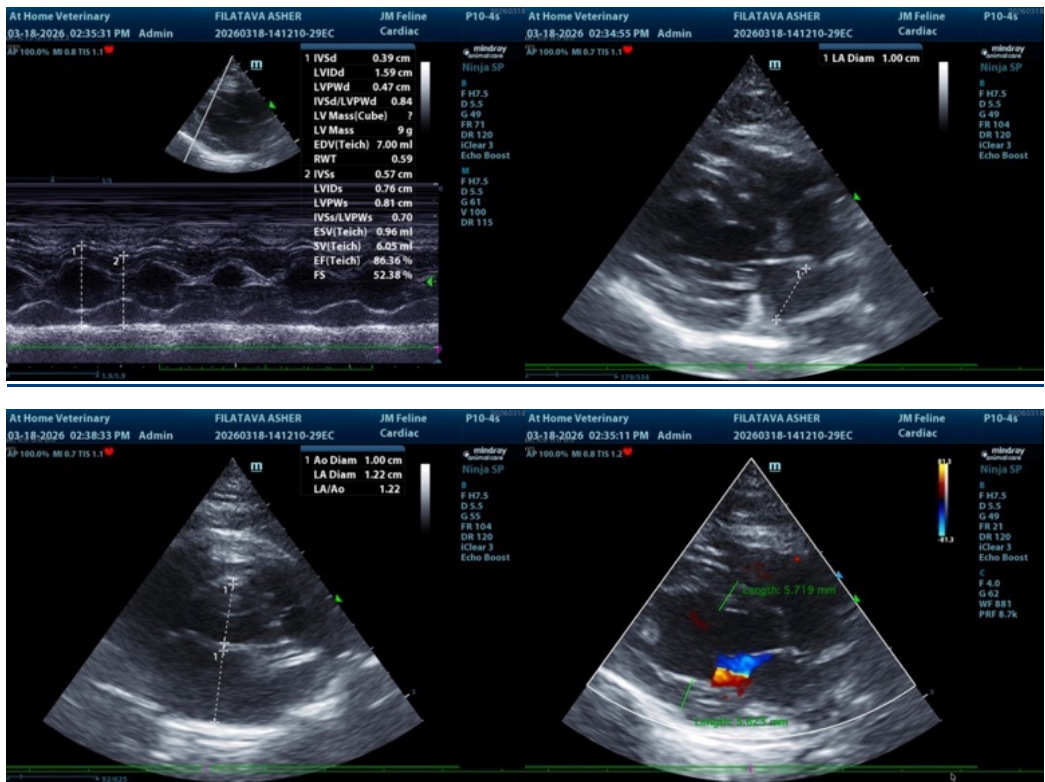
**INTERPRETATION OF THE FINDINGS & FURTHER RECOMMENDATIONS**

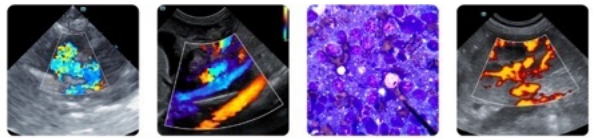
Given these findings, no cardiac therapy is recommended. There are no cardiac contraindications to corticosteroids or fluid therapy as indicated for further treatment. No specific recheck echocardiogram is recommended.

Anesthesia considerations:  
No special cardiac considerations are necessary

Diet:  
No special considerations are necessary. Any high-quality food from Hills, Royal Canin, Science Diet, Eukanuba, Iams, or Purina is reasonable.

Activity:  
No special considerations are necessary.





## PATIENT

Asher Filatava

## SPECIES

Feline

## BREED

Domestic Shorthair

## SEX

Neutered male

## AGE

7 years

## WEIGHT

16.9 lbs

## INTERPRETED BY

Bradley Harris, DVM,  
DACVECC, DACVIM  
(cardiology)

## IMAGING PERFORMED BY

Melinda Persson

## HOSPITAL NAME

At Home Veterinary

## REFERRING VET

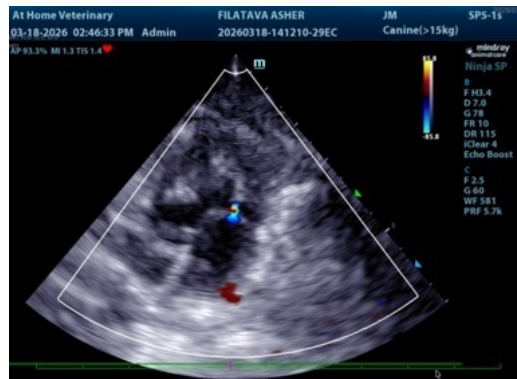
Dr. Persson

## INVOICE

73590

## DATE

3/18/26



The information and recommendations provided are based on the images presented by the referring veterinarian/sonographer. No evaluation can be communicated regarding pathology that was not visible in the image/video clips provided.

Thank you for this referral. If the clinical or image interpretation does not parallel your findings or if I can be of any further assistance please contact me.

Bradley Harris, DVM, DACVECC, DACVIM (cardiology)

[info@SonoPath.com](mailto:info@SonoPath.com)