

**PATIENT**

Cooper Chrusch

**SPECIES**

Canine

**BREED**

French Bulldog

**SEX**

Intact Male

**AGE**

8 Years

**WEIGHT**

~18.0 pounds

**INTERPRETED BY**

Bradley Harris, DVM,  
 DACVECC, DACVIM  
 (cardiology)

**IMAGING PERFORMED BY**

Andrea Nicastro DVM,  
 DACVIM

**HOSPITAL NAME**

Dunes Veterinary  
 Clinic

**REFERRING VET**

Dr. Devin Soileau

**INVOICE**

14320

**DATE**

03/13/26

**PRESENTING CLINICAL SIGNS**

- Recently ADR; episode of collapse
- Hx of seizures (on Keppra)
- Hx of back pain/IVDD

Abnormal PE/Chem/CBC/UA Results: Albumin - 2.4 Creatinine - 1.8 UPC - 0.1 ACTH stim - not consistent with Addison's dz

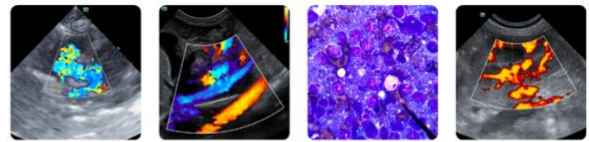
**ULTRASONOGRAPHIC EXAMINATION OF THE HEART**

CANINE CARDIAC PARAMETERS	BW	HR BPM	LAD 4 ch Long	RAD 4 ch Long	La/Ao Heart Base	LVIDd	LVIDs
NORMAL PARAMETER		50-100			<1.6		
PATIENT	8.18	80	2.93	2.21	1.07	2.9	1.89
CANINE CARDIAC PARAMETERS	FS	EPSS	PV V MAX (m/s)	AV V Max (m/sec)	MR Vmax	TR Vmax	RPA distensibility (normal >30%)
NORMAL PARAMETER	28-40	<0.6	0.7-1.6	0.7-1.7	4.5-5.5	< 2.7	
PATIENT	35	1.0	1.0	1.0	NM	NM	31

**Cardiac Presentation**

The left atrium is normal in dimension. The left ventricle is normal in dimension, with normal systolic function. The right atrium and ventricle are normal in dimension, with normal systolic function. The anterior and posterior mitral valve leaflets are appropriately thin with adequate apposition, intact chordae, and there is no significant prolapse. There is no significant mitral regurgitation identified. The tricuspid valve leaflets are appropriately thin with adequate apposition, intact chordae, with trivial tricuspid regurgitation and no evidence of pulmonary hypertension. The left ventricular outflow tract demonstrated normal laminar flow and the visible aorta is unremarkable. The right ventricular outflow tract assessment revealed normal laminar flow, and appropriate diameter and distensibility. There is no pulmonic and no aortic valve insufficiency identified. There is no visible pericardial, pleural, or free peritoneal fluid documented. No evidence of hepatic venous congestion is noted. The cardiac chambers, pericardial and visible extra-cardiac regions were free of masses, spontaneous echo contrast, or thrombi.

**EKG**



**PATIENT**

Cooper Chrusch

**SPECIES**

Canine

**BREED**

French Bulldog

**SEX**

Intact Male

**AGE**

8 Years

**WEIGHT**

~18.0 pounds

**INTERPRETED BY**

Bradley Harris, DVM,  
 DACVECC, DACVIM  
 (cardiology)

**IMAGING PERFORMED BY**

Andrea Nicastro DVM,  
 DACVIM

**HOSPITAL NAME**

Dunes Veterinary  
 Clinic

**REFERRING VET**

Dr. Devin Soileau

**INVOICE**

14320

**DATE**

03/13/26

A six-lead ECG is available for review. The average heart rate is approximately 80bpm, with a normal mean electrical axis. The QRS complexes are sinus in origin (<70ms), with appropriate P-Q intervals. There are irregular R-R intervals, consistent with respiratory variation. There is no evidence of atrial or ventricular ectopy, nor any atrioventricular block. The underlying rhythm is most consistent with a respiratory sinus arrhythmia (normal physiologic change).

**ULTRASONOGRAPHIC FINDINGS**

- These findings are consistent with an essentially normal echocardiogram. Any murmur will be considered functional in origin. No cardiac cause of the morbidity is identified.

**INTERPRETATION OF THE FINDINGS & FURTHER RECOMMENDATIONS**

Given these findings, no cardiac therapy is recommended. There are no cardiac contraindications to fluid therapy or corticosteroid therapy, as indicated for further assessment and treatment. No specific cardiac recheck is recommended unless a murmur or clinical signs of heart disease develop.

Anesthesia considerations:

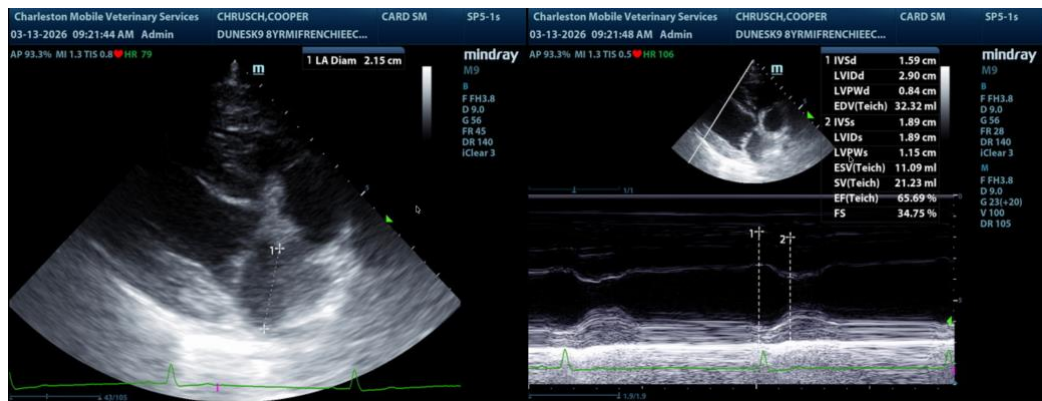
No special considerations are necessary.

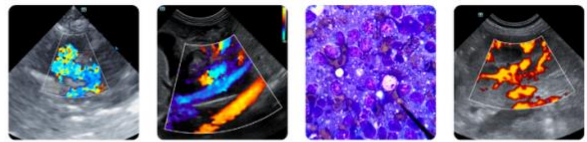
Diet:

No special considerations are necessary. Any high-quality food from Hills, Royal Canin, Science Diet, Eukanuba, Iams, or Purina is reasonable.

Activity:

No special considerations are necessary





**PATIENT**

Cooper Chrusch

**SPECIES**

Canine

**BREED**

French Bulldog

**SEX**

Intact Male

**AGE**

8 Years

**WEIGHT**

~18.0 pounds

**INTERPRETED BY**

Bradley Harris, DVM,  
 DACVECC, DACVIM  
 (cardiology)

**IMAGING PERFORMED BY**

Andrea Nicastro DVM,  
 DACVIM

**HOSPITAL NAME**

Dunes Veterinary  
 Clinic

**REFERRING VET**

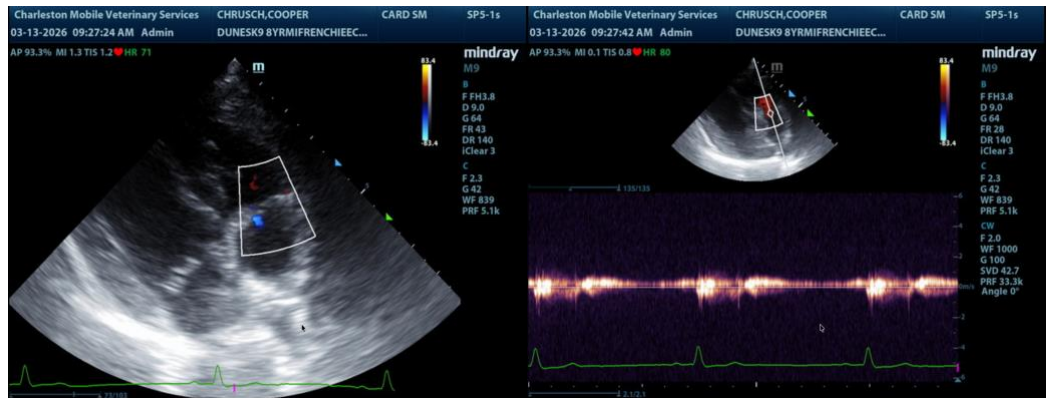
Dr. Devin Soileau

**INVOICE**

14320

**DATE**

03/13/26



The information and recommendations provided are based on the images presented by the referring veterinarian/sonographer. No evaluation can be communicated regarding pathology that was not visible in the image/video clips provided.

Thank you for this referral. If the clinical or image interpretation does not parallel your findings or if I can be of any further assistance please contact me.

**Bradley Harris, DVM, DACVECC, DACVIM (cardiology)**

[info@SonoPath.com](mailto:info@SonoPath.com)