



**PATIENT**

Arlo Palazzo

**SPECIES**

Canine

**BREED**

Doberman

**SEX**

Neutered Male

**AGE**

4 Years

**WEIGHT**

83 lbs

**INTERPRETED BY**

Brad Harris, DVM,  
DACVECC, DACVIM  
(cardiology)

**IMAGING PERFORMED BY**

Vincent Ravancho, CVT

**HOSPITAL NAME**

Park Ridge Animal  
Hospital

**REFERRING VET**

Dr. Doyle

**INVOICE**

73672

**DATE**

3/13/26

**PRESENTING CLINICAL SIGNS**

Breed scan for heart issues. No murmur/arrhythmias. Unremarkable PE

Current medications - Paxil 60mg, Dasuquin, Wellactin, Calming care, Melatonin, Fortiflora

**ULTRASONOGRAPHIC EXAMINATION OF THE HEART**

CANINE CARDIAC PARAMETERS	BW	HR BPM	LAD 4 ch Long	RAD 4 ch Long	La/Ao Heart Base	LVIDd	LVIDs
NORMAL PARAMETER		50-100			<1.6		
PATIENT	37.73	NM	4.71	3.14	NM	4.14	3.0
CANINE CARDIAC PARAMETERS	FS	EPSS	PV V MAX (m/s)	AV V Max (m/sec)	MR Vmax	TR Vmax	RPA distensibility (normal >30%)
NORMAL PARAMETER	28-40	<0.6	0.7-1.6	0.7-1.7	4.5-5.5	< 2.7	
PATIENT	28	0.4	1.4	2.2	NM	NM	NM

**Cardiac Presentation**

The left atrium is normal in dimension. The left ventricle is normal in dimension, with adequate systolic function. The right atrium and ventricle are normal in dimension, with normal systolic function. The anterior and posterior mitral valve leaflets are appropriately thin with adequate apposition, intact chordae, and there is no significant prolapse. There is mild mitral regurgitation identified. The tricuspid valve leaflets are appropriately thin with adequate apposition, intact chordae, no significant tricuspid regurgitation and no evidence of pulmonary hypertension. The left ventricular outflow tract demonstrated normal laminar flow and the visible aorta is unremarkable. The right ventricular outflow tract assessment revealed normal laminar flow, and appropriate diameter and distensibility. There is no pulmonic and no aortic valve insufficiency identified. There is no visible pericardial, pleural, or free peritoneal fluid documented. No evidence of hepatic venous congestion is noted. The cardiac chambers, pericardial and visible extra-cardiac regions were free of masses, spontaneous echo contrast, or thrombi.

**ULTRASONOGRAPHIC FINDINGS**

- These findings are consistent with degenerative/myxomatous mitral valve disease with minimal to mild hemodynamic effects consistent with ACVIM Stage B1 disease. It is unlikely that any current morbidity is of cardiac origin.



**PATIENT**

Arlo Palazzo

**SPECIES**

Canine

**BREED**

Doberman

**SEX**

Neutered Male

**AGE**

4 Years

**WEIGHT**

83 lbs

**INTERPRETED BY**

Brad Harris, DVM,  
 DACVECC, DACVIM  
 (cardiology)

**IMAGING PERFORMED BY**

Vincent Ravancho, CVT

**HOSPITAL NAME**

Park Ridge Animal  
 Hospital

**REFERRING VET**

Dr. Doyle

**INVOICE**

73672

**DATE**

3/13/26

**INTERPRETATION OF THE FINDINGS & FURTHER RECOMMENDATIONS**

Given these findings, no cardiac therapy is recommended. There are no cardiac contraindications to anesthesia, fluid therapy, vasopressor therapy, or corticosteroids as indicated for further assessment and treatment. If not already performed, baseline thoracic radiographs and blood pressure are recommended. A recheck echocardiogram is recommended in 6 months.

Anesthesia considerations:

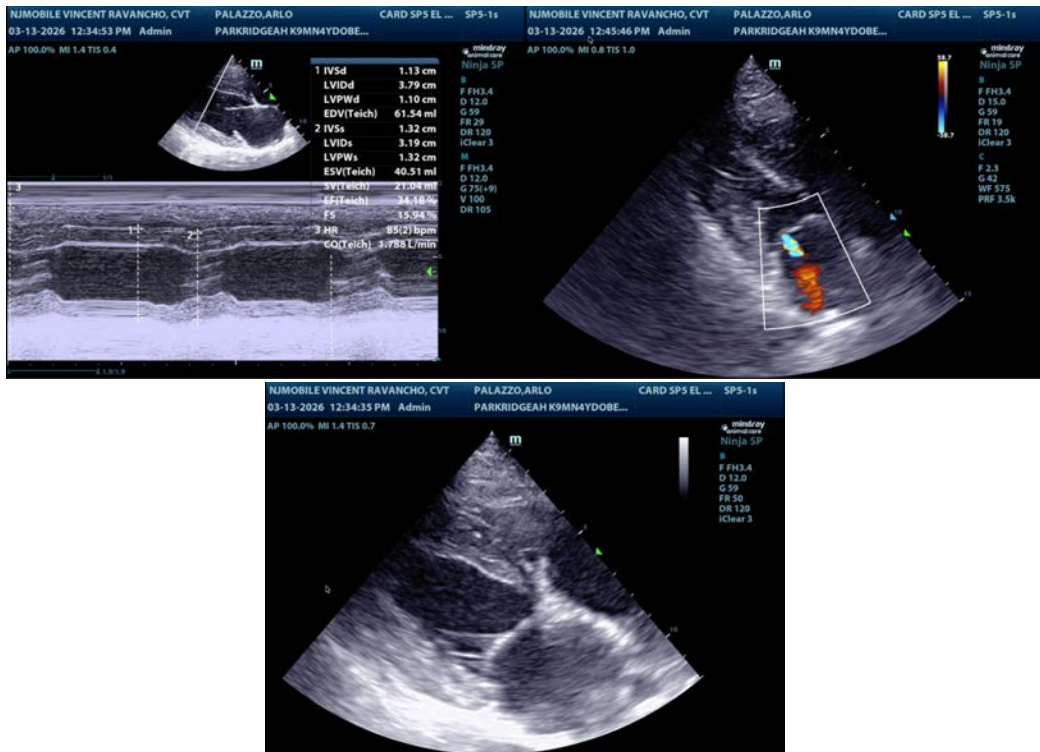
If anesthesia is necessary, alpha-2 agonists, ketamine, high dose acepromazine, and Telazol should be avoided. Fluid therapy during anesthesia should be considered at a conservative rate (e.g., 5 ml/kg/hour) if possible.

Diet:

A high-quality food from Hills, Royal Canin, Science Diet, Eukanuba, Iams, or Purina that is highly palatable with adequate protein and calories for maintaining optimal body condition is reasonable.

Activity:

No special considerations are necessary.





**PATIENT**

Arlo Palazzo

**SPECIES**

Canine

**BREED**

Doberman

**SEX**

Neutered Male

**AGE**

4 Years

**WEIGHT**

83 lbs

**INTERPRETED BY**

Brad Harris, DVM,  
DACVECC, DACVIM  
(cardiology)

**IMAGING  
PERFORMED BY**

Vincent Ravancho, CVT

**HOSPITAL NAME**

Park Ridge Animal  
Hospital

**REFERRING VET**

Dr. Doyle

**INVOICE**

73672

**DATE**

3/13/26

The information and recommendations provided are based on the images presented by the referring veterinarian/sonographer. No evaluation can be communicated regarding pathology that was not visible in the image/video clips provided.

Thank you for this referral. If the clinical or image interpretation does not parallel your findings or if I can be of any further assistance please contact me.

**Brad Harris, DVM, DACVECC, DACVIM (cardiology)**

[info@SonoPath.com](mailto:info@SonoPath.com)