

PATIENT

Winston Shruder
Sherry

SPECIES

Canine

BREED

Boston Terrier

SEX

MN

AGE

14 years

WEIGHT

12.2 kg

INTERPRETED BY

Bradley Harris, DVM,
DACVECC, DACVIM
(cardiology)

IMAGING PERFORMED BY

Dr. Mark VanCampen

HOSPITAL NAME

Renfrew Animal
Hospital

REFERRING VET

Dr. Mark VanCampen

INVOICE

11475

DATE

3/12/2026

PRESENTING CLINICAL SIGNS

- Historical grade I HM - recently Grade III - PMI left apex.
- CXR - VHS 10.5 - no change from Jan 2024.
- Recently noted decreased activity and increased coughing and gagging.
- This exam is to prepare for a dental surgery .

ULTRASONOGRAPHIC EXAMINATION OF THE HEART

CANINE CARDIAC PARAMETERS	BW	HR BPM	LAD 4 ch Long	RAD 4 ch Long	La/Ao Heart Base	LVIDd	LVIDs
NORMAL PARAMETER		50-100			<1.6		
PATIENT	11.09 kg	170	3.03	2.05	1.26	2.90	1.91
CANINE CARDIAC PARAMETERS	FS	EPSS	PV V MAX (m/s)	AV V Max (m/sec)	MR Vmax	TR Vmax	RPA distensibility (normal >30%)
NORMAL PARAMETER	28-40	<0.6	0.7-1.6	0.7-1.7	4.5-5.5	< 2.7	
PATIENT	34	0.2	0.6	1.0	5.0	3.8	38%

Cardiac Presentation

The left atrium is normal in dimension. The left ventricle is normal in dimension, with normal systolic function. The right atrium and ventricle are normal in dimension, with normal systolic function. The anterior and posterior mitral valve leaflets are thickened and redundant consistent with myxomatous changes, and there is moderate prolapse. There is mild to moderate mitral regurgitation identified. The tricuspid valve leaflets are thickened and redundant, with mild to moderate tricuspid regurgitation and evidence of moderate pulmonary hypertension. The left ventricular outflow tract demonstrated normal laminar flow and the visible aorta is unremarkable. The right ventricular outflow tract assessment revealed normal laminar flow, and appropriate diameter and distensibility. There is no pulmonic and no aortic valve insufficiency identified. There is no visible pericardial, pleural, or free peritoneal fluid documented. No evidence of hepatic venous congestion is noted. The cardiac chambers, pericardial and visible extra-cardiac regions were free of masses, spontaneous echo contrast, or thrombi.

ULTRASONOGRAPHIC FINDINGS

- These findings identify degenerative mitral valve disease with minimal to no hemodynamic effects in the presence of mild pulmonary hypertension (PH). In the absence of more convincing left sided enlargement, the PH is more likely related to primary respiratory disease or other etiology (non-type 2 PH). Pulmonary hypertension in dogs is most commonly secondary to primary respiratory disease (chronic bronchitis, pulmonary fibrosis, or other forms of pulmonary interstitial disease). Pulmonary hypertension can also develop in dogs



PATIENT

Winston Shruder
Sherry

SPECIES

Canine

BREED

Boston Terrier

SEX

MN

AGE

14 years

WEIGHT

12.2 kg

INTERPRETED BY

Bradley Harris, DVM,
DACVECC, DACVIM
(cardiology)

IMAGING PERFORMED BY

Dr. Mark VanCampen

HOSPITAL NAME

Renfrew Animal
Hospital

REFERRING VET

Dr. Mark VanCampen

INVOICE

11475

DATE

3/12/2026

with severe heartworm disease or secondary to pulmonary thromboembolism (PTE). Less commonly, pulmonary hypertension is identified in dogs as an idiopathic condition.

INTERPRETATION OF THE FINDINGS & FURTHER RECOMMENDATIONS

Given these findings, no cardiac therapy is recommended. There are no cardiac contraindications to anesthesia, fluid therapy, vasopressor therapy, or corticosteroids as indicated for further assessment and treatment. If not already performed, baseline thoracic radiographs and blood pressure are recommended. A recheck echocardiogram is recommended in 6 months.

Anesthesia considerations:

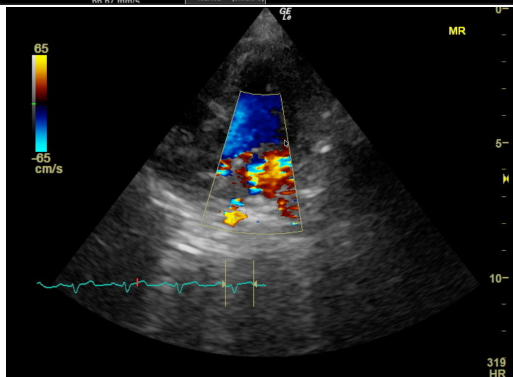
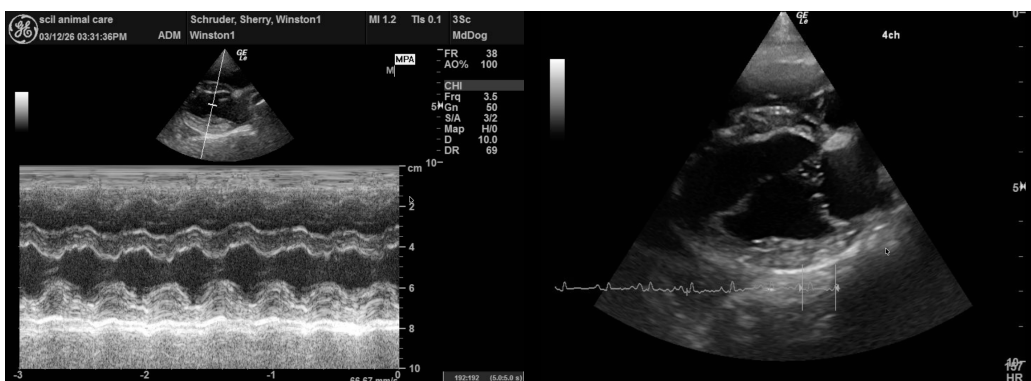
While there is no CHF present, there is likely an increased anesthetic risk which must be considered prior to any anesthetic procedure. If anesthesia is necessary, then alpha-2 agonists, ketamine, and Telazol should be avoided. Fluid therapy during anesthesia does not necessarily need to be adjusted. A shorter anesthetic duration will reduce the risk of complications. Pre-oxygenation is mandatory. Premedication with an opioid (e.g., butorphanol, hydromorphone, oxymorphone) with or without a benzodiazepine is generally the safest protocol. An induction agent such as Propofol, alfaxalone, or diazepam/etomidate can be used to effect. Maintenance of anesthesia with isoflurane or sevoflurane is reasonable.

Diet:

A high-quality food from Hills, Royal Canin, Science Diet, Eukanuba, Iams, or Purina that is highly palatable with adequate protein and calories for maintaining optimal body condition is reasonable.

Activity:

No special considerations are necessary.





PATIENT

Winston Shruder
Sherry

SPECIES

Canine

BREED

Boston Terrier

SEX

MN

AGE

14 years

WEIGHT

12.2 kg

INTERPRETED BY

Bradley Harris, DVM,
DACVECC, DACVIM
(cardiology)

IMAGING PERFORMED BY

Dr. Mark VanCampen

HOSPITAL NAME

Renfrew Animal
Hospital

REFERRING VET

Dr. Mark VanCampen

INVOICE

11475

DATE

3/12/2026

The information and recommendations provided are based on the images presented by the referring veterinarian/sonographer. No evaluation can be communicated regarding pathology that was not visible in the image/video clips provided.

Thank you for this referral. If the clinical or image interpretation does not parallel your findings or if I can be of any further assistance please contact me.

Bradley Harris, DVM, DACVECC, DACVIM (cardiology)

info@SonoPath.com