



PATIENT

Pepe Hartman

SPECIES

Canine

BREED

Terrier Mix

SEX

Neutered Male

AGE

12 Years

WEIGHT

6 kg

INTERPRETED BY

Bradley Harris, DVM,
DACVECC, DACVIM
(cardiology)

IMAGING PERFORMED BY

Catherine Alexander
LVT

HOSPITAL NAME

NorthStar Veterinary
Sonography PLLC

REFERRING VET

Dr. Phillips

INVOICE

14232

DATE

03/11/26

PRESENTING CLINICAL SIGNS

- Pt presented for excessive coughing that seems to have gotten worse over the last 2 weeks. On exam 3/06/26, tested positive for heartworms and microfilaria negative. X-rays done and findings listed below: heart enlarged; blood pressure normal, and abnormal Cardio BNP. On Pimobendan 2.5mg BID and still coughing through it. On doxycycline 100mg 1/2 tab BID. Still eating food. Started medication on Monday 3/06. Picked up enalapril 5mg 1 tab BID and Cough tablets 1/2 tab TID today 3/10/26.

Abnormal PE/Chem/CBC/UA Results: Radiographic Conclusions/Recommendations: Right-sided cardiomegaly, consistent with heartworm disease. The appearance of the lung fields is also consistent with diffuse inflammation related to heartworm disease or other bronchitis. Blood Pressure: 177/128 (158) 114/66 (74) 121/30 (37) 170/146 (158) 122/71 (83) Cardiac BNP:>1800pmol/L Heartworms: Heartworm disease

ULTRASONOGRAPHIC EXAMINATION OF THE HEART

CANINE CARDIAC PARAMETERS	BW	HR BPM	LAD 4 ch Long	RAD 4 ch Long	La/Ao Heart Base	LVIDd	LVIDs
NORMAL PARAMETER		50-100			<1.6		
PATIENT	6.0	NM	3.42	2.16	1.22	3.51	1.71
CANINE CARDIAC PARAMETERS	FS	EPSS	PV V MAX (m/s)	AV V Max (m/sec)	MR Vmax	TR Vmax	RPA distensibility (normal >30%)
NORMAL PARAMETER	28-40	<0.6	0.7-1.6	0.7-1.7	4.5-5.5	< 2.7	
PATIENT	51	NM	0.9	NM	NM	NM	35

Cardiac Presentation

The left atrium is mildly enlarged. The left ventricle is moderately enlarged, with normal systolic function. The right atrium and ventricle are normal in dimension, with normal systolic function. The anterior and posterior mitral valve leaflets are appropriately thin with adequate apposition, intact chordae, and there is no significant prolapse. There is no significant mitral regurgitation identified. The tricuspid valve leaflets are appropriately thin with adequate apposition, intact chordae, no significant tricuspid regurgitation and no evidence of pulmonary hypertension. The left ventricular outflow tract demonstrated normal laminar flow and the visible aorta is unremarkable. The right ventricular outflow tract assessment revealed normal laminar flow, and appropriate diameter and distensibility. There is no pulmonic and no aortic valve insufficiency identified. There is no visible pericardial, pleural, or free peritoneal fluid documented. No evidence of hepatic venous congestion is noted. The cardiac



PATIENT

Pepe Hartman

SPECIES

Canine

BREED

Terrier Mix

SEX

Neutered Male

AGE

12 Years

WEIGHT

6 kg

INTERPRETED BY

Bradley Harris, DVM,
DACVECC, DACVIM
(cardiology)

IMAGING PERFORMED BY

Catherine Alexander
LVT

HOSPITAL NAME

NorthStar Veterinary
Sonography PLLC

REFERRING VET

Dr. Phillips

INVOICE

14232

DATE

03/11/26

chambers, pericardial and visible extra-cardiac regions were free of masses, spontaneous echo contrast, or thrombi. There is no evidence of heartworm infestation within the right sided cardiac chambers.

ULTRASONOGRAPHIC FINDINGS

- These findings are consistent with degenerative/myxomatous mitral valve disease with moderate hemodynamic effects consistent with ACVIM Stage B2. There is no current evidence of the reported heartworm infestation within the right side.

INTERPRETATION OF THE FINDINGS & FURTHER RECOMMENDATIONS

Given the degree of chamber dilation, cardiac therapy with enalapril (0.5 mg/kg BID assuming normotension and lack of renal insult) and Vetmedin (0.25-0.35 mg/kg BID) is recommended. While there is an increased risk of IV fluids, corticosteroids, or anesthesia, there is no overt objection, as the need likely outweighs the risks. Continued therapy for heartworm disease is indicated as recommended by the American Heartworm Society. If not already performed, baseline thoracic radiographs and blood pressure are recommended. A repeat chest X-rays, BP, and chemistry should be performed again in 1-2 weeks. A repeat echo is indicated in 6 months. Consideration could be given to mitral valve repair (open heart surgery or transcatheter edge to edge repair). Owners should monitor resting respiratory rate at home. Values above 30 breaths/minute or an increase in respiratory rate 10% above baseline should prompt veterinary re-evaluation.

Anesthesia considerations:

While there is no CHF present, there is likely an increased anesthetic risk which must be considered prior to any anesthetic procedure. If anesthesia is necessary, then alpha-2 agonists, ketamine, high dose acepromazine, and Telazol should be avoided. If an ACE inhibitor (enalapril, benazepril) or spironolactone is being given, it should not be administered on the morning of general anesthesia. Other cardiac medications should be administered per the normal dosing schedule. Fluid therapy during anesthesia should be considered at a reduced rate (e.g., 5 ml/kg/hour) if possible. A shorter anesthetic duration will reduce the risk of complications. Pre-oxygenation is advised. Premedication with an opioid (i.e., butorphanol, hydromorphone, oxymorphone) with or without a benzodiazepine is generally the safest protocol. An induction agent such as Propofol, alfaxalone, or diazepam/etomidate can be used to effect. Maintenance of anesthesia with isoflurane or sevoflurane is reasonable. Dobutamine (2.5-10 μ g/kg/min as a CRI, starting at 2.5 μ g/kg/min and increasing the dosage incrementally) may be used in lieu of fluid boluses to augment systemic blood pressure.

Diet:

A high-quality food from Hills, Royal Canin, Science Diet, Eukanuba, Iams, or Purina that is highly palatable with adequate protein and calories for maintaining an optimal body condition is recommended. Consider omega-3 fatty acid supplementation. Avoid any boutique, exotic, or grain-free diets.

Activity:

Moderate physical activity (meandering walks, exploring the backyard, playing with toys inside, getting excited when family gets home, etc.) is encouraged, but periods of strenuous aerobic activity (jogging, strenuous outdoor ball play, prolonged play at the dog park, etc.) should be avoided, especially during periods of high heat (> 80 F) and humidity. Dogs with heart disease tend to tolerate cool and cold temperatures much better than high temperatures. Avoid sudden increases in activity (e.g. 2 block



PATIENT

Pepe Hartman

SPECIES

Canine

BREED

Terrier Mix

SEX

Neutered Male

AGE

12 Years

WEIGHT

6 kg

INTERPRETED BY

Bradley Harris, DVM,
DACVECC, DACVIM
(cardiology)

IMAGING PERFORMED BY

Catherine Alexander
LVT

HOSPITAL NAME

NorthStar Veterinary
Sonography PLLC

REFERRING VET

Dr. Phillips

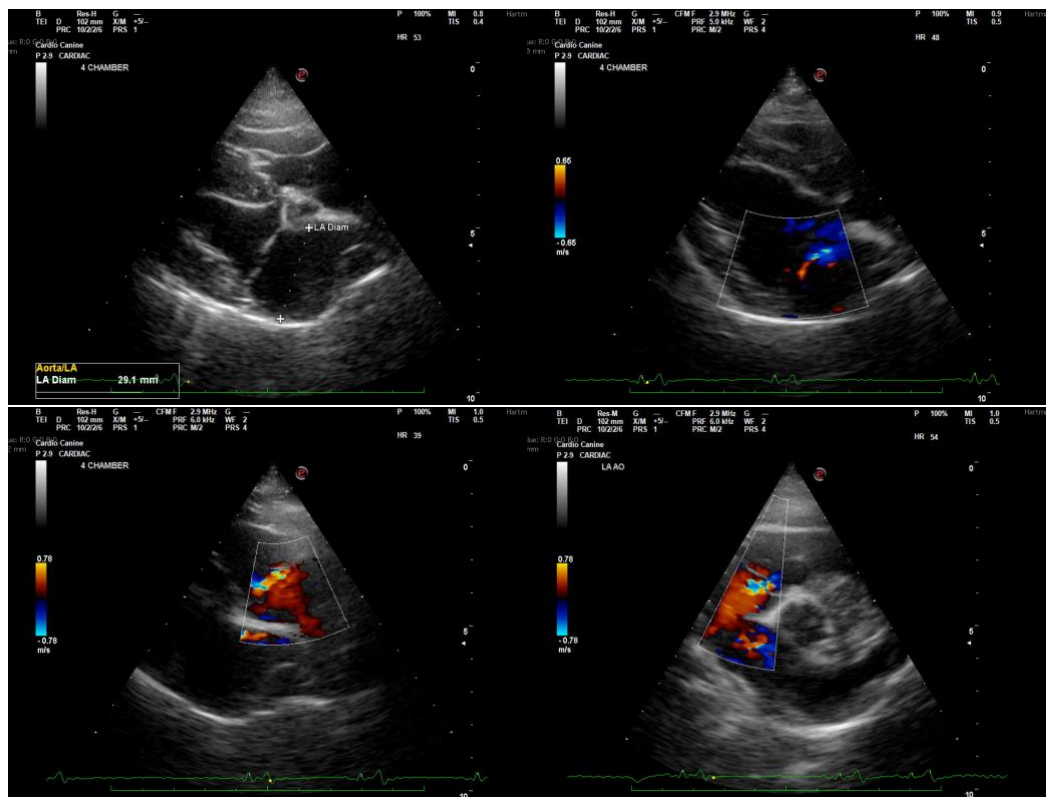
INVOICE

14232

DATE

03/11/26

walks during the week but 2 mile walks followed by 30 minutes at the dog park on the weekends) as this may be difficult for the cardiovascular system to deal with.



The information and recommendations provided are based on the images presented by the referring veterinarian/sonographer. No evaluation can be communicated regarding pathology that was not visible in the image/video clips provided.

Thank you for this referral. If the clinical or image interpretation does not parallel your findings or if I can be of any further assistance please contact me.

Bradley Harris, DVM, DACVECC, DACVIM (cardiology)

info@SonoPath.com