



PATIENT

Monkey Sanders

SPECIES

Feline

BREED

Domestic Shorthair

SEX

Spayed female

AGE

16 years

WEIGHT

6.84 lbs

INTERPRETED BY

Bradley Harris, DVM,
DACVECC, DACVIM
(cardiology)

IMAGING PERFORMED BY

Arielle Roldan, CVT

HOSPITAL NAME

Milford AH

REFERRING VET

Dr. Ascione

INVOICE

71175

DATE

2/3/26

PRESENTING CLINICAL SIGNS

- Presented for exam due to tooth problem, previous vet concerned about increased AST level and recommended abdominal ultrasound. Patient has not been eating well, dx with pancreatitis at time of exam and owner presented today for ultrasound and pancreatitis treatment.
- Patient is fractious, had to be sedated in order to scan/treat.
- Is in need of a dental as well due to possible tooth root abscess
- No heart murmur noted upon exam
- Attached previous bloodwork and in house, additional results: FPL 38.9 ng/ml consistent with pancreatitis (>5.4) TNL 0.19 ng/ml gray zone (0.18-0.28) PROBNP <50 pmol/L WNL SAA <5 ug/ml WNL

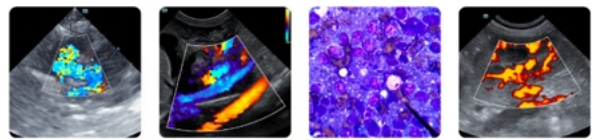
ULTRASONOGRAPHIC EXAMINATION OF THE HEART

The left atrium is normal in dimension. There are no distinct left atrial thrombi/clots or spontaneous echo contrast appreciated. The left ventricle is normal in dimension as well as wall thickness, and no evidence of restriction. Left ventricular systolic function is normal, with adequate contractility. The right atrium and ventricle are subjectively normal in dimension and systolic function. The anterior and posterior mitral and tricuspid valve leaflets presented normal linear structure, extension in systole, and union in diastole without regurgitation. There is no evidence of systolic anterior mitral valve motion documented. The left ventricular outflow tract demonstrated normal laminar flow and subjective structural valvular integrity. The visible aorta is unremarkable. Pulmonary outflow tract assessment revealed normal valve structure, laminar flow, and appropriate diameter and distensibility. There is no evidence of pulmonary hypertension documented. There is no visible pericardial, pleural, or free peritoneal fluid noted.

FELINE CARDIAC PARAMETERS	BODY WEIGHT (kg)	HR (BPM)	IVSd (cm)	LVIDd (cm)	LVWd (cm)	FS (%)	EF (%)
NORMAL PARAMETER	-----	150-240	0.3-0.6	1.0-2.1	0.25-0.6	35-67	80-100
PATIENT	3.11 kg	NM	0.51	1.51	0.46	45	NM
FELINE CARDIAC PARAMETERS	LA/AO (M-mode)	LA/AO HEART BASE (Sisson)	LAD LA MAX 4 Chamber		LVOT VEL. (m/s)	RVOT VEL. (m/s)	IVRT (m/)
NORMAL PARAMETER	<1.5	1.6	0.7-1.7		<1.6	<1.3	40-60
PATIENT	NM	1.33	1.17		1.9	0.8	NM
Adapted from June Boon, Veterinary Echocardiography, 1998 Sisson D et al. JVIM 1991; 5: 232, Jacobs et al. Am J Vet Res 1985; 46:1705							

ULTRASONOGRAPHIC FINDINGS

These findings are consistent with an essentially normal echocardiogram. Any murmur auscultated will be considered functional in origin.



PATIENT

Monkey Sanders

SPECIES

Feline

BREED

Domestic Shorthair

SEX

Spayed female

AGE

16 years

WEIGHT

6.84 lbs

INTERPRETED BY

Bradley Harris, DVM,
DACVECC, DACVIM
(cardiology)

IMAGING PERFORMED BY

Arielle Roldan, CVT

HOSPITAL NAME

Milford AH

REFERRING VET

Dr. Ascione

INVOICE

71175

DATE

2/3/26

INTERPRETATION OF THE FINDINGS & FURTHER RECOMMENDATIONS

Given these findings, no cardiac therapy is recommended. There are no cardiac contraindications to corticosteroids or fluid therapy as indicated for further treatment. No specific recheck echocardiogram is recommended.

Anesthesia considerations:

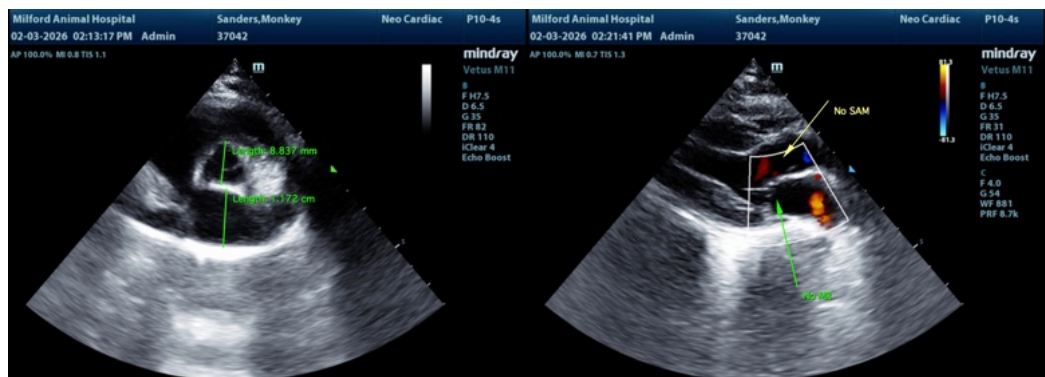
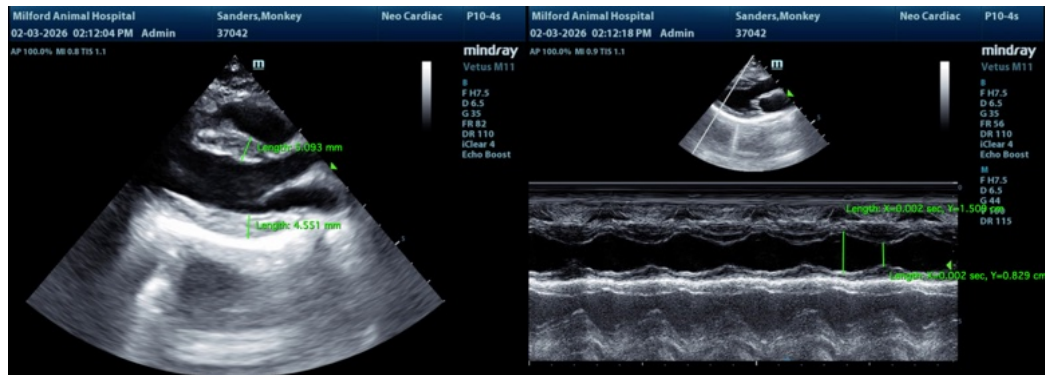
No special cardiac considerations are necessary

Diet:

No special considerations are necessary. Any high-quality food from Hills, Royal Canin, Science Diet, Eukanuba, Iams, or Purina is reasonable.

Activity:

No special considerations are necessary.



The information and recommendations provided are based on the images presented by the referring veterinarian/sonographer. No evaluation can be communicated regarding pathology that was not visible in the image/video clips provided.

Thank you for this referral. If the clinical or image interpretation does not parallel your findings or if I can be of any further assistance please contact me.

Bradley Harris, DVM, DACVECC, DACVIM (cardiology)

info@SonoPath.com