



PATIENT

Kennebec Kurt

SPECIES

Canine

BREED

Shih Tzu

SEX

Spayed female

AGE

12 years

WEIGHT

14.5 lbs

INTERPRETED BY

Bradley Harris, DVM,
DACVECC, DACVIM
(cardiology)

IMAGING PERFORMED BY

Christopher Roberts

HOSPITAL NAME

Kentown AH

REFERRING VET

Dr. Roberts

INVOICE

71976

DATE

2/26/26

PRESENTING CLINICAL SIGNS

- History of heart murmur- grade 2/6 systolic murmur, history of hyperadrenocorticism - pituitary dependent.
- Recent concerns for inappetence and mobility. Radiographs performed revealed questionable heart base mass/thoracic bulge on the lateral view cranial to the heart.
- BAR, H/L- grade 2/6 left apical systolic murmur no arrhythmias- HR- 130- increased up to 200 during echo CBC- plt- 502,000 Chem- ALT- 394, ALP - 1011, Tbili- 0.5, BuN- 33, SDMA- 15.8, Chol- 513, Triglycerides- 1691 UA- USG- 1.014, protein- 1+, glucose- trace

ULTRASONOGRAPHIC EXAMINATION OF THE HEART

The left atrium is normal in dimension. The left ventricle is normal in dimension, with normal systolic function. The right atrium and ventricle are normal in dimension, with normal systolic function. The anterior and posterior mitral valve leaflets are thickened and redundant consistent with myxomatous changes, and there is no significant prolapse. There is trivial mitral regurgitation identified. The tricuspid valve leaflets are appropriately thin with adequate apposition, intact chordae, with trivial tricuspid regurgitation and no evidence of pulmonary hypertension. The left ventricular outflow tract demonstrated normal laminar flow and the visible aorta is unremarkable. The right ventricular outflow tract assessment revealed normal laminar flow, and appropriate diameter and distensibility. There is no pulmonic and no aortic valve insufficiency identified. There is no visible pericardial, pleural, or free peritoneal fluid documented. No evidence of hepatic venous congestion is noted. The cardiac chambers, pericardial and visible extra-cardiac regions were free of masses, spontaneous echo contrast, or thrombi.

CANINE CARDIAC PARAMETERS	Body Weight kg	HR BPM	LAD 4 ch Long	RAD 4 ch Long	La/Ao Heart Base	LVIDd	LVIDs
NORMAL PARAMETER		50-100			<1.6		
PATIENT	6.59 kg	120	2.38	1.47	1.44	2.73	1.52
CANINE CARDIAC PARAMETERS	FS	EPSS	PV V MAX (m/s)	AV V Max (m/sec)	MR Vmax	TR Vmax	RPA distensibility (normal >30%)
NORMAL PARAMETER	28-40	<0.6	0.7-1.6	0.7-1.7	4.5-5.5	< 2.7	
PATIENT	44	0.5	0.5	0.7	NM	1.4	31

ULTRASONOGRAPHIC FINDINGS

These findings are consistent with degenerative/myxomatous mitral valve disease with minimal to mild hemodynamic effects consistent with ACVIM Stage B1 disease. It is unlikely that any current morbidity is of cardiac origin.



PATIENT

Kennebec Kurt

SPECIES

Canine

BREED

Shih Tzu

SEX

Spayed female

AGE

12 years

WEIGHT

14.5 lbs

INTERPRETED BY

Bradley Harris, DVM,
DACVECC, DACVIM
(cardiology)

IMAGING PERFORMED BY

Christopher Roberts

HOSPITAL NAME

Kentown AH

REFERRING VET

Dr. Roberts

INVOICE

71976

DATE

2/26/26

INTERPRETATION OF THE FINDINGS & FURTHER RECOMMENDATIONS

Given these findings, no cardiac therapy is recommended. There are no cardiac contraindications to anesthesia, fluid therapy, vasopressor therapy, or corticosteroids as indicated for further assessment and treatment. If not already performed, baseline thoracic radiographs and blood pressure are recommended. A recheck echocardiogram is recommended in 6 months.

Anesthesia considerations:

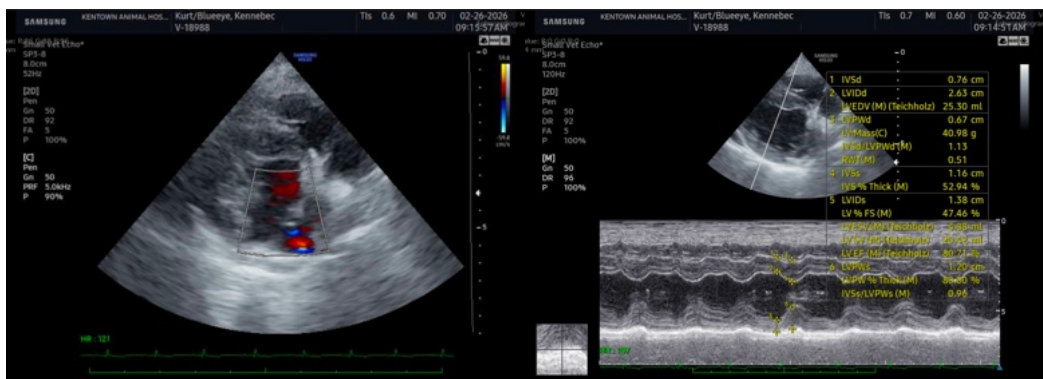
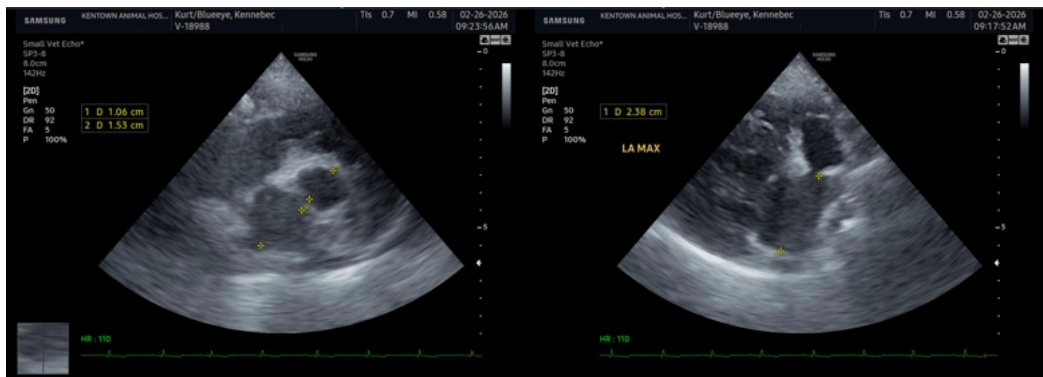
If anesthesia is necessary, alpha-2 agonists, ketamine, high dose acepromazine, and Telazol should be avoided. Fluid therapy during anesthesia should be considered at a conservative rate (e.g., 5 ml/kg/hour) if possible.

Diet:

A high-quality food from Hills, Royal Canin, Science Diet, Eukanuba, Iams, or Purina that is highly palatable with adequate protein and calories for maintaining optimal body condition is reasonable.

Activity:

No special considerations are necessary.



The information and recommendations provided are based on the images presented by the referring veterinarian/sonographer. No evaluation can be communicated regarding pathology that was not visible in the image/video clips provided.

Thank you for this referral. If the clinical or image interpretation does not parallel your findings or if I can be of any further assistance please contact me.



PATIENT

Bradley Harris, DVM, DACVECC, DACVIM (cardiology)

Kennebec Kurt

info@SonoPath.com

SPECIES

Canine

BREED

Shih Tzu

SEX

Spayed female

AGE

12 years

WEIGHT

14.5 lbs

INTERPRETED BY

Bradley Harris, DVM,
DACVECC, DACVIM
(cardiology)

**IMAGING
PERFORMED BY**

Christopher Roberts

HOSPITAL NAME

Kentown AH

REFERRING VET

Dr. Roberts

INVOICE

71976

DATE

2/26/26