



**PATIENT**

Sox Grove

**SPECIES**

Canine

**BREED**

Mix

**SEX**

Neutered male

**AGE**

23 months

**WEIGHT**

26.4 lbs

**INTERPRETED BY**

Bradley Harris, DVM,  
DACVECC, DACVIM  
(cardiology)

**IMAGING PERFORMED BY**

Tiffany Brady, DVM

**HOSPITAL NAME**

Shiloh VH

**REFERRING VET**

Dr. Craig

**INVOICE**

71933

**DATE**

2/17/26

**PRESENTING CLINICAL SIGNS**

- Novel 3/6 heart murmur noted on physical exam. P currently asymptomatic
- BP (taken prior to torb administration) 136, 124, 118 (avg 126) mmHg

**ULTRASONOGRAPHIC EXAMINATION OF THE HEART**

The left atrium is normal in dimension. The left ventricle is normal in dimension, with normal systolic function. The right atrium and ventricle are normal in dimension, with normal systolic function. The anterior and posterior mitral valve leaflets are appropriately thin with adequate apposition, intact chordae, and there is no significant prolapse. There is no significant mitral regurgitation identified. The tricuspid valve leaflets are appropriately thin with adequate apposition, intact chordae, no significant tricuspid regurgitation and no evidence of pulmonary hypertension. The left ventricular outflow tract demonstrated normal laminar flow and the visible aorta is unremarkable. The right ventricular outflow tract assessment revealed normal laminar flow, and appropriate diameter and distensibility. There is no pulmonic and no aortic valve insufficiency identified. There is no visible pericardial, pleural, or free peritoneal fluid documented. No evidence of hepatic venous congestion is noted. The cardiac chambers, pericardial and visible extra-cardiac regions were free of masses, spontaneous echo contrast, or thrombi. Thoracic radiographs are unremarkable with a normal cardiac silhouette and no evidence for chamber dilation or pulmonary venous distention.

| CANINE CARDIAC PARAMETERS | Body Weight kg | HR BPM | LAD 4 ch Long  | RAD 4 ch Long    | La/Ao Heart Base | LVIDd       | LVIDs                            |
|---------------------------|----------------|--------|----------------|------------------|------------------|-------------|----------------------------------|
| NORMAL PARAMETER          |                | 50-100 |                |                  | <1.6             |             |                                  |
| PATIENT                   | 12 kg          | NM     | NM             | NM               | 0.98             | 2.76        | 1.69                             |
| CANINE CARDIAC PARAMETERS | FS             | EPSS   | PV V MAX (m/s) | AV V Max (m/sec) | MR Vmax          | TR Vmax     | RPA distensibility (normal >30%) |
| NORMAL PARAMETER          | 28-40          | <0.6   | 0.7-1.6        | 0.7-1.7          | 4.5-5.5          | < 2.7       |                                  |
| PATIENT                   | 39             | NM     | 0.9            | 1.0              | Not present      | Not present | NM                               |

**ULTRASONOGRAPHIC FINDINGS**

- These findings are consistent with an essentially normal echocardiogram. Any murmur will be considered functional in origin. No cardiac cause of the morbidity is identified.



## PATIENT

Sox Grove

## SPECIES

Canine

## BREED

Mix

## SEX

Neutered male

## AGE

23 months

## WEIGHT

26.4 lbs

## INTERPRETED BY

Bradley Harris, DVM,  
DACVECC, DACVIM  
(cardiology)

## IMAGING PERFORMED BY

Tiffany Brady, DVM

## HOSPITAL NAME

Shiloh VH

## REFERRING VET

Dr. Craig

## INVOICE

71933

## DATE

2/17/26

## INTERPRETATION OF THE FINDINGS & FURTHER RECOMMENDATIONS

Given these findings, no cardiac therapy is recommended. There are no cardiac contraindications to fluid therapy or corticosteroid therapy, as indicated for further assessment and treatment. No specific cardiac recheck is recommended unless a murmur or clinical signs of heart disease develop.

### Anesthesia considerations:

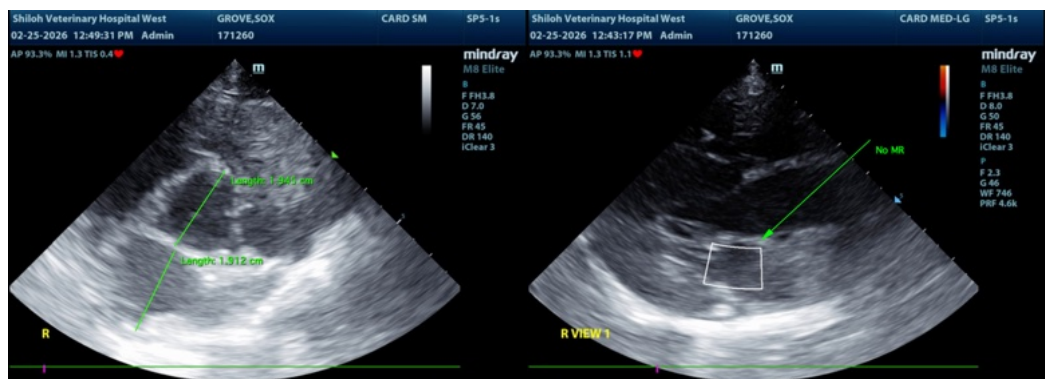
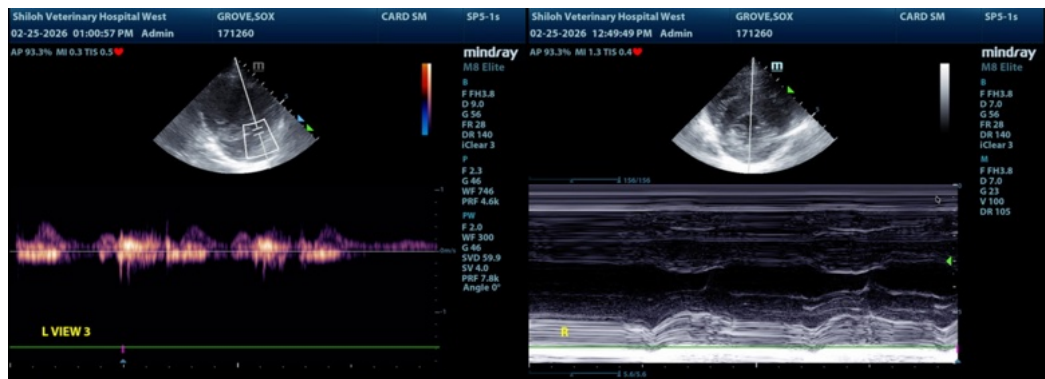
No special considerations are necessary.

### Diet:

No special considerations are necessary. Any high-quality food from Hills, Royal Canin, Science Diet, Eukanuba, Iams, or Purina is reasonable.

### Activity:

No special considerations are necessary.



The information and recommendations provided are based on the images presented by the referring veterinarian/sonographer. No evaluation can be communicated regarding pathology that was not visible in the image/video clips provided.

Thank you for this referral. If the clinical or image interpretation does not parallel your findings or if I can be of any further assistance please contact me.

Bradley Harris, DVM, DACVECC, DACVIM (cardiology)

[info@SonoPath.com](mailto:info@SonoPath.com)