



**PATIENT**

Leo Lopes

**SPECIES**

Canine

**BREED**

Australian Shepherd x

**SEX**

Neutered Male

**AGE**

11 Years

**WEIGHT**

32 kg

**INTERPRETED BY**

Brad Harris, DVM,  
 DACVECC, DACVIM  
 (cardiology)

**IMAGING PERFORMED BY**

Crystal Hill

**HOSPITAL NAME**

BPH Stoney Creek

**REFERRING VET**

Dr. Beckstead

**INVOICE**

73200

**DATE**

2/23/26

**PRESENTING CLINICAL SIGNS**

ADR, hyporexic, lethargic, pale MMs and potty belly, Hemoabdomen? AFAST and abdominocentesis revealed frank blood. Start Gabapentin and Yunnan Baiyou

Abnormal PE/Chem/CBC/UA Results: Rads revealed loss of detail, borders of liver and spleen not detected, poorly defined oval soft tissue structure mid ventrally, concerns for enlarged right heart. HCT 22% PLT 41K/uL PCT 0.07% TT4 11 rest WNL

**ULTRASONOGRAPHIC EXAMINATION OF THE HEART**

CANINE CARDIAC PARAMETERS	BW	HR BPM	LAD 4 ch Long	RAD 4 ch Long	La/Ao Heart Base	LVIDd	LVIDs
NORMAL PARAMETER		50-100			<1.6		
PATIENT	32	NM	3.82	2.86	1.09	4.2	2.38
CANINE CARDIAC PARAMETERS	FS	EPSS	PV V MAX (m/s)	AV V Max (m/sec)	MR Vmax	TR Vmax	RPA distensibility (normal >30%)
NORMAL PARAMETER	28-40	<0.6	0.7-1.6	0.7-1.7	4.5-5.5	< 2.7	
PATIENT	43	0.3	1.6	2.3	NM	2.4	36

**Cardiac Presentation**

The left atrium is normal in dimension. The left ventricle is normal in dimension, with normal systolic function. The right atrium and ventricle are normal in dimension, with normal systolic function. The anterior and posterior mitral valve leaflets are appropriately thin with adequate apposition, intact chordae, and there is no significant prolapse. There is no significant mitral regurgitation identified. The tricuspid valve leaflets are appropriately thin with adequate apposition, intact chordae, with trivial tricuspid regurgitation and no evidence of pulmonary hypertension. The left ventricular outflow tract demonstrated normal laminar flow and the visible aorta is unremarkable. The right ventricular outflow tract assessment revealed normal laminar flow, and appropriate diameter and distensibility. There is no pulmonic and no aortic valve insufficiency identified. There is no visible pericardial or pleural effusion, and mild to moderate free peritoneal fluid is documented. No evidence of hepatic venous congestion is noted. The cardiac chambers, pericardial and visible extra-cardiac regions were free of masses, spontaneous echo contrast, or thrombi.

**ULTRASONOGRAPHIC FINDINGS**

- These findings are consistent with an essentially normal echocardiogram. Any murmur will be considered functional in origin. No cardiac cause of the morbidity is identified.



**PATIENT**

Leo Lopes

**SPECIES**

Canine

**BREED**

Australian Shepherd x

**SEX**

Neutered Male

**AGE**

11 Years

**WEIGHT**

32 kg

**INTERPRETED BY**

Brad Harris, DVM,  
 DACVECC, DACVIM  
 (cardiology)

**IMAGING PERFORMED BY**

Crystal Hill

**HOSPITAL NAME**

BPH Stoney Creek

**REFERRING VET**

Dr. Beckstead

**INVOICE**

73200

**DATE**

2/23/26

**INTERPRETATION OF THE FINDINGS & FURTHER RECOMMENDATIONS**

Given these findings, no cardiac therapy is recommended. There are no cardiac contraindications to fluid therapy or corticosteroid therapy, as indicated for further assessment and treatment. No specific cardiac recheck is recommended unless a murmur or clinical signs of heart disease develop.

Anesthesia considerations:

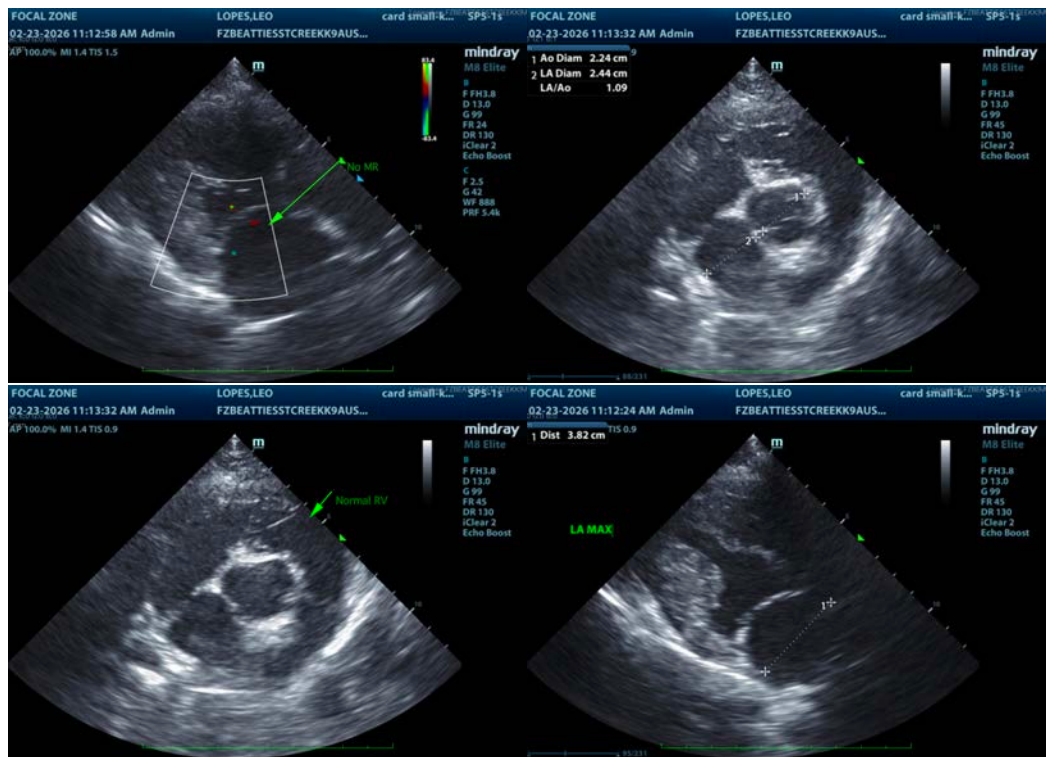
No special considerations are necessary.

Diet:

No special considerations are necessary. Any high-quality food from Hills, Royal Canin, Science Diet, Eukanuba, Iams, or Purina is reasonable.

Activity:

No special considerations are necessary.





**PATIENT**

Leo Lopes

**SPECIES**

Canine

**BREED**

Australian Shepherd x

**SEX**

Neutered Male

**AGE**

11 Years

**WEIGHT**

32 kg

**INTERPRETED BY**

Brad Harris, DVM,  
 DACVECC, DACVIM  
 (cardiology)

**IMAGING PERFORMED BY**

Crystal Hill

**HOSPITAL NAME**

BPH Stoney Creek

**REFERRING VET**

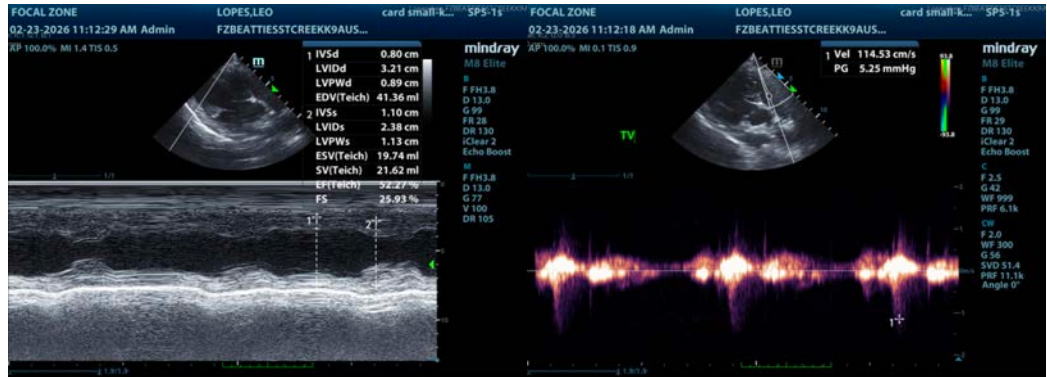
Dr. Beckstead

**INVOICE**

73200

**DATE**

2/23/26



The information and recommendations provided are based on the images presented by the referring veterinarian/sonographer. No evaluation can be communicated regarding pathology that was not visible in the image/video clips provided.

Thank you for this referral. If the clinical or image interpretation does not parallel your findings or if I can be of any further assistance please contact me.

**Brad Harris, DVM, DACVECC, DACVIM (cardiology)**

[info@SonoPath.com](mailto:info@SonoPath.com)