

PATIENT

Griffith Snyder

SPECIES

Canine

BREED

Doberman Pinscher

SEX

Intact Male

AGE

3 Years

WEIGHT

77 lbs

INTERPRETED BY

Brad Harris, DVM,
 DACVECC, DACVIM
 (cardiology)

IMAGING PERFORMED BY

Kathleen Byrnes

HOSPITAL NAME

Scotts Creek Animal
 Hospital

REFERRING VET

Dr. Cartner

INVOICE

73150

DATE

2/20/26

PRESENTING CLINICAL SIGNS

P presented to ER clinic a few days prior for respiratory distress, Rads showed enlarged heart, pulmonary edema, ProBNP 4000

Started on Pimobendan and Furosemide- doing better

ULTRASONOGRAPHIC EXAMINATION OF THE HEART

CANINE CARDIAC PARAMETERS	BW	HR BPM	LAD 4 ch Long	RAD 4 ch Long	La/Ao Heart Base	LVIDd	LVIDs
NORMAL PARAMETER		50-100			<1.6		
PATIENT	35.0	170	6.65	3.33	2.01	5.95	4.94
CANINE CARDIAC PARAMETERS	FS	EPSS	PV V MAX (m/s)	AV V Max (m/sec)	MR Vmax	TR Vmax	RPA distensibility (normal >30%)
NORMAL PARAMETER	28-40	<0.6	0.7-1.6	0.7-1.7	4.5-5.5	< 2.7	
PATIENT	17	2.3	1.2	1.3	3.8	2.9	NM

Cardiac Presentation

The left atrium is severely enlarged. The left ventricle is moderately enlarged with severely reduced systolic function. The right atrium and ventricle are normal in dimension with normal systolic function. The anterior and posterior mitral valve leaflets are appropriately thin but do not completely appose during systole due to annular dilation, and there is no significant prolapse. There is mild mitral regurgitation identified. The tricuspid valve leaflets are appropriately thin with adequate apposition, intact chordae, with mild tricuspid regurgitation and no evidence of pulmonary hypertension. The left ventricular outflow tract demonstrated normal laminar flow, and the visible aorta is unremarkable. The right ventricular outflow tract assessment revealed normal laminar flow and appropriate diameter and distensibility. There is no pulmonic and no aortic valve insufficiency identified. There is no visible pericardial, pleural, or free peritoneal fluid documented. No evidence of hepatic venous congestion is noted. The cardiac chambers, pericardial and visible extra-cardiac regions were free of masses, spontaneous echo contrast, or thrombi.

Electrocardiogram

The underlying rhythm is sinus in origin with a consistent R-R interval and average heart rate of 170bpm. The majority of the QRS complexes are supraventricular in origin with consistent P-Q intervals. There is a rare QRS complexes that are prolonged in duration (>70ms), suggesting a ventricular origin. There is no evidence of atrioventricular block or atrial ectopy identified. This is most consistent with an underlying sinus rhythm with rare ventricular ectopy.



PATIENT

Griffith Snyder

SPECIES

Canine

BREED

Doberman Pinscher

SEX

Intact Male

AGE

3 Years

WEIGHT

77 lbs

INTERPRETED BY

Brad Harris, DVM,
 DACVECC, DACVIM
 (cardiology)

IMAGING PERFORMED BY

Kathleen Byrnes

HOSPITAL NAME

Scotts Creek Animal
 Hospital

REFERRING VET

Dr. Cartner

INVOICE

73150

DATE

2/20/26

ULTRASONOGRAPHIC FINDINGS

These findings are consistent with dilated cardiomyopathy with significant hemodynamic effects. Intrinsic myocardial dysfunction (ie DCM) is a concern given the breed. Other possibilities, including primary valve disease with secondary ventricular changes or myocardial depressant effects of systemic disease must also be considered. It would also be important to verify that the owners are not feeding a grain-free, exotic, or boutique diet, as a secondary nutritional cardiomyopathy must also be considered. Given the degree of chamber enlargement and recent thoracic radiographs, congestive heart failure is a likely explanation for the clinical/radiographic signs. Ventricular arrhythmias occur in many clinical settings, generally divided into cardiac and non-cardiac causes. Cardiac conditions include structural heart disease, pericardial effusion/cardiac neoplasia, and rarely myocarditis. Non-cardiac causes are common and include splenic disease, metabolic disease, electrolyte disturbances, tick-borne disease, fever, anemia, trauma, GDV, hepatic disease, GI disease, pancreatitis, DIC, and sepsis.

INTERPRETATION OF THE FINDINGS & FURTHER RECOMMENDATIONS

Therapy for CHF is recommended, with Lasix (2mg/kg BID), enalapril (0.5mg/kg BID assuming normotension and lack of renal insult), and Vetmedin (.25-.35mg/kg BID). If the owners are feeding a grain free diet, an immediate diet change would be necessary, and the addition of taurine (50 mg/kg BID) would be appropriate. If there is any concern for metabolic/systemic disease, additional testing (complete bloodwork including T4 and resting cortisol, abdominal ultrasound) should be considered. Otherwise, a repeat chest X-rays, BP, and chemistry should be performed now for a baseline, and again in 1-2 weeks. A repeat echo is indicated in 3 months. Owners should monitor resting respiratory rate at home. Values above 30 breaths/minute or an increase in respiratory rate 10% above baseline should prompt veterinary re-evaluation.

The following sources for supplemental taurine are recommended:

- Mega taurine caps by Twinlab (1000mg capsule)
- Taurine by Swanson Health Products (500mg capsule)
- Taurine by NOW foods (500mg capsule)
- Taurine 500 by GNC (500mg tablet)

Anesthesia considerations:

Anesthesia should be avoided until manifestations of congestive heart failure (edema/effusion/respiratory distress) have resolved. Following that time, if anesthesia is necessary, then alpha-2 agonists, ketamine, high dose acepromazine, and Telazol should be avoided. If an ACE inhibitor (enalapril, benazepril) or spironolactone is being given, it should not be administered on the morning of general anesthesia. Other cardiac medications should be administered per the normal dosing schedule. Anesthetic IV fluid use should be limited to < 3 ml/kg/hr and, if IV fluid therapy is administered during the procedure, a 1 mg/kg dose of IM Lasix should be administered when the patient is awake and standing in recovery. A shorter anesthetic duration will reduce the risk of complications. Pre-oxygenation is advised. Premedication with an opioid (i.e., butorphanol, hydromorphone, oxymorphone) with or without a benzodiazepine is generally the safest protocol. An induction agent such as Propofol, alfaxalone, or diazepam/etomidate can be used to effect. Maintenance of anesthesia with isoflurane or sevoflurane is reasonable. Dobutamine (2.5-10 µg/kg/min as a CRI, starting at 2.5 µg/kg/min and increasing the dosage incrementally) may be used in lieu of fluid boluses to augment systemic blood pressure.



PATIENT

Griffith Snyder

SPECIES

Canine

BREED

Doberman Pinscher

SEX

Intact Male

AGE

3 Years

WEIGHT

77 lbs

INTERPRETED BY

Brad Harris, DVM,
 DACVECC, DACVIM
 (cardiology)

IMAGING PERFORMED BY

Kathleen Byrnes

HOSPITAL NAME

Scotts Creek Animal
 Hospital

REFERRING VET

Dr. Cartner

INVOICE

73150

DATE

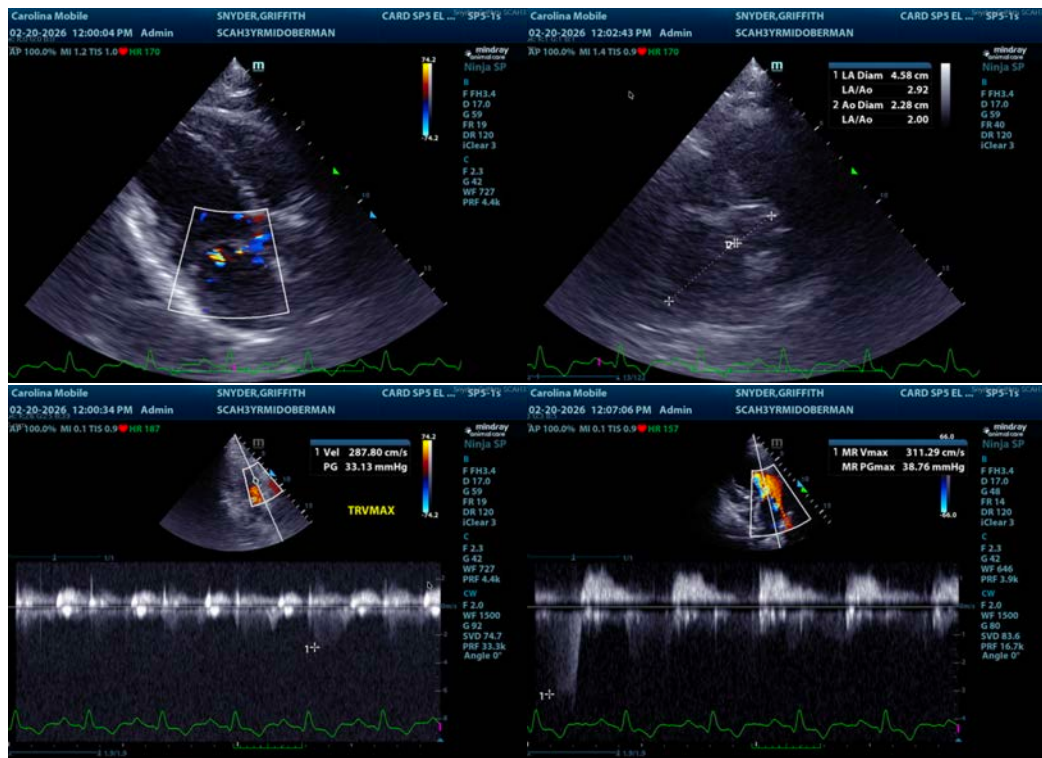
2/20/26

Diet:

A high-quality food from Hills, Royal Canin, Science Diet, Eukanuba, Iams, or Purina that is highly palatable with adequate protein and calories for maintaining optimal body condition with mild dietary sodium restriction (< 100 mg/100 kcal) is recommended. Consider omega-3 fatty acid supplementation. Avoid any boutique, exotic, or grain-free diets.

Activity:

Moderate physical activity (meandering walks, exploring the backyard, playing with toys inside, getting excited when family gets home, etc.) is encouraged, but periods of strenuous aerobic activity (jogging, strenuous outdoor ball play, prolonged play at the dog park, etc.) should be avoided, especially during periods of high heat (> 80 F) and humidity. Dogs with heart disease tend to tolerate cool and cold temperatures much better than high temperatures. Avoid sudden increases in activity (e.g. 2 block walks during the week but 2 mile walks followed by 30 minutes at the dog park on the weekends) as this may be difficult for the cardiovascular system to deal with.





PATIENT

Griffith Snyder

SPECIES

Canine

BREED

Doberman Pinscher

SEX

Intact Male

AGE

3 Years

WEIGHT

77 lbs

INTERPRETED BY

Brad Harris, DVM,
 DACVECC, DACVIM
 (cardiology)

IMAGING PERFORMED BY

Kathleen Byrnes

HOSPITAL NAME

Scotts Creek Animal
 Hospital

REFERRING VET

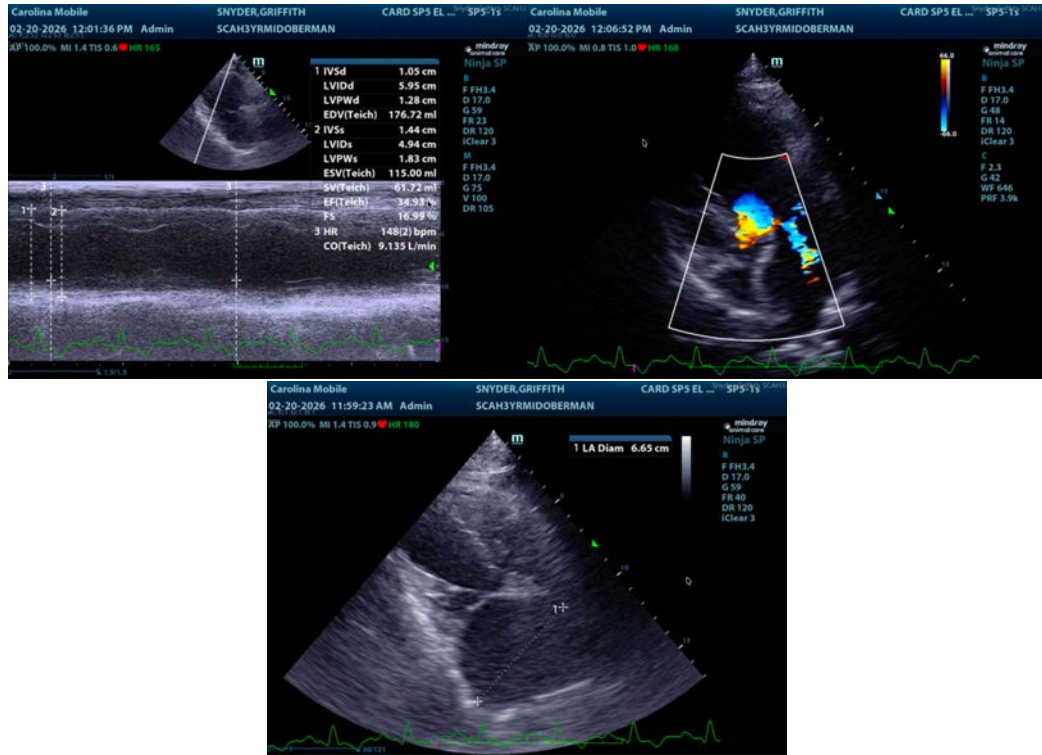
Dr. Cartner

INVOICE

73150

DATE

2/20/26



The information and recommendations provided are based on the images presented by the referring veterinarian/sonographer. No evaluation can be communicated regarding pathology that was not visible in the image/video clips provided.

Thank you for this referral. If the clinical or image interpretation does not parallel your findings or if I can be of any further assistance please contact me.

Brad Harris, DVM, DACVECC, DACVIM (cardiology)

info@SonoPath.com