



PATIENT

Pretzel Kim

SPECIES

Canine

BREED

Yorkshire Terrier

SEX

Neutered Male

AGE

11 Years 8 Months

WEIGHT

9.7 pounds

INTERPRETED BY

Bradley Harris, DVM,
DACVECC, DACVIM
(cardiology)

IMAGING PERFORMED BY

Dr. Graham Sager-Gellerman DVM

HOSPITAL NAME

Back Bay Veterinary
Clinic

REFERRING VET

Dr. Eva Gurian DVM

INVOICE

13750

DATE

02/13/26

PRESENTING CLINICAL SIGNS

- To evaluate the following condition: MMVD Stg B1
- 11yo MN Yorkie with known MMVD stage B1 diagnosed in October 2024. Grade III/VI heart murmur on PE. Asymptomatic. Pursuing routine echo recheck.

Abnormal PE/Chem/CBC/UA Results: Jan 2026 Chem, CBC, UA, T4, 4DX, fecal— all WNL

ULTRASONOGRAPHIC EXAMINATION OF THE HEART

CANINE CARDIAC PARAMETERS	BW	HR BPM	LAD 4 ch Long	RAD 4 ch Long	La/Ao Heart Base	LVIDd	LVIDs
NORMAL PARAMETER		50-100			<1.6		
PATIENT	4.4	NM	2.5	NM	1.38	2.51	1.39
CANINE CARDIAC PARAMETERS	FS	EPSS	PV V MAX (m/s)	AV V Max (m/sec)	MR Vmax	TR Vmax	RPA distensibility (normal >30%)
NORMAL PARAMETER	28-40	<0.6	0.7-1.6	0.7-1.7	4.5-5.5	< 2.7	
PATIENT	45	0.2	0.9	1.1	5.7	NM	NM

Cardiac Presentation

The left atrium is normal in dimension. The left ventricle is normal in dimension, with normal systolic function. The right atrium and ventricle are normal in dimension, with normal systolic function. The anterior and posterior mitral valve leaflets are thickened and redundant consistent with myxomatous changes, and there is mild prolapse. There is mild to moderate mitral regurgitation identified. The tricuspid valve leaflets are appropriately thin with adequate apposition, intact chordae, no significant tricuspid regurgitation and no evidence of pulmonary hypertension. The left ventricular outflow tract demonstrated normal laminar flow and the visible aorta is unremarkable. The right ventricular outflow tract assessment revealed normal laminar flow, and appropriate diameter and distensibility. There is no pulmonic and no aortic valve insufficiency identified. There is no visible pericardial, pleural, or free peritoneal fluid documented. No evidence of hepatic venous congestion is noted. The cardiac chambers, pericardial and visible extra-cardiac regions were free of masses, spontaneous echo contrast, or thrombi.

ULTRASONOGRAPHIC FINDINGS



PATIENT

Pretzel Kim

SPECIES

Canine

BREED

Yorkshire Terrier

SEX

Neutered Male

AGE

11 Years 8 Months

WEIGHT

9.7 pounds

INTERPRETED BY

Bradley Harris, DVM,
DACVECC, DACVIM
(cardiology)

IMAGING PERFORMED BY

Dr. Graham Sager-Gellerman DVM

HOSPITAL NAME

Back Bay Veterinary Clinic

REFERRING VET

Dr. Eva Gurian DVM

INVOICE

13750

DATE

02/13/26

- These findings are consistent with degenerative/myxomatous mitral valve disease with minimal to mild hemodynamic effects consistent with ACVIM Stage B1 disease. It is unlikely that any current morbidity is of cardiac origin.

INTERPRETATION OF THE FINDINGS & FURTHER RECOMMENDATIONS

Given these findings, no cardiac therapy is recommended. There are no cardiac contraindications to anesthesia, fluid therapy, vasopressor therapy, or corticosteroids as indicated for further assessment and treatment. If not already performed, baseline thoracic radiographs and blood pressure are recommended. A recheck echocardiogram is recommended in 6 months.

Anesthesia considerations:

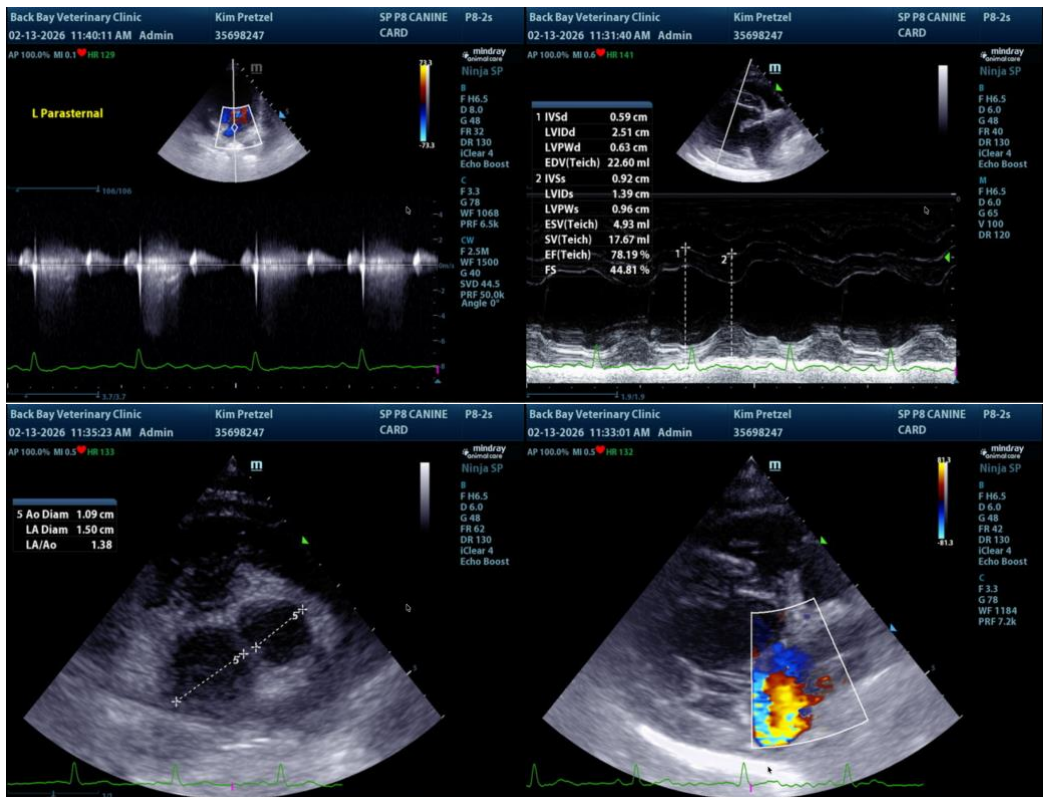
If anesthesia is necessary, alpha-2 agonists, ketamine, high dose acepromazine, and Telazol should be avoided. Fluid therapy during anesthesia should be considered at a conservative rate (e.g., 5 ml/kg/hour) if possible.

Diet:

A high-quality food from Hills, Royal Canin, Science Diet, Eukanuba, Iams, or Purina that is highly palatable with adequate protein and calories for maintaining optimal body condition is reasonable.

Activity:

No special considerations are necessary.





PATIENT

Pretzel Kim

SPECIES

Canine

BREED

Yorkshire Terrier

SEX

Neutered Male

AGE

11 Years 8 Months

WEIGHT

9.7 pounds

INTERPRETED BY

Bradley Harris, DVM,
DACVECC, DACVIM
(cardiology)

IMAGING PERFORMED BY

Dr. Graham Sager-
Gellerman DVM

HOSPITAL NAME

Back Bay Veterinary
Clinic

REFERRING VET

Dr. Eva Gurian DVM

INVOICE

13750

DATE

02/13/26

The information and recommendations provided are based on the images presented by the referring veterinarian/sonographer. No evaluation can be communicated regarding pathology that was not visible in the image/video clips provided.

Thank you for this referral. If the clinical or image interpretation does not parallel your findings or if I can be of any further assistance please contact me.

Bradley Harris, DVM, DACVECC, DACVIM (cardiology)

info@SonoPath.com