



PATIENT

Daisy Duncan

SPECIES

Canine

BREED

Beagle

SEX

SF

AGE

10 years

WEIGHT

27.4 lbs

INTERPRETED BY

Bradley Harris, DVM,
DACVECC, DACVIM
(cardiology)

IMAGING PERFORMED BY

Dr. Christopher
Roberts

HOSPITAL NAME

Kentown Animal
Hospital

REFERRING VET

Dr. Christopher
Roberts

INVOICE

11315

DATE

2/13/2026

PRESENTING CLINICAL SIGNS

- Recent heart murmur noted.
- Grade 2/6 systolic murmur.
- Hx of dental disease and eyelid tumors.
- No coughing or trouble breathing.

Abnormal PE/Chem/CBC/UA Results: H/L- grade 2/6 left apical systolic murmur no arrhythmia dental disease eyelid tumors BUN- 46 ALP- 394 USG- 1.016, protein 2+

ULTRASONOGRAPHIC EXAMINATION OF THE HEART

CANINE CARDIAC PARAMETERS	BW	HR BPM	LAD 4 ch Long	RAD 4 ch Long	La/Ao Heart Base	LVIDd	LVIDs
NORMAL PARAMETER		50-100			<1.6		
PATIENT	12.45 kg	NM	3.64	2.51	1.33	3.93	2.48
CANINE CARDIAC PARAMETERS	FS	EPSS	PV V MAX (m/s)	AV V Max (m/sec)	MR Vmax	TR Vmax	RPA distensibility (normal >30%)
NORMAL PARAMETER	28-40	<0.6	0.7-1.6	0.7-1.7	4.5-5.5	< 2.7	
PATIENT	37	0.4	1.0	1.4	NM	NM	NM

Cardiac Presentation

The left atrium is upper limits of normal in dimension. The left ventricle is mildly enlarged, with normal systolic function. The right atrium and ventricle are normal in dimension, with normal systolic function. The anterior and posterior mitral valve leaflets are thickened and redundant consistent with myxomatous changes, and there is no significant prolapse. There is trivial mitral regurgitation identified. The tricuspid valve leaflets are appropriately thin with adequate apposition, intact chordae, no significant tricuspid regurgitation and no evidence of pulmonary hypertension. The left ventricular outflow tract demonstrated normal laminar flow and the visible aorta is unremarkable. The right ventricular outflow tract assessment revealed normal laminar flow, and appropriate diameter and distensibility. There is no pulmonic and no aortic valve insufficiency identified. There is no visible pericardial, pleural, or free peritoneal fluid documented. No evidence of hepatic venous congestion is noted. The cardiac chambers, pericardial and visible extra-cardiac regions were free of masses, spontaneous echo contrast, or thrombi.

ULTRASONOGRAPHIC FINDINGS

- These findings are consistent with degenerative/myxomatous mitral valve disease with minimal to mild hemodynamic effects consistent with ACVIM Stage B1 disease. It is unlikely that any current morbidity is of cardiac origin.



PATIENT

Daisy Duncan

SPECIES

Canine

BREED

Beagle

SEX

SF

AGE

10 years

WEIGHT

27.4 lbs

INTERPRETED BY

Bradley Harris, DVM,
DACVECC, DACVIM
(cardiology)

IMAGING PERFORMED BY

Dr. Christopher
Roberts

HOSPITAL NAME

Kentown Animal
Hospital

REFERRING VET

Dr. Christopher
Roberts

INVOICE

11315

DATE

2/13/2026

INTERPRETATION OF THE FINDINGS & FURTHER RECOMMENDATIONS

Given these findings, no cardiac therapy is recommended. There are no cardiac contraindications to anesthesia, fluid therapy, vasopressor therapy, or corticosteroids as indicated for further assessment and treatment. If not already performed, baseline thoracic radiographs and blood pressure are recommended. A recheck echocardiogram is recommended in 6 months.

Anesthesia considerations:

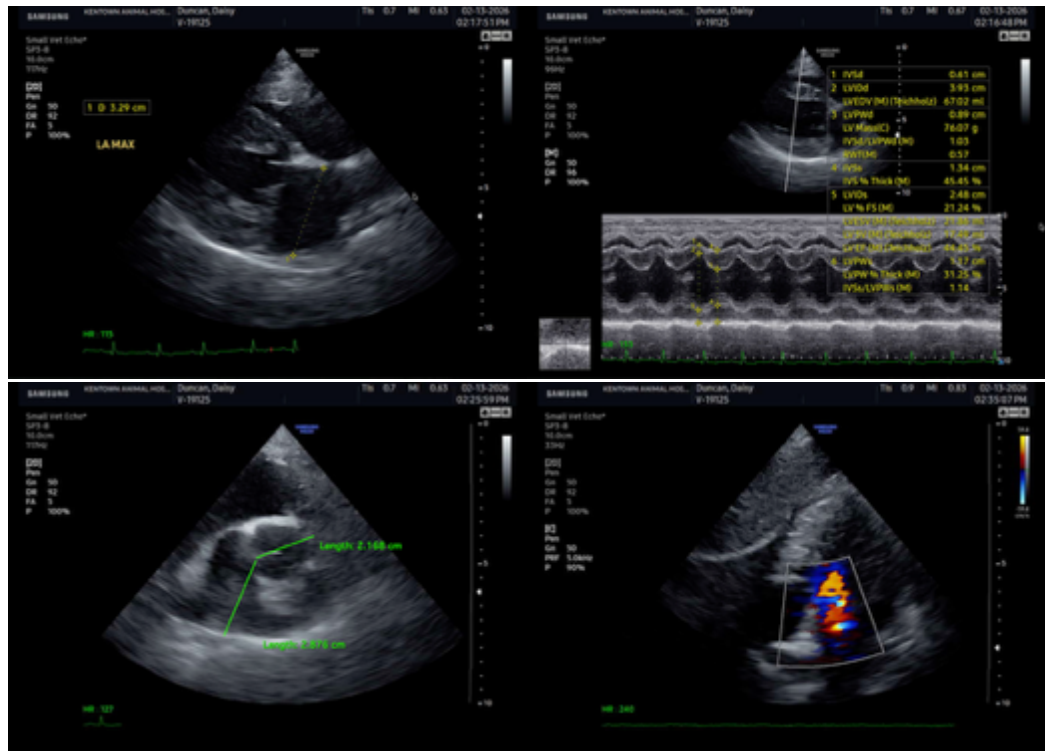
If anesthesia is necessary, alpha-2 agonists, ketamine, high dose acepromazine, and Telazol should be avoided. Fluid therapy during anesthesia should be considered at a conservative rate (e.g., 5 ml/kg/hour) if possible.

Diet:

A high-quality food from Hills, Royal Canin, Science Diet, Eukanuba, Iams, or Purina that is highly palatable with adequate protein and calories for maintaining optimal body condition is reasonable.

Activity:

No special considerations are necessary.



The information and recommendations provided are based on the images presented by the referring veterinarian/sonographer. No evaluation can be communicated regarding pathology that was not visible in the image/video clips provided.

Thank you for this referral. If the clinical or image interpretation does not parallel your findings or if I can be of any further assistance please contact me.



PATIENT

Bradley Harris, DVM, DACVECC, DACVIM (cardiology)

Daisy Duncan

info@SonoPath.com

SPECIES

Canine

BREED

Beagle

SEX

SF

AGE

10 years

WEIGHT

27.4 lbs

INTERPRETED BY

Bradley Harris, DVM,
DACVECC, DACVIM
(cardiology)

IMAGING PERFORMED BY

Dr. Christopher
Roberts

HOSPITAL NAME

Kentown Animal
Hospital

REFERRING VET

Dr. Christopher
Roberts

INVOICE

11315

DATE

2/13/2026