



**PATIENT**

Barron Novak

**SPECIES**

Canine

**BREED**

Pitbull Mix

**SEX**

Neutered Male

**AGE**

9 Years

**WEIGHT**

67.4 pounds

**INTERPRETED BY**

Bradley Harris, DVM,  
DACVECC, DACVIM  
(cardiology)

**IMAGING PERFORMED BY**

Dr. Christopher  
Roberts

**HOSPITAL NAME**

Kentown Animal  
Hospital

**REFERRING VET**

Dr. Christopher  
Roberts

**INVOICE**

13751

**DATE**

02/13/26

**PRESENTING CLINICAL SIGNS**

- repeat echo performed under sedation 11/2025- revealed myocardial dysfunction and concern for DCM
- repeated echo today- P sedated with gabapentin 900 mg and 200 mg of trazodone

Abnormal PE/Chem/CBC/UA Results: BAR, H/L- WNL, no arrhythmias BP- 140 mmHg BW pending but previous BW had slight elevation of ALP- 249 UA- 1+ protein, USG- 1.044

**ULTRASONOGRAPHIC EXAMINATION OF THE HEART**

CANINE CARDIAC PARAMETERS	BW	HR BPM	LAD 4 ch Long	RAD 4 ch Long	La/Ao Heart Base	LVIDd	LVIDs
NORMAL PARAMETER		50-100			<1.6		
PATIENT	30.64	120	3.44	2.59	1.03	2.94	2.07
30	FS	EPSS	PV V MAX (m/s)	AV V Max (m/sec)	MR Vmax	TR Vmax	RPA distensibility (normal >30%)
NORMAL PARAMETER	28-40	<0.6	0.7-1.6	0.7-1.7	4.5-5.5	< 2.7	
PATIENT	30	NM	0.8	1.8	--	--	NM

**Cardiac Presentation**

The left atrium is normal in dimension. The left ventricle is normal in dimension, with normal systolic function. The right atrium and ventricle are normal in dimension, with normal systolic function. The anterior and posterior mitral valve leaflets are appropriately thin with adequate apposition, intact chordae, and there is no significant prolapse. There is no significant mitral regurgitation identified. The tricuspid valve leaflets are appropriately thin with adequate apposition, intact chordae, no significant tricuspid regurgitation and no evidence of pulmonary hypertension. The left ventricular outflow tract demonstrated normal laminar flow and the visible aorta is unremarkable. The right ventricular outflow tract assessment revealed normal laminar flow, and appropriate diameter and distensibility. There is no pulmonic and no aortic valve insufficiency identified. There is no visible pericardial, pleural, or free peritoneal fluid documented. No evidence of hepatic venous congestion is noted. The cardiac chambers, pericardial and visible extra-cardiac regions were free of masses, spontaneous echo contrast, or thrombi.

**ULTRASONOGRAPHIC FINDINGS**



## PATIENT

Barron Novak

## SPECIES

Canine

## BREED

Pitbull Mix

## SEX

Neutered Male

## AGE

9 Years

## WEIGHT

67.4 pounds

## INTERPRETED BY

Bradley Harris, DVM,  
DACVECC, DACVIM  
(cardiology)

## IMAGING PERFORMED BY

Dr. Christopher  
Roberts

## HOSPITAL NAME

Kentown Animal  
Hospital

## REFERRING VET

Dr. Christopher  
Roberts

## INVOICE

13751

## DATE

02/13/26

- These findings are consistent with an essentially normal echocardiogram. Any murmur will be considered functional in origin. No cardiac cause of the morbidity is identified.

## INTERPRETATION OF THE FINDINGS & FURTHER RECOMMENDATIONS

Given these findings, no cardiac therapy is recommended. There are no cardiac contraindications to fluid therapy or corticosteroid therapy, as indicated for further assessment and treatment. No specific cardiac recheck is recommended unless a murmur or clinical signs of heart disease develop.

Anesthesia considerations:

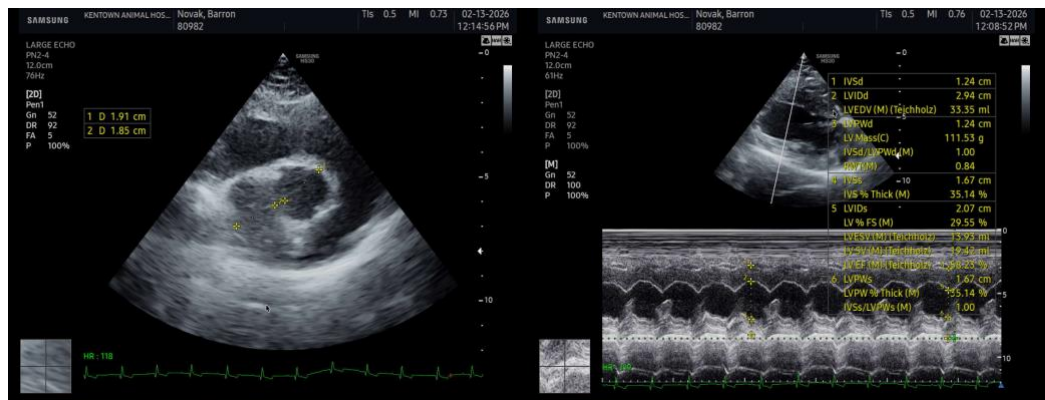
No special considerations are necessary.

Diet:

No special considerations are necessary. Any high-quality food from Hills, Royal Canin, Science Diet, Eukanuba, Iams, or Purina is reasonable.

Activity:

No special considerations are necessary.



The information and recommendations provided are based on the images presented by the referring veterinarian/sonographer. No evaluation can be communicated regarding pathology that was not visible in the image/video clips provided.

Thank you for this referral. If the clinical or image interpretation does not parallel your findings or if I can be of any further assistance please contact me.

**Bradley Harris, DVM, DACVECC, DACVIM (cardiology)**

[info@SonoPath.com](mailto:info@SonoPath.com)