

PATIENT

Margo Burch

SPECIES

Canine

BREED

Pitbull Mix

SEX

FS

AGE

11yr

WEIGHT

58lb

INTERPRETED BY

Brad Harris, DVM,
DACVECC, Residency
trained in cardiology

IMAGING PERFORMED BY

Karen Ebersole

HOSPITAL NAME

Scanvet

REFERRING VET

Dr Ouellette

INVOICE

23129

DATE

12/5/2025

PRESENTING CLINICAL SIGNS

Preanesthetic echo for MCT removal. Pre-operative ECG revealed ventricular premature contractions (VPCs), prompting a recommendation for a cardiac ultrasound. Hypothyroid, on medication.

Abnormal PE/Chem/CBC/UA Results: PE: Grade 1/6 systolic murmur, first noted in 2022 Most recent BW - NSF. Cardiopet - VPC noted.

ULTRASONOGRAPHIC EXAMINATION OF THE HEART

CANINE	BW	HR BPM	LAD 4 ch Long	RAD 4 ch Long	La/Ao Heart Base	LVIDd	LVIDs
CARDIAC PARAMETERS							
NORMAL PARAMETER		50-100			<1.6		
PATIENT	26.36	--	4.20	2.78	1.13	4.45	3.01
CANINE	FS	EPSS	PV V MAX (m/s)	AV V Max (m/sec)	MR Vmax	TR Vmax	RPA distensibility (normal >30%)
CARDIAC PARAMETERS							
NORMAL PARAMETER	28-40	<0.6	0.7-1.6	0.7-1.7	4.5-5.5	< 2.7	
PATIENT	32	0.4	0.9	1.8	--	--	32

Cardiac Presentation

The left atrium is normal in dimension. The left ventricle is upper limits of normal in dimension, with normal systolic function. The right atrium and ventricle are subjectively normal in dimension and systolic function. The mitral valve is thickened and redundant consistent with myxomatous changes, and there is no significant prolapse. There is evidence of mild mitral regurgitation. The tricuspid valve leaflets are subjectively normal with no tricuspid regurgitation and no evidence of pulmonary hypertension. The left ventricular outflow tract demonstrated normal laminar flow and the visible aorta is unremarkable. The right ventricular outflow tract assessment revealed normal laminar flow, and appropriate diameter and distensibility. There is no evidence of semilunar valve insufficiency. There is no visible pericardial, pleural, or free peritoneal fluid noted. The cardiac chambers, pericardial and visible extra-cardiac regions were free of masses, spontaneous echo contrast, or thrombi.

ULTRASONOGRAPHIC FINDINGS

- These findings are consistent with degenerative/myxomatous mitral valve disease with minimal to mild hemodynamic effects consistent with ACVIM Stage B1 disease. It is unlikely that any current morbidity is of cardiac origin.

INTERPRETATION OF THE FINDINGS & FURTHER RECOMMENDATIONS

Recommendations:

Given these findings, no cardiac therapy is recommended. There are no cardiac contraindications to



PATIENT

Margo Burch

anesthesia, fluid therapy, vasopressor therapy, or corticosteroids as indicated for further assessment and treatment. If not already performed, baseline thoracic radiographs and blood pressure are recommended. A recheck echocardiogram is recommended in 6 months.

SPECIES

Canine

Anesthesia considerations:

If anesthesia is necessary, alpha-2 agonists, ketamine, high dose acepromazine, and Telazol should be avoided. Fluid therapy during anesthesia should be considered at a conservative rate (e.g., 5 ml/kg/hour) if possible.

BREED

Pitbull Mix

Diet:

A high-quality food from Hills, Royal Canin, Science Diet, Eukanuba, Iams, or Purina that is highly palatable with adequate protein and calories for maintaining optimal body condition is reasonable.

SEX

FS

Activity:

No special considerations are necessary.

AGE

11yr

WEIGHT

58lb

INTERPRETED BY

Brad Harris, DVM, DACVECC, Residency trained in cardiology

IMAGING PERFORMED BY

Karen Ebersole

HOSPITAL NAME

Scanvet

REFERRING VET

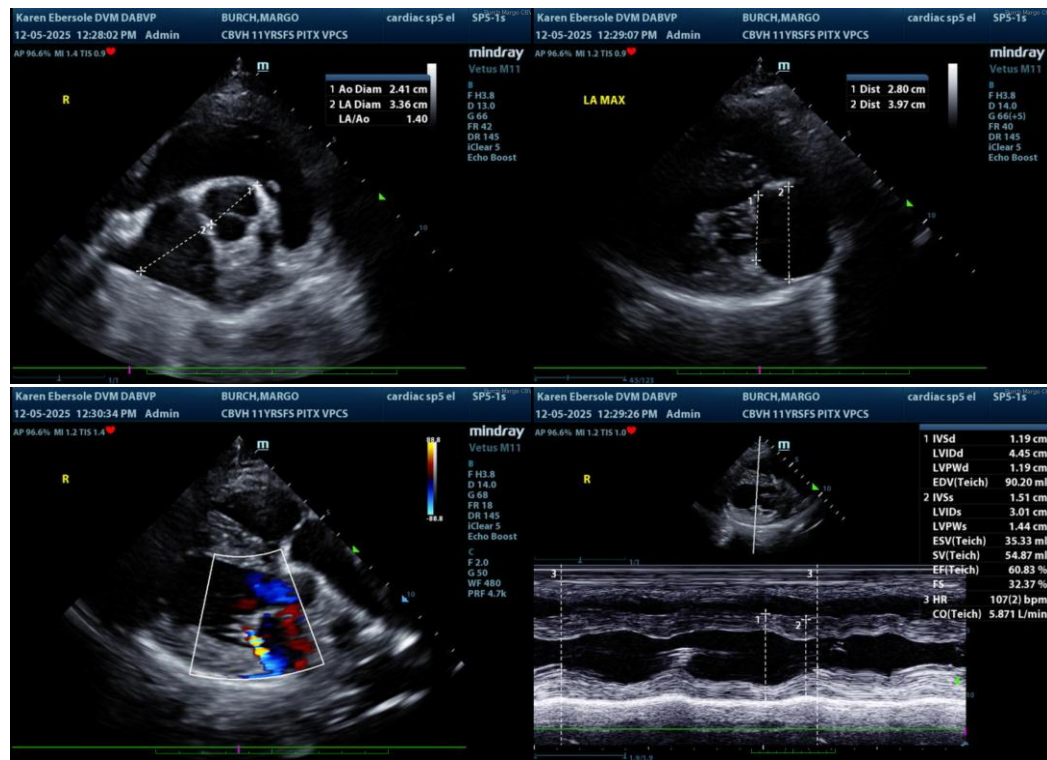
Dr Ouellette

INVOICE

23129

DATE

12/5/2025



The information and recommendations provided are based on the images presented by the referring veterinarian/sonographer. No evaluation can be communicated regarding pathology that was not visible in the image/video clips provided.

Thank you for this referral. If the clinical or image interpretation does not parallel your findings or if I can be of any further assistance please contact me.

Bradley Harris, DVM, DACVECC, DACVIM (cardiology)



PATIENT

info@SonoPath.com

Margo Burch

SPECIES

Canine

BREED

Pitbull Mix

SEX

FS

AGE

11yr

WEIGHT

58lb

INTERPRETED BY

Brad Harris, DVM,
DACVECC, Residency
trained in cardiology

**IMAGING
PERFORMED BY**

Karen Ebersole

HOSPITAL NAME

Scanvet

REFERRING VET

Dr Ouellette

INVOICE

23129

DATE

12/5/2025