



**PATIENT PRESENTING CLINICAL SIGNS**

Jack Hoepfel Grade 2/6 hm, periodontal dz, pre- anesthetic. Otitis externa, mass removal surgery and dental workup.

**SPECIES**

Canine

Abnormal PE/Chem/CBC/UA Results: TP-7.6 Glob-2.4 ALKP-679 Amyl-1473 PSL-531 WBC-17.7 PLT-714 Neut-11328 Lymph-4956 Mono-1239 T4-<0.5 UA-prot- 1+ UPC-0.7 USG-1.017.

**BREED**

English Cocker Spaniel

**ULTRASONOGRAPHIC EXAMINATION OF THE HEART**

**SEX**

Neutered Male

**AGE**

13 years 2 months

**WEIGHT**

42.3 lbs

CANINE CARDIAC PARAMETERS	BW	HR BPM	LAD 4 ch Long	RAD 4 ch Long	La/Ao Heart Base	LVIDd	LVIDs
NORMAL PARAMETER		50-100			<1.6		
PATIENT	19.23 kg	90	3.1	2.67	1.39	2.97	2.27
CANINE CARDIAC PARAMETERS	FS	EPSS	PV V MAX (m/s)	AV V Max (m/sec)	MR Vmax	TR Vmax	RPA distensibility (normal >30%)
NORMAL PARAMETER	28-40	<0.6	0.7-1.6	0.7-1.7	4.5-5.5	< 2.7	
PATIENT	24	0.2	1.3	1.0	NM	NM	38%

**INTERPRETED BY**

Bradley Harris, DVM, DACVECC, DACVIM (cardiology)

**Cardiac Presentation**

The left atrium is normal in dimension. The left ventricle is normal in dimension, with normal systolic function. The right atrium and ventricle are subjectively normal in dimension and systolic function. The mitral valve is thickened and redundant consistent with myxomatous changes, and there is no significant prolapse. There is evidence of mild mitral regurgitation. The tricuspid valve leaflets are subjectively normal with no tricuspid regurgitation and no evidence of pulmonary hypertension. The left ventricular outflow tract demonstrated normal laminar flow, and the visible aorta is unremarkable. The right ventricular outflow tract assessment revealed normal laminar flow, and appropriate diameter and distensibility. There is no evidence of semilunar valve insufficiency. There is no visible pericardial, pleural, or free peritoneal fluid noted. The cardiac chambers, pericardial and visible extra-cardiac regions were free of masses, spontaneous echo contrast, or thrombi.

**IMAGING PERFORMED BY**

Kerri Becker

**HOSPITAL NAME**

St. George VH

**REFERRING VET**

Dr. Patel

**ULTRASONOGRAPHIC FINDINGS**

**INVOICE**

10864

**DATE**

12/4/2025

- These findings are consistent with degenerative/myxomatous mitral valve disease with minimal to mild hemodynamic effects consistent with ACVIM Stage B1 disease. It is unlikely that any current morbidity is of cardiac origin.

**INTERPRETATION OF THE FINDINGS & FURTHER RECOMMENDATIONS**

Given these findings, no cardiac therapy is recommended. There are no cardiac contraindications to anesthesia, fluid therapy, vasopressor therapy, or corticosteroids as indicated for further assessment



**PATIENT**

Jack Hoepfel

**SPECIES**

Canine

**BREED**

English Cocker Spaniel

**SEX**

Neutered Male

**AGE**

13 years 2 months

**WEIGHT**

42.3 lbs

**INTERPRETED BY**

Bradley Harris, DVM,  
DACVECC, DACVIM  
(cardiology)

**IMAGING PERFORMED BY**

Kerri Becker

**HOSPITAL NAME**

St. George VH

**REFERRING VET**

Dr. Patel

**INVOICE**

10864

**DATE**

12/4/2025

and treatment. If not already performed, baseline thoracic radiographs and blood pressure are recommended. A recheck echocardiogram is recommended in 6 months.

**Anesthesia considerations:**

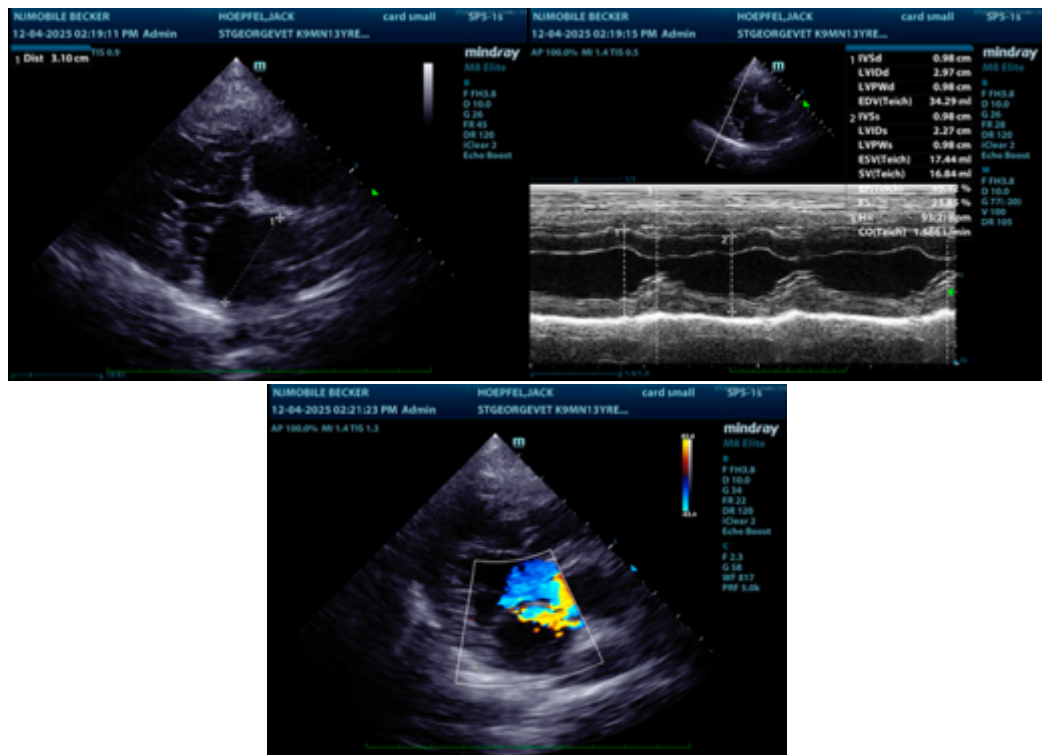
If anesthesia is necessary, alpha-2 agonists, ketamine, high dose acepromazine, and Telazol should be avoided. Fluid therapy during anesthesia should be considered at a conservative rate (e.g., 5 ml/kg/hour) if possible.

**Diet:**

A high-quality food from Hills, Royal Canin, Science Diet, Eukanuba, Iams, or Purina that is highly palatable with adequate protein and calories for maintaining optimal body condition is reasonable.

**Activity:**

No special considerations are necessary.



The information and recommendations provided are based on the images presented by the referring veterinarian/sonographer. No evaluation can be communicated regarding pathology that was not visible in the image/video clips provided.

Thank you for this referral. If the clinical or image interpretation does not parallel your findings or if I can be of any further assistance please contact me.

**Bradley Harris, DVM, DACVECC, DACVIM (cardiology)**

[info@SonoPath.com](mailto:info@SonoPath.com)