

PATIENT

Gandolf Franklin

SPECIES

Canine

BREED

Poodle Mix

SEX

MN

AGE

15 years

WEIGHT

18 lbs

INTERPRETED BY

Bradley Harris, DVM,
DACVECC, DACVIM
(cardiology)

IMAGING PERFORMED BY

Loetitia Saint-Jacques,
LVT

HOSPITAL NAME

VCA Baring Blvd Vet

REFERRING VET

Dr. Jackie Pulver

INVOICE

11007

DATE

12/23/2025

PRESENTING CLINICAL SIGNS

wly noted heart murmur, dog is having increased abdominal respiratory effort and weakness. 4/6 heart murmur. Working diagnosis rule out pulmonary hypertension Blood pressure- 130, 130 Medication pimobendan 2.5mg bid, started 12/22/2025.

Abnormal PE/Chem/CBC/UA Results: Bun 40.8 (9-29) Phos 5.7 (1.9-5) Alt-125 (0-120) Lipase 241 (0-225) Na-155 (141-152) Heartworm test negative ECG results (if done previously): The ECG shows a sinus rhythm with left axis deviation of the QRS complex. Right deviation of the MEA of the QRS complex could be due to right ventricle enlargement, intraventricular conduction disturbance, or individual thorax conformation/intra-thoracic conformational changes. Radiographic Abnormalities: THORACIC RADIOGRAPHIC CONCLUSIONS: Mild cardiomegaly, suspect right sided. Concern for pulmonary hypertension Assessment: 1. Dyspnea, based on the provided xrays pulmonary hypertension would be the top differential although echocardiogram required to confirm.

ULTRASONOGRAPHIC EXAMINATION OF THE HEART

CANINE CARDIAC PARAMETERS	BW	HR BPM	LAD 4 ch Long	RAD 4 ch Long	La/Ao Heart Base	LVIDd	LVIDs
NORMAL PARAMETER		50-100			<1.6		
PATIENT	8.18 kg	NM	2.14	2.94	1.12	1.66	0.80
CANINE CARDIAC PARAMETERS	FS	EPSS	PV V MAX (m/s)	AV V Max (m/sec)	MR Vmax	TR Vmax	RPA distensibility (normal >30%)
NORMAL PARAMETER	28-40	<0.6	0.7-1.6	0.7-1.7	4.5-5.5	< 2.7	
PATIENT	52	0.1	NM	1.1	NM	5.7	11%

Cardiac Presentation

The left atrium is normal in dimension. The left ventricle is normal in dimension, with normal systolic function. The right atrium and ventricle are subjectively normal in dimension and systolic function. The mitral valve is thickened and redundant consistent with myxomatous changes, and there is no significant prolapse. There is evidence of trivial mitral regurgitation. The tricuspid valve leaflets are minimally thickened with severe tricuspid regurgitation and evidence of severe pulmonary hypertension. The left ventricular outflow tract demonstrated normal laminar flow and the visible aorta is unremarkable. The right ventricular outflow tract assessment revealed normal laminar flow, with a severely dilated main pulmonary artery diameter and reduced distensibility. There is trace pulmonic valve insufficiency. There is no visible pericardial, pleural, or free peritoneal fluid noted. The cardiac chambers, pericardial and visible extra-cardiac regions were free of masses, spontaneous echo contrast, or thrombi.

**PATIENT**

Gandolf Franklin

SPECIES

Canine

BREED

Poodle Mix

SEX

MN

AGE

15 years

WEIGHT

18 lbs

INTERPRETED BYBradley Harris, DVM,
DACVECC, DACVIM
(cardiology)**IMAGING
PERFORMED BY**Loetitia Saint-Jacques,
LVT**HOSPITAL NAME**

VCA Baring Blvd Vet

REFERRING VET

Dr. Jackie Pulver

INVOICE

11007

DATE

12/23/2025

ULTRASONOGRAPHIC FINDINGS

- These findings identify significant pulmonary hypertension in conjunction with trivial degenerative mitral disease. The lack of chamber enlargement is consistent with ACVIM stage B1, making the PH more likely related to primary respiratory disease or other etiology (non-type 2 PH). Pulmonary hypertension in dogs is most commonly secondary to primary respiratory disease (chronic bronchitis, pulmonary fibrosis, or other forms of pulmonary interstitial disease). Pulmonary hypertension can also develop in dogs with severe heartworm disease or secondary to pulmonary thromboembolism (PTE). Less commonly, pulmonary hypertension is identified in dogs as an idiopathic condition. Pulmonary hypertension commonly causes syncope, and a patient's signs may be attributable to this condition.

INTERPRETATION OF THE FINDINGS & FURTHER RECOMMENDATIONS

Given the degree of right sided cardiac enlargement, cardiac therapy is reasonable at this time. Treatment for the PH/presumed respiratory disease is also warranted, as clinical signs are present. Therapy should include Vetmedin (0.25-0.35 mg/kg BID), sildenafil (2 mg/kg BID), and enalapril (0.5 mg/kg BID assuming normotension and lack of renal insult). Baseline thoracic radiographs, blood pressure and chemistry panel should be performed now, and again in 1-2 weeks. A repeat echocardiogram, thoracic radiographs, blood pressure, and chemistry panel is indicated in another 3-6 months, or sooner if progression is suspected, clinical signs develop/worsen, or additional cardiac therapy is being contemplated.

Anesthesia considerations:

While there is no CHF present, there is likely an increased anesthetic risk which must be considered prior to any anesthetic procedure. If anesthesia is necessary, then alpha-2 agonists, ketamine, high dose acepromazine, and Telazol should be avoided. If an ACE inhibitor (enalapril, benazepril) or spironolactone is being given, it should not be administered on the morning of general anesthesia. Other cardiac medications should be administered per the normal dosing schedule. Fluid therapy during anesthesia should be considered at a reduced rate (e.g., 5 ml/kg/hour) if possible. A shorter anesthetic duration will reduce the risk of complications. Pre-oxygenation is advised. Premedication with an opioid (i.e., butorphanol, hydromorphone, oxymorphone) with or without a benzodiazepine is generally the safest protocol. An induction agent such as Propofol, alfaxalone, or diazepam/etomidate can be used to effect. Maintenance of anesthesia with isoflurane or sevoflurane is reasonable.

Diet:

A high-quality food from Hills, Royal Canin, Science Diet, Eukanuba, Iams, or Purina that is highly palatable with adequate protein and calories for maintaining optimal body condition with mild dietary sodium restriction (<100 mg/100 kcal) is recommended. Consider omega-3 fatty acid supplementation. Ensure the patient is not currently receiving a boutique, exotic, or grain-free diet.

Activity:

Moderate physical activity (meandering walks, exploring the backyard, playing with toys inside, getting excited when family gets home, etc.) is encouraged, but periods of strenuous aerobic activity (jogging, strenuous outdoor ball play, prolonged play at the dog park, etc.) should be avoided, especially during periods of high heat (> 80 F) and humidity. Dogs with heart disease tend to tolerate cool and cold temperatures much better than high temperatures. Avoid sudden increases in activity (e.g. 2 block walks during the week but 2 mile walks followed by 30 minutes at the dog park on the weekends) as this may be difficult for the cardiovascular system to deal with.



PATIENT

Gandolf Franklin

SPECIES

Canine

BREED

Poodle Mix

SEX

MN

AGE

15 years

WEIGHT

18 lbs

INTERPRETED BY

Bradley Harris, DVM,
DACVECC, DACVIM
(cardiology)

IMAGING PERFORMED BY

Loetitia Saint-Jacques,
LVT

HOSPITAL NAME

VCA Baring Blvd Vet

REFERRING VET

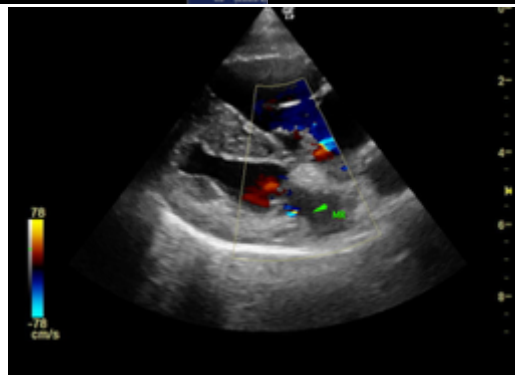
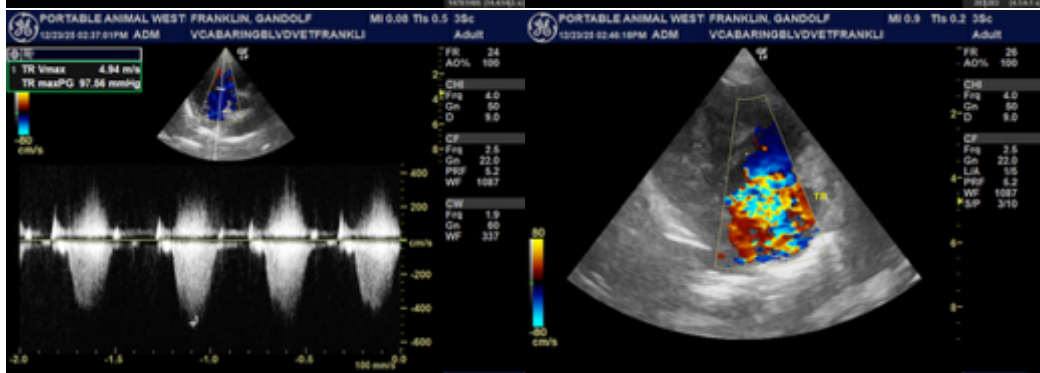
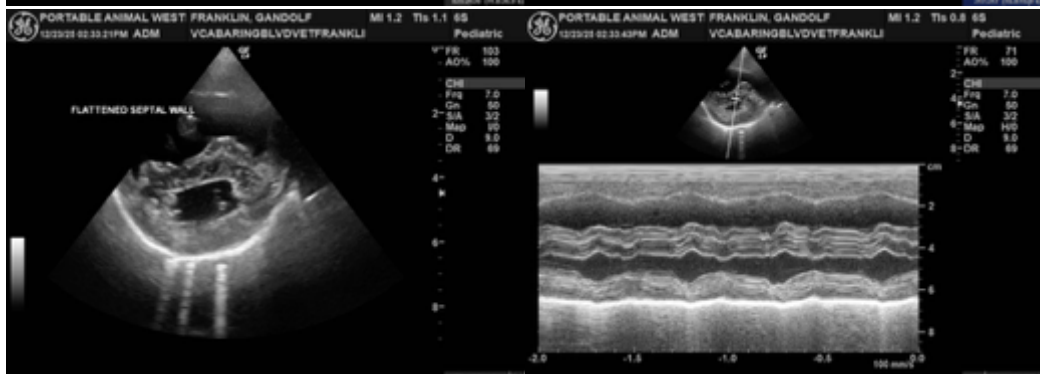
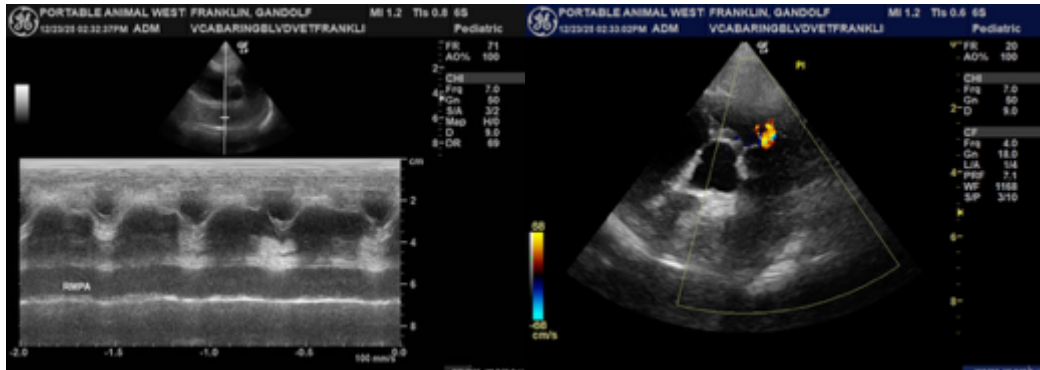
Dr. Jackie Pulver

INVOICE

11007

DATE

12/23/2025

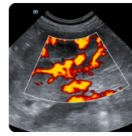
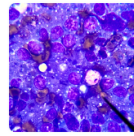
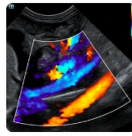
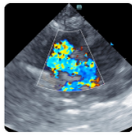


The information and recommendations provided are based on the images presented by the referring veterinarian/sonographer. No evaluation can be communicated regarding pathology that was not

Imaging
performed by



Paw Print Veterinary Services, Inc.
pawsonography@gmail.com
530-786-8340



Clinical Sonography & Telectytoplogy
Educational Teleconsultation Services™

SonoPath

FOSTERING THE ART OF VETERINARY MEDICINE™

SonoPath.com info@sonopath.com 1.800.838.4268

PATIENT

Gandolf Franklin

SPECIES

Canine

BREED

Poodle Mix

SEX

MN

AGE

15 years

WEIGHT

18 lbs

INTERPRETED BY

Bradley Harris, DVM,
DACVECC, DACVIM
(cardiology)

**IMAGING
PERFORMED BY**

Loetitia Saint-Jacques,
LVT

HOSPITAL NAME

VCA Baring Blvd Vet

REFERRING VET

Dr. Jackie Pulver

INVOICE

11007

DATE

12/23/2025

visible in the image/video clips provided.

Thank you for this referral. If the clinical or image interpretation does not parallel your findings or if I can be of any further assistance please contact me.

Bradley Harris, DVM, DACVECC, DACVIM (cardiology)

info@SonoPath.com