



## PATIENT

Pebbles Janosik

## SPECIES

Canine

## BREED

Pomeranian Mix

## SEX

Spayed female

## AGE

10 years

## WEIGHT

24 lbs

## INTERPRETED BY

Bradley Harris, DVM,  
DACVECC, DACVIM  
(cardiology)

## IMAGING PERFORMED BY

Brandon Holmes

## HOSPITAL NAME

West Newton AC

## REFERRING VET

Dr. Holmes

## INVOICE

69476

## DATE

12/10/25

## PRESENTING CLINICAL SIGNS

History: Presented for tooth root abscess on 11/26/2025. Noted new grade 2/6 left sided murmur, so performing echo for pre-anesthetic purposes.

Abnormal PE/Chem/CBC/UA Results: Grade 2/6 left apical murmur. Mildly elevated ALT/ALKP

## ULTRASONOGRAPHIC EXAMINATION OF THE HEART

The left atrium is normal in dimension. The left ventricle is normal in dimension with normal systolic function. The right atrium and ventricle are subjectively normal in dimension and systolic function. The anterior and posterior mitral and tricuspid valve leaflets presented normal linear structure, extension in systole, and union in diastole without regurgitation, prolapse, or myxomatous changes noted. The left ventricular outflow tract demonstrated normal laminar flow and the visible aorta is unremarkable. The right ventricular outflow tract assessment revealed normal laminar flow, and appropriate diameter and distensibility. There is no evidence of semilunar valve insufficiency. There is no visible pericardial, pleural, or free peritoneal fluid noted. The cardiac chambers, pericardial and visible extra-cardiac regions were free of masses, spontaneous echo contrast, or thrombi.

CANINE CARDIAC PARAMETERS	Body Weight kg	HR BPM	LAD 4 ch Long	RAD 4 ch Long	La/Ao Heart Base	LVIDd	LVIDs
NORMAL PARAMETER		50-100			<1.6		
PATIENT	10.91 kg	NM	3.33	1.93	1.17	2.85	2.13
CANINE CARDIAC PARAMETERS	FS	EPSS	PV V MAX (m/s)	AV V Max (m/sec)	MR Vmax	TR Vmax	RPA distensibility (normal >30%)
NORMAL PARAMETER	28-40	<0.6	0.7-1.6	0.7-1.7	4.5-5.5	< 2.7	
PATIENT	25	0.4	0.6	NM	Not present	Not Present	NM

## ULTRASONOGRAPHIC FINDINGS

These findings are consistent with an essentially normal echocardiogram. Any murmur will be considered functional in origin. No cardiac cause of the morbidity is identified.

## INTERPRETATION OF THE FINDINGS & FURTHER RECOMMENDATIONS

Given these findings, no cardiac therapy is recommended. There are no cardiac contraindications to fluid therapy or corticosteroid therapy, as indicated for further assessment and treatment. No specific cardiac recheck is recommended unless a murmur or clinical signs of heart disease develop.

### Anesthesia considerations:

No special considerations are necessary.



## PATIENT

Pebbles Janosik

## SPECIES

Canine

## BREED

Pomeranian Mix

## SEX

Spayed female

## AGE

10 years

## WEIGHT

24 lbs

## INTERPRETED BY

Bradley Harris, DVM,  
DACVECC, DACVIM  
(cardiology)

## IMAGING PERFORMED BY

Brandon Holmes

## HOSPITAL NAME

West Newton AC

## REFERRING VET

Dr. Holmes

## INVOICE

69476

## DATE

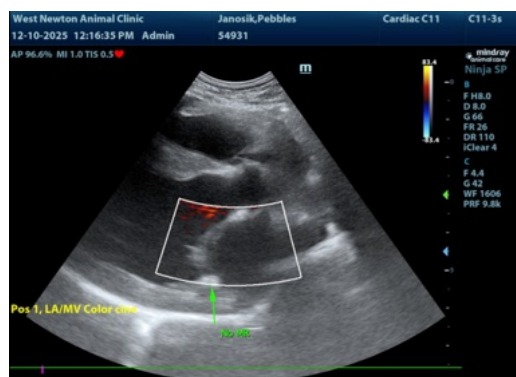
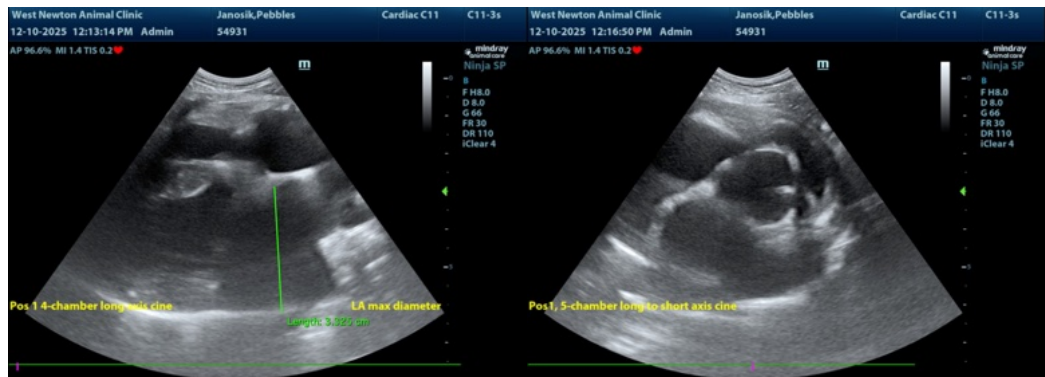
12/10/25

## Diet:

No special considerations are necessary. Any high-quality food from Hills, Royal Canin, Science Diet, Eukanuba, Iams, or Purina is reasonable.

## Activity:

No special considerations are necessary.



The information and recommendations provided are based on the images presented by the referring veterinarian/sonographer. No evaluation can be communicated regarding pathology that was not visible in the image/video clips provided.

Thank you for this referral. If the clinical or image interpretation does not parallel your findings or if I can be of any further assistance please contact me.

Bradley Harris, DVM, DACVECC, DACVIM (cardiology)

[info@SonoPath.com](mailto:info@SonoPath.com)