

**PATIENT**

River Rodriguez

**SPECIES**

Feline

**BREED**

DSH

**SEX**

Spayed Female

**AGE**

5 years 3 months

**WEIGHT**

4.54 kgs

**INTERPRETED BY**

Bradley Harris, DVM,  
DACVECC, DACVIM  
(cardiology)

**IMAGING PERFORMED BY**

Renee Trionfetti, VMD

**HOSPITAL NAME**

Brandywine Valley  
Veterinary Hospital

**REFERRING VET**

Dr. Courtney Mooney

**INVOICE**

10711

**DATE**

11/7/2025

**PRESENTING CLINICAL SIGNS**

Echo following a grade 3/6 parasternal systolic murmur. Diagnosed March 2024 with Hypertrophic Obstructive Cardiomyopathy, Systolic Anterior Motion of the MV, Mild MR. Previous echo with Cardiologist at Pinnacle. HM graded 4/6 at that time. January 2025 showed a mildly elevated proBNP. Meds: Atenolol (25 mg) - 1/4 SID.

Abnormal PE/Chem/CBC/UA Results: Blood Pressure: 183/85, 194/86, 188/95, 193/91, 179/99  
1/17/2025 - ProBNP-FEL 261 H (0-100) - Chem: Alb 3.1-n, normal LES, BUN 22-n, Cr 1.2, SDMA 7-n.  
- Hct 39.5%, Plts 277-n

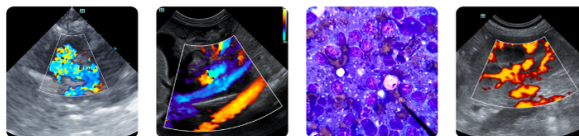
**ULTRASONOGRAPHIC EXAMINATION OF THE ABDOMEN**

FELINE CARDIAC PARAMETERS	BODY WEIGHT (kg)	HR (BPM)	IVSd (cm)	LVIDd (cm)	LVWd (cm)	FS (%)	EF (%)
NORMAL PARAMETER	-----	150-240	0.3-0.6	1.0-2.1	0.25-0.6	35-67	80-100
PATIENT	4.54 kgs	170	0.56	1.4	0.70	49%	84%
FELINE CARDIAC PARAMETERS	LA/AO (M-mode)	LA/AO HEART BASE (Sisson)	LAD LA MAX 4 Chamber		LVOT VEL. (m/s)	RVOT VEL. (m/s)	IVRT (m/)
NORMAL PARAMETER	<1.5	1.6	0.7-1.7		<1.6	<1.3	40-60
PATIENT	NM	1.06	1.34		1.0	0.6	NM
Adapted from June Boon, Veterinary Echocardiography, 1998							
Sisson D et al. JVIM 1991; 5: 232, Jacobs et al. Am J Vet Res 1985; 46:1705							

**Cardiac Presentation**

The left atrium is normal in dimension. There are no distinct left atrial thrombi/clots or spontaneous echo contrast appreciated. The left ventricle is normal in dimension, with concentric hypertrophy, and no evidence of restriction. Left ventricular systolic function is normal, with adequate contractility based on fractional shortening and systolic left ventricular dimensions. The right atrium and ventricle are subjectively normal in dimension and systolic function. There is evidence of systolic anterior motion of the mitral valve with mild to moderate mitral regurgitation. The tricuspid valve leaflets presented normal linear structure, extension in systole, and union in diastole without regurgitation. The left ventricular outflow tract demonstrated turbulent flow and subjective structural valvular integrity. The visible aorta is unremarkable. Pulmonary outflow tract assessment revealed normal valve structure, laminar flow, and appropriate diameter and distensibility. There is no evidence of semilunar valve insufficiency or pulmonary hypertension documented. There is no visible pericardial, pleural, or free peritoneal fluid noted.

**ULTRASONOGRAPHIC FINDINGS**



## PATIENT

River Rodriguez

## SPECIES

Feline

## BREED

DSH

## SEX

Spayed Female

## AGE

5 years 3 months

## WEIGHT

4.54 kgs

## INTERPRETED BY

Bradley Harris, DVM,  
DACVECC, DACVIM  
(cardiology)

## IMAGING PERFORMED BY

Renee Trionfetti, VMD

## HOSPITAL NAME

Brandywine Valley  
Veterinary Hospital

## REFERRING VET

Dr. Courtney Mooney

## INVOICE

10711

## DATE

11/7/2025

- These findings identify left ventricular hypertrophy in the setting of an outflow tract obstruction and absence of any chamber dilation, consistent with occult hypertrophic obstructive cardiomyopathy (HOCM).

## INTERPRETATION OF THE FINDINGS & FURTHER RECOMMENDATIONS

There are multiple layers of uncertainty regarding this case. The presence of hypertrophy and an outflow tract obstruction make the continued use of a beta blocker reasonable. However, the challenge of treating these cats is the lack of any real data to support a meaningful benefit (most of the rationale for their use is theoretical), coupled with the potential for adverse effects (low BP, renal impairment, potential exacerbation of CHF). If atenolol is continued, the dose of 6.25mg once daily (with the potential of increasing to BID given the borderline systemic hypertension). A recheck heart rate, BP, and chemistry would be indicated 1-2 weeks after increasing the dose if this is considered. A repeat echo is warranted in another 6 months, regardless of whether or not therapy is started. Ultimately, a conversation with the owner is necessary to determine what course of therapy is most suitable for them. Regardless, owners should monitor resting respiratory rate at home. Values above 30 breaths/minute or an increase in respiratory rate 10% above baseline should prompt veterinary re-evaluation.

### Anesthesia considerations:

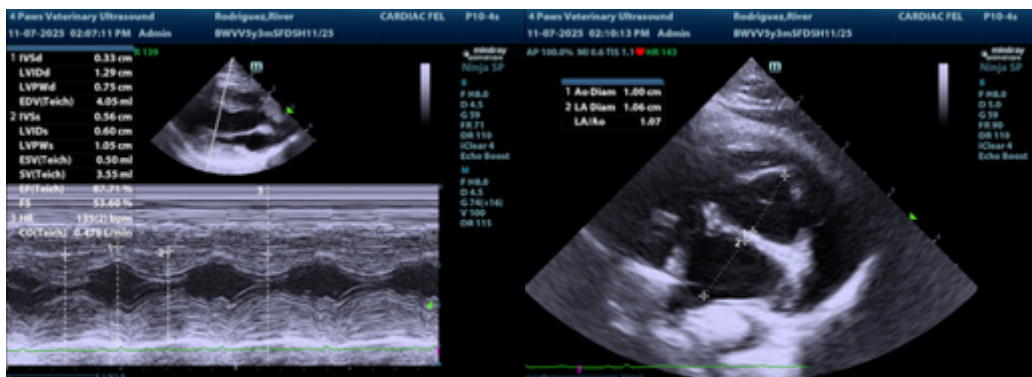
If anesthesia is necessary, then alpha-2 agonists, ketamine, high dose acepromazine, and Telazol should be avoided. If a beta-blocker (atenolol) is being given, it should not be administered on the morning of general anesthesia. Other cardiac medications should be administered per the normal dosing schedule. Fluid therapy during anesthesia should be considered at a conservative rate (e.g., 5 ml/kg/hour) if possible (i.e., if not hypotensive). A shorter anesthetic duration will reduce the risk of complications. Pre-oxygenation is advised. Premedication with an opioid (i.e., butorphanol, hydromorphone, oxymorphone) with or without a benzodiazepine is generally the safest protocol. An induction agent such as Propofol or alfaxalone can be used to effect. Maintenance of anesthesia with isoflurane or sevoflurane is reasonable.

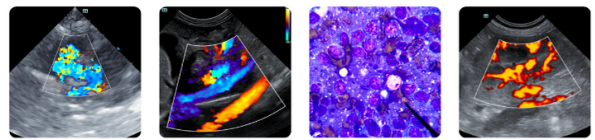
### Diet:

No special considerations are necessary. Any high-quality food from Hills, Royal Canin, Science Diet, Eukanuba, Iams, or Purina is reasonable.

### Activity:

Avoid overly strenuous activity.





## PATIENT

River Rodriguez

## SPECIES

Feline

## BREED

DSH

## SEX

Spayed Female

## AGE

5 years 3 months

## WEIGHT

4.54 kgs

## INTERPRETED BY

Bradley Harris, DVM,  
DACVECC, DACVIM  
(cardiology)

## IMAGING PERFORMED BY

Renee Trionfetti, VMD

## HOSPITAL NAME

Brandywine Valley  
Veterinary Hospital

## REFERRING VET

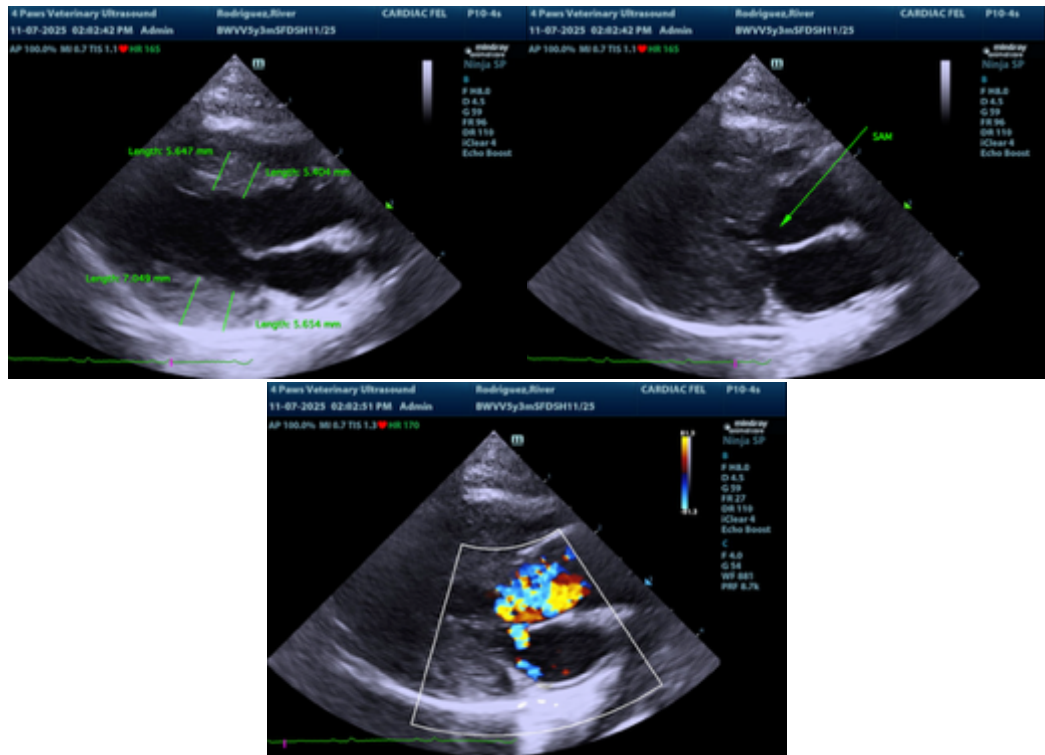
Dr. Courtney Mooney

## INVOICE

10711

## DATE

11/7/2025



The information and recommendations provided are based on the images presented by the referring veterinarian/sonographer. No evaluation can be communicated regarding pathology that was not visible in the image/video clips provided.

Thank you for this referral. If the clinical or image interpretation does not parallel your findings or if I can be of any further assistance please contact me.

Bradley Harris, DVM, DACVECC, DACVIM (cardiology)

[info@SonoPath.com](mailto:info@SonoPath.com)