

**PATIENT**

Frank Hudson

**SPECIES**

Feline

**BREED**

DSH

**SEX**

Neutered Male

**AGE**

7 years 4 months

**WEIGHT**

9.4 lbs

**INTERPRETED BY**

Bradley Harris, DVM,  
DACVECC, DACVIM  
(cardiology)

**IMAGING PERFORMED BY**

Kerri Becker

**HOSPITAL NAME**

Englewood VC

**REFERRING VET**

Dr. Ezik

**INVOICE**

10704

**DATE**

11/7/2025

**PRESENTING CLINICAL SIGNS**

Follow up echo.

Abnormal PE/Chem/CBC/UA Results: Normal.

**ULTRASONOGRAPHIC EXAMINATION OF THE HEART**

FELINE CARDIAC PARAMETERS	BODY WEIGHT (kg)	HR (BPM)	IVSd (cm)	LVIDd (cm)	LVWd (cm)	FS (%)	EF (%)
NORMAL PARAMETER	-----	150-240	0.3-0.6	1.0-2.1	0.25-0.6	35-67	80-100
PATIENT	4.27 kg	200	0.56	1.54	0.54	40	74
FELINE CARDIAC PARAMETERS	LA/AO (M-mode)	LA/AO HEART BASE (Sisson)	LAD LA MAX 4 Chamber		LVOT VEL. (m/s)	RVOT VEL. (m/s)	IVRT (m/)
NORMAL PARAMETER	<1.5	1.6	0.7-1.7		<1.6	<1.3	40-60
PATIENT	NM	1.36	1.40		1.0	0.5	NM
Adapted from June Boon, Veterinary Echocardiography, 1998							
Sisson D et al. JVIM 1991; 5: 232, Jacobs et al. Am J Vet Res 1985; 46:1705							

**Cardiac Presentation**

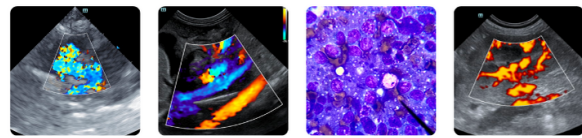
The left atrium is normal in dimension. There are no distinct left atrial thrombi/clots or spontaneous echo contrast appreciated. The left ventricle is normal in dimension with equivocal wall thickness, and no evidence of restriction. Left ventricular systolic function is normal, with adequate contractility. The right atrium and ventricle are subjectively normal in dimension and systolic function. The anterior and posterior mitral and tricuspid valve leaflets presented normal linear structure, extension in systole, and union in diastole without regurgitation. There is no evidence of systolic anterior mitral valve motion documented. The left ventricular outflow tract demonstrated normal laminar flow and subjective structural valvular integrity. The visible aorta is unremarkable. Pulmonary outflow tract assessment revealed normal valve structure, laminar flow, and appropriate diameter and distensibility. There is no evidence of pulmonary hypertension documented. There is no visible pericardial, pleural, or free peritoneal fluid noted.

**ULTRASONOGRAPHIC FINDINGS**

- These findings are consistent with an essentially normal echocardiogram. Any murmur auscultated will be considered functional in origin. There has not been significant progression since the previous study performed.

**INTERPRETATION OF THE FINDINGS & FURTHER RECOMMENDATIONS**

Given these findings, no cardiac therapy is recommended. There are no cardiac contraindications to corticosteroids or fluid therapy as indicated for further treatment. A recheck echocardiogram is



**PATIENT**

recommended in 12 months to monitor for potential progression, or sooner if clinical signs of heart disease develop.

Frank Hudson

**SPECIES**

Anesthesia considerations:  
 No special cardiac considerations are necessary

Feline

Diet:  
 No special considerations are necessary. Any high-quality food from Hills, Royal Canin, Science Diet, Eukanuba, Iams, or Purina is reasonable.

**BREED**

DSH

Activity:  
 No special considerations are necessary.

**SEX**

Neutered Male

**AGE**

7 years 4 months

**WEIGHT**

9.4 lbs

**INTERPRETED BY**

Bradley Harris, DVM,  
 DACVECC, DACVIM  
 (cardiology)

**IMAGING PERFORMED BY**

Kerri Becker

**HOSPITAL NAME**

Englewood VC

**REFERRING VET**

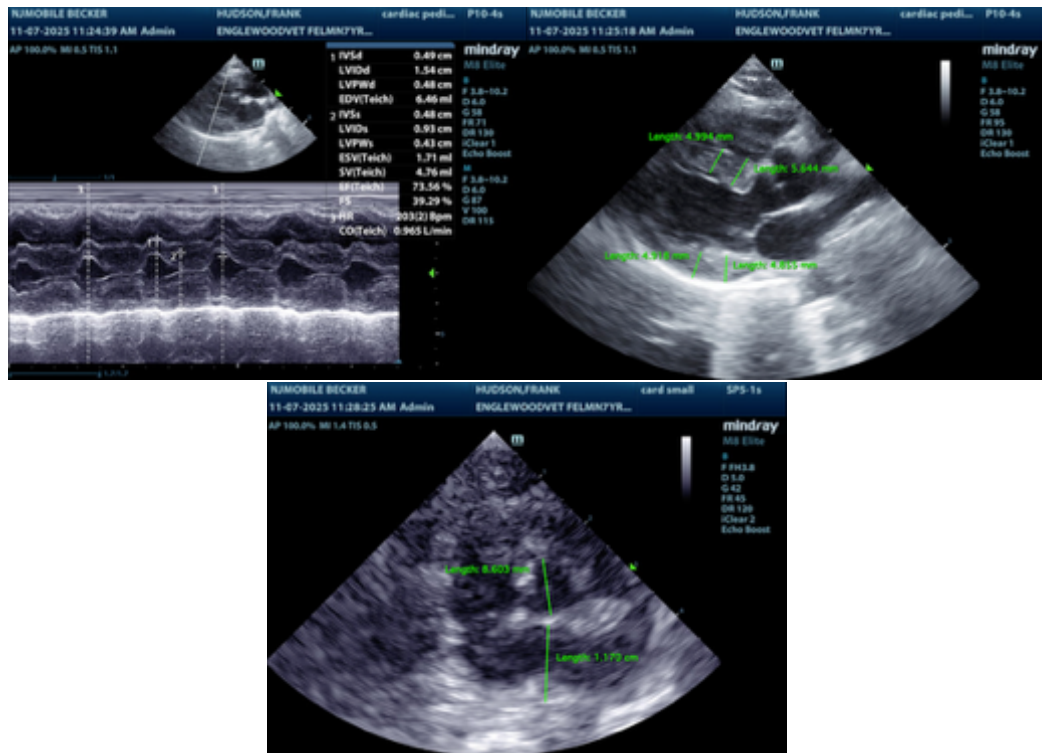
Dr. Ezik

**INVOICE**

10704

**DATE**

11/7/2025



The information and recommendations provided are based on the images presented by the referring veterinarian/sonographer. No evaluation can be communicated regarding pathology that was not visible in the image/video clips provided.

Thank you for this referral. If the clinical or image interpretation does not parallel your findings or if I can be of any further assistance please contact me.

**Bradley Harris, DVM, DACVECC, DACVIM (cardiology)**

[info@SonoPath.com](mailto:info@SonoPath.com)