



## PATIENT

Barron Novak

## SPECIES

Canine

## BREED

Pitbull Cross

## SEX

Neutered male

## AGE

9 years

## WEIGHT

70 lbs

## PRESENTING CLINICAL SIGNS

History: echo performed last year revealed mild left ventricular hypertrophy when having coughing issues. Coughing has since resolved but recheck echo was recommended to ensure no worsening. P required sedation - dexmed- 0.3 mL IV, torb- 0.3 mL IV  
Abnormal PE/Chem/CBC/UA Results: no murmur, no concerns

## ULTRASONOGRAPHIC EXAMINATION OF THE HEART

The left atrium is normal in dimension. The left ventricle is upper limits of normal in dimension, enlarged with marginal systolic function or contractility. The myocardium is normal echogenicity and wall thickness, without subjective evidence of significant fibrotic or ischemic disease. The right atrium and ventricle are subjectively normal in dimension and systolic function. The anterior and posterior mitral valve leaflets presented normal linear structure with moderate regurgitation noted. The tricuspid valve is subjectively normal with mild regurgitation, and no evidence of pulmonary hypertension. The left ventricular outflow tract demonstrated normal laminar flow and subjective structural valvular integrity. The visible aorta is unremarkable. Pulmonary outflow tract assessment revealed normal valve structure, laminar flow, and appropriate diameter and distensibility. There is evidence of trace pulmonic valve insufficiency documented. There is no visible pericardial, pleural, or free peritoneal fluid noted. The cardiac chambers, pericardial and visible extra-cardiac regions were free of masses, spontaneous echo contrast, or thrombi.

## INTERPRETED BY

Bradley Harris, DVM,  
DACVECC, DACVIM  
(cardiology)

## IMAGING PERFORMED BY

Christopher Roberts

## HOSPITAL NAME

Kentown AH

## REFERRING VET

Dr. Roberts

## INVOICE

68386

## DATE

11/6/25

| CANINE CARDIAC PARAMETERS | Body Weight kg | HR BPM | LAD 4 ch Long  | RAD 4 ch Long    | La/Ao Heart Base | LVIDd   | LVIDs                            |
|---------------------------|----------------|--------|----------------|------------------|------------------|---------|----------------------------------|
| NORMAL PARAMETER          |                | 50-100 |                |                  | <1.6             |         |                                  |
| PATIENT                   | 31.82 kg       | 40     | 4.4            | 3.53             | 1.3              | 4.97    | 3.8                              |
| CANINE CARDIAC PARAMETERS | FS             | EPSS   | PV V MAX (m/s) | AV V Max (m/sec) | MR Vmax          | TR Vmax | RPA distensibility (normal >30%) |
| NORMAL PARAMETER          | 28-40          | <0.6   | 0.7-1.6        | 0.7-1.7          | 4.5-5.5          | < 2.7   |                                  |
| PATIENT                   | 24             | 0.7    | 0.5            | 1.5              | 4.6              | NM      | NM                               |

## ULTRASONOGRAPHIC FINDINGS

These findings identify reduced left ventricular function in the setting of an borderline left ventricle. This is likely secondary to the use of an alpha-2 agonist for sedation, however, intrinsic myocardial dysfunction (ie DCM) is a concern. Other possibilities, including primary valve disease with secondary ventricular changes or myocardial depressant effects of systemic disease must also be considered. It would also be important to verify that the owners are not feeding a grain-free, exotic, or boutique diet, as a secondary nutritional cardiomyopathy must also be considered.



## PATIENT

Barron Novak

## SPECIES

Canine

## BREED

Pitbull Cross

## SEX

Neutered male

## AGE

9 years

## WEIGHT

70 lbs

## INTERPRETED BY

Bradley Harris, DVM,  
DACVECC, DACVIM  
(cardiology)

## IMAGING PERFORMED BY

Christopher Roberts

## HOSPITAL NAME

Kentown AH

## REFERRING VET

Dr. Roberts

## INVOICE

68386

## DATE

11/6/25

## INTERPRETATION OF THE FINDINGS & FURTHER RECOMMENDATIONS

At this time, therapy for the myocardial dysfunction can be considered, to include Vetmedin (0.25-0.35 mg/kg BID) and enalapril (0.5 mg/kg BID, assuming normotension and lack of renal insult). If the owners are feeding a grain free diet, an immediate diet change would be necessary, and the addition of taurine (50 mg/kg BID) would be appropriate. If there is any concern for metabolic/systemic disease, additional testing (complete bloodwork including T4 and resting cortisol, abdominal ultrasound) should be considered. Otherwise, thoracic radiographs, blood pressure, and chemistry panel should be performed now for a baseline, and again in 1-2 weeks. A follow-up echocardiogram, thoracic radiographs, blood pressure, and chemistry panel is recommended in 3 months to assess for either static, improved, or progressive changes. Owners should monitor resting respiratory rate at home. Values above 30 breaths/minute or an increase in respiratory rate 10% above baseline should prompt veterinary re-evaluation.

The following sources for supplemental taurine are recommended:

Mega taurine caps by Twinlab (1000mg capsule)

Taurine by Swanson Health Products (500mg capsule)

Taurine by NOW foods (500mg capsule)

Taurine 500 by GNC (500mg tablet)

### Anesthesia considerations:

Anesthesia should be avoided if possible. If anesthesia is necessary, then alpha-2 agonists, ketamine, high dose acepromazine, and Telazol should be avoided. If an ACE inhibitor (enalapril, benazepril) or spironolactone is being given, it should not be administered on the morning of general anesthesia. Other cardiac medications should be administered per the normal dosing schedule. Fluid therapy during anesthesia should be considered at a reduced rate (e.g., 5 ml/kg/hour) if possible (i.e., if not hypotensive). A shorter anesthetic duration will reduce the risk of complications. Pre-oxygenation is advised. Premedication with an opioid (i.e., butorphanol, hydromorphone, oxymorphone) with or without a benzodiazepine is generally the safest protocol. An induction agent such as Propofol, alfaxalone, or diazepam/etomidate can be used to effect. Maintenance of anesthesia with isoflurane or sevoflurane is reasonable. Dobutamine (2.5-10 µg/kg/min as a CRI, starting at 2.5 µg/kg/min and increasing the dosage incrementally) may be used in lieu of fluid boluses to augment systemic blood pressure.

### Diet:

A high-quality food from Hills, Royal Canin, Science Diet, Eukanuba, Iams, or Purina that is highly palatable with adequate protein and calories for maintaining optimal body condition. Consider omega-3 fatty acid supplementation. Ensure the patient is not currently receiving a boutique, exotic, or grain-free diet.

### Activity:

Moderate physical activity (meandering walks, exploring the backyard, playing with toys inside, getting excited when family gets home, etc.) is encouraged, but periods of strenuous aerobic activity (jogging, strenuous outdoor ball play, prolonged play at the dog park, etc.) should be avoided, especially during periods of high heat (> 80 F) and humidity. Dogs with heart disease tend to tolerate cool and cold temperatures much better than high temperatures. Avoid sudden increases in activity (e.g. 2 block walks during the week but 2 mile walks followed by 30 minutes at the dog park on the weekends) as this may be difficult for the cardiovascular system to deal with.



## PATIENT

Barron Novak

## SPECIES

Canine

## BREED

Pitbull Cross

## SEX

Neutered male

## AGE

9 years

## WEIGHT

70 lbs

## INTERPRETED BY

Bradley Harris, DVM,  
DACVECC, DACVIM  
(cardiology)

## IMAGING PERFORMED BY

Christopher Roberts

## HOSPITAL NAME

Kentown AH

## REFERRING VET

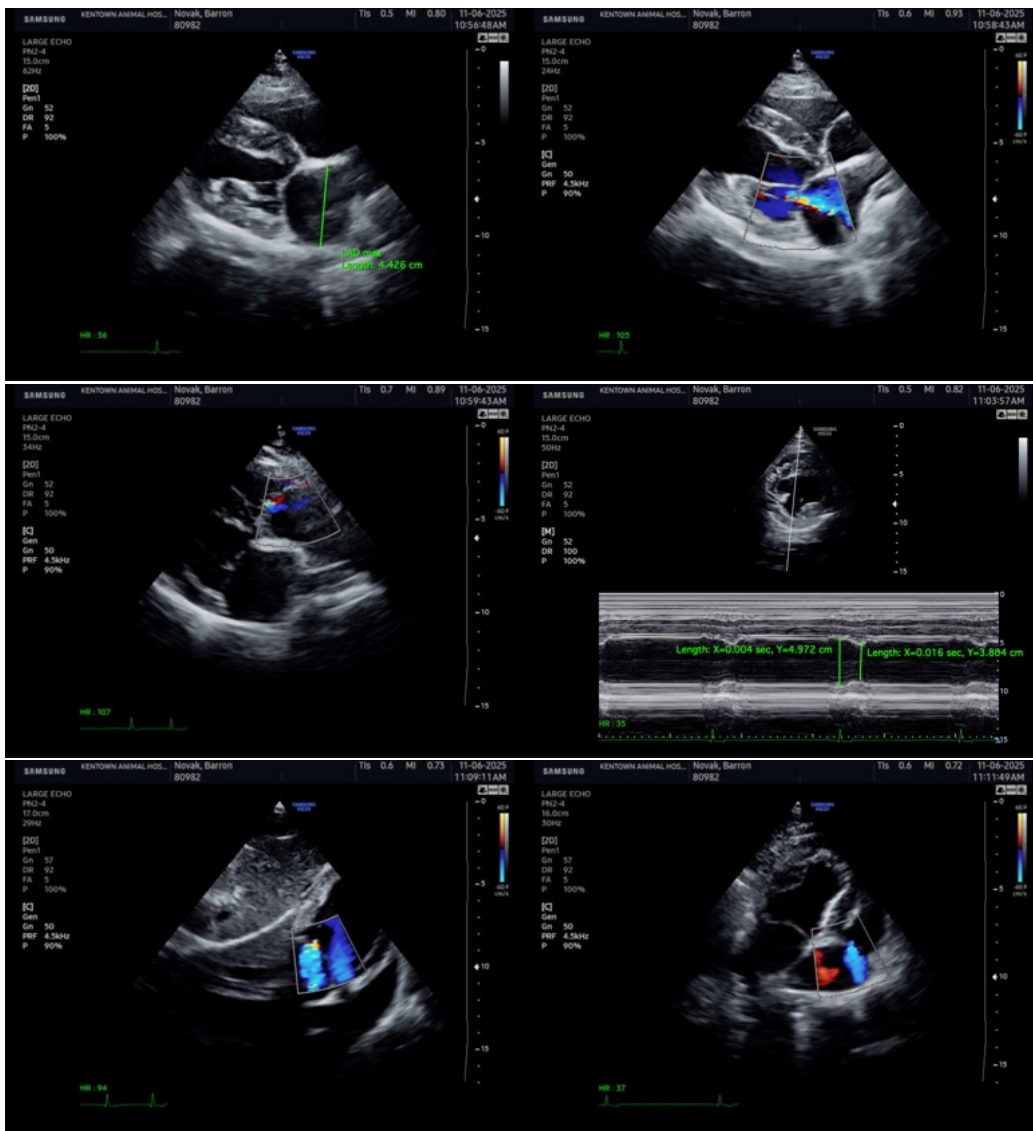
Dr. Roberts

## INVOICE

68386

## DATE

11/6/25



The information and recommendations provided are based on the images presented by the referring veterinarian/sonographer. No evaluation can be communicated regarding pathology that was not visible in the image/video clips provided.

Thank you for this referral. If the clinical or image interpretation does not parallel your findings or if I can be of any further assistance please contact me.

Bradley Harris, DVM, DACVECC, DACVIM (cardiology)

[info@SonoPath.com](mailto:info@SonoPath.com)