

## PATIENT

Gemma Brady

## SPECIES

Feline

## BREED

Domestic Shorthair

## SEX

Spayed female

## AGE

9 years

## WEIGHT

13.6 lbs

## INTERPRETED BY

Bradley Harris, DVM,  
DACVECC, DACVIM  
(cardiology)

## IMAGING PERFORMED BY

Tiffany Brady DVM

## HOSPITAL NAME

Shiloh VH

## REFERRING VET

Dr. Brady

## INVOICE

68299

## DATE

11/4/25

## PRESENTING CLINICAL SIGNS

History: Seen for severe constipation 9/15. CBC/Chem/UA/T4/FeLV/FIV, ECG, and GI panel all unremarkable Noted 2/6 heart murmur (not noted on follow up) Currently on lactulose, cisapride and Royal Canin GI diet doing well  
Abnormal PE/Chem/CBC/UA Results: folate mildly decreased 9.5 (low end of normal 9.7)

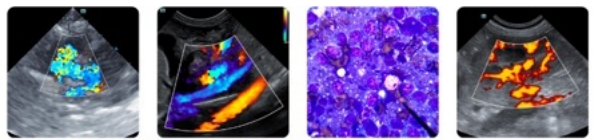
## ULTRASONOGRAPHIC EXAMINATION OF THE HEART

The left atrium is normal in dimension. There are no distinct left atrial thrombi/clots or spontaneous echo contrast appreciated. The left ventricle is normal in dimension as well as wall thickness, and no evidence of restriction. Left ventricular systolic function is normal, with adequate contractility. The right atrium and ventricle are subjectively normal in dimension and systolic function. The anterior and posterior mitral and tricuspid valve leaflets presented normal linear structure, extension in systole, and union in diastole without regurgitation. There is no evidence of systolic anterior mitral valve motion documented. The left ventricular outflow tract demonstrated normal laminar flow and subjective structural valvular integrity. The visible aorta is unremarkable. Pulmonary outflow tract assessment revealed normal valve structure, laminar flow, and appropriate diameter and distensibility. There is no evidence of pulmonary hypertension documented. There is no visible pericardial, pleural, or free peritoneal fluid noted.

FELINE CARDIAC PARAMETERS	BODY WEIGHT (kg)	HR (BPM)	IVSd (cm)	LVIDd (cm)	LWVd (cm)	FS (%)	EF (%)
NORMAL PARAMETER	-----	150-240	0.3-0.6	1.0-2.1	0.25-0.6	35-67	80-100
PATIENT	6.18 kg	NM	0.56	1.36	0.5	49	NM
FELINE CARDIAC PARAMETERS	LA/AO (M-mode)	LA/AO HEART BASE (Sisson)	LAD LA MAX 4 Chamber		LVOT VEL. (m/s)	RVOT VEL. (m/s)	IVRT (m/)
NORMAL PARAMETER	<1.5	1.6	0.7-1.7		<1.6	<1.3	40-60
PATIENT	NM	1.34	1.08		Not evaluated due to anesthesia	Not evaluated due to anesthesia	NM
Adapted from June Boon, Veterinary Echocardiography, 1998 Sisson D et al. JVIM 1991; 5: 232, Jacobs et al. Am J Vet Res 1985; 46:1705							

## ULTRASONOGRAPHIC FINDINGS

These findings are consistent with an essentially normal echocardiogram, however due to the administration of anesthesia, a dynamic outflow tract obstruction cannot be completely ruled out. Regardless, any murmur auscultated will be considered functional in origin.



**PATIENT**

Gemma Brady

**SPECIES**

Feline

**BREED**

Domestic Shorthair

**SEX**

Spayed female

**AGE**

9 years

**WEIGHT**

13.6 lbs

**INTERPRETED BY**

Bradley Harris, DVM,  
DACVECC, DACVIM  
(cardiology)

**IMAGING PERFORMED BY**

Tiffany Brady DVM

**HOSPITAL NAME**

Shiloh VH

**REFERRING VET**

Dr. Brady

**INVOICE**

68299

**DATE**

11/4/25

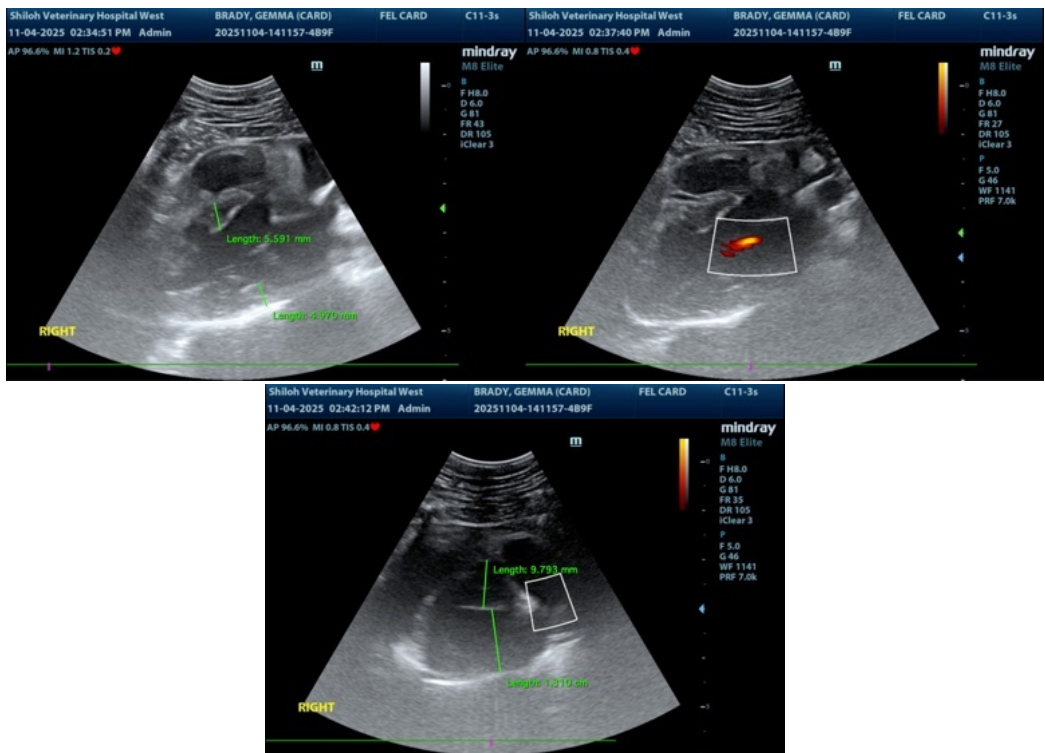
**INTERPRETATION OF THE FINDINGS & FURTHER RECOMMENDATIONS**

Given these findings, no cardiac therapy is recommended. There are no cardiac contraindications to corticosteroids or fluid therapy as indicated for further treatment. No specific recheck echocardiogram is recommended.

Anesthesia considerations:  
No special cardiac considerations are necessary

Diet:  
No special considerations are necessary. Any high-quality food from Hills, Royal Canin, Science Diet, Eukanuba, Iams, or Purina is reasonable.

Activity:  
No special considerations are necessary.



The information and recommendations provided are based on the images presented by the referring veterinarian/sonographer. No evaluation can be communicated regarding pathology that was not visible in the image/video clips provided.

Thank you for this referral. If the clinical or image interpretation does not parallel your findings or if I can be of any further assistance please contact me.

Bradley Harris, DVM, DACVECC, DACVIM (cardiology)

[info@SonoPath.com](mailto:info@SonoPath.com)