



PATIENT

Asher Longobardi

SPECIES

Canine

BREED

Border Collie

SEX

Male

AGE

7 years

WEIGHT

4 lbs

INTERPRETED BY

Bradley Harris, DVM,
DACVECC, DACVIM
(cardiology)

IMAGING PERFORMED BY

Arielle Roldan CVT

HOSPITAL NAME

Milford AH

REFERRING VET

Dr. Grasso

INVOICE

68258

DATE

11/3/25

PRESENTING CLINICAL SIGNS

History: Staff pet: Asymptomatic; murmur (grade II) found upon routine examination- was not present at last exam approx 6 months ago. Pt is a sport and working dog-o has not noticed any decline in fitness while working/playing/training.
Abnormal PE/Chem/CBC/UA Results: As of 5/29/2025: -ALT 262 (ref range 18 - 121): pt on liver support chews -T4 1.0 (ref range 1.0-4.0): pt on thyro-tabs 0.5mg SID All other values WNL. Bloodwork being rechecked today 11/3/2025

ULTRASONOGRAPHIC EXAMINATION OF THE HEART

The left atrium is normal in dimension. The left ventricle is normal in dimension with normal systolic function. The right atrium and ventricle are subjectively normal in dimension and systolic function. The mitral valve is thickened and redundant consistent with myxomatous changes, and there is no significant prolapse. There is evidence of mild mitral regurgitation. The tricuspid valve leaflets are subjectively normal with no tricuspid regurgitation and no evidence of pulmonary hypertension. The left ventricular outflow tract demonstrated normal laminar flow and the visible aorta is unremarkable. The right ventricular outflow tract assessment revealed normal laminar flow, and appropriate diameter and distensibility. There is no evidence of semilunar valve insufficiency. There is no visible pericardial, pleural, or free peritoneal fluid noted. The cardiac chambers, pericardial and visible extra-cardiac regions were free of masses, spontaneous echo contrast, or thrombi.

CANINE CARDIAC PARAMETERS	BW	HR BPM	LAD 4 ch Long	RAD 4 ch Long	La/Ao Heart Base	LVIDd	LVIDs
NORMAL PARAMETER		50-100			<1.6		
PATIENT	20.23	NM	4.2	2.46	1.47	4.0	2.2
CANINE CARDIAC PARAMETERS	FS	EPSS	PV V MAX (m/s)	AV V Max (m/sec)	MR Vmax	TR Vmax	RPA distensibility (normal >30%)
NORMAL PARAMETER	28-40	<0.6	0.7-1.6	0.7-1.7	4.5-5.5	< 2.7	
PATIENT	45	0.2	0.8	1.6	5.0	NM	NM

ULTRASONOGRAPHIC FINDINGS

These findings are consistent with degenerative/myxomatous mitral valve disease with minimal to mild hemodynamic effects consistent with ACVIM Stage B1 disease. It is unlikely that any current morbidity is of cardiac origin.



PATIENT

Asher Longobardi

SPECIES

Canine

BREED

Border Collie

SEX

Male

AGE

7 years

WEIGHT

4 lbs

INTERPRETED BY

Bradley Harris, DVM,
DACVECC, DACVIM
(cardiology)

IMAGING PERFORMED BY

Arielle Roldan CVT

HOSPITAL NAME

Milford AH

REFERRING VET

Dr. Grasso

INVOICE

68258

DATE

11/3/25

INTERPRETATION OF THE FINDINGS & FURTHER RECOMMENDATIONS

Given these findings, no cardiac therapy is recommended. There are no cardiac contraindications to anesthesia, fluid therapy, vasopressor therapy, or corticosteroids as indicated for further assessment and treatment. If not already performed, baseline thoracic radiographs and blood pressure are recommended. A recheck echocardiogram is recommended in 6 months.

Anesthesia considerations:

If anesthesia is necessary, alpha-2 agonists, ketamine, high dose acepromazine, and Telazol should be avoided. Fluid therapy during anesthesia should be considered at a conservative rate (e.g., 5 ml/kg/hour) if possible.

Diet:

A high-quality food from Hills, Royal Canin, Science Diet, Eukanuba, Iams, or Purina that is highly palatable with adequate protein and calories for maintaining optimal body condition is reasonable.

Activity:

No special considerations are necessary.



PATIENT

Asher Longobardi

SPECIES

Canine

BREED

Border Collie

SEX

Male

AGE

7 years

WEIGHT

4 lbs

INTERPRETED BY

Bradley Harris, DVM,
DACVECC, DACVIM
(cardiology)

IMAGING PERFORMED BY

Arielle Roldan CVT

HOSPITAL NAME

Milford AH

REFERRING VET

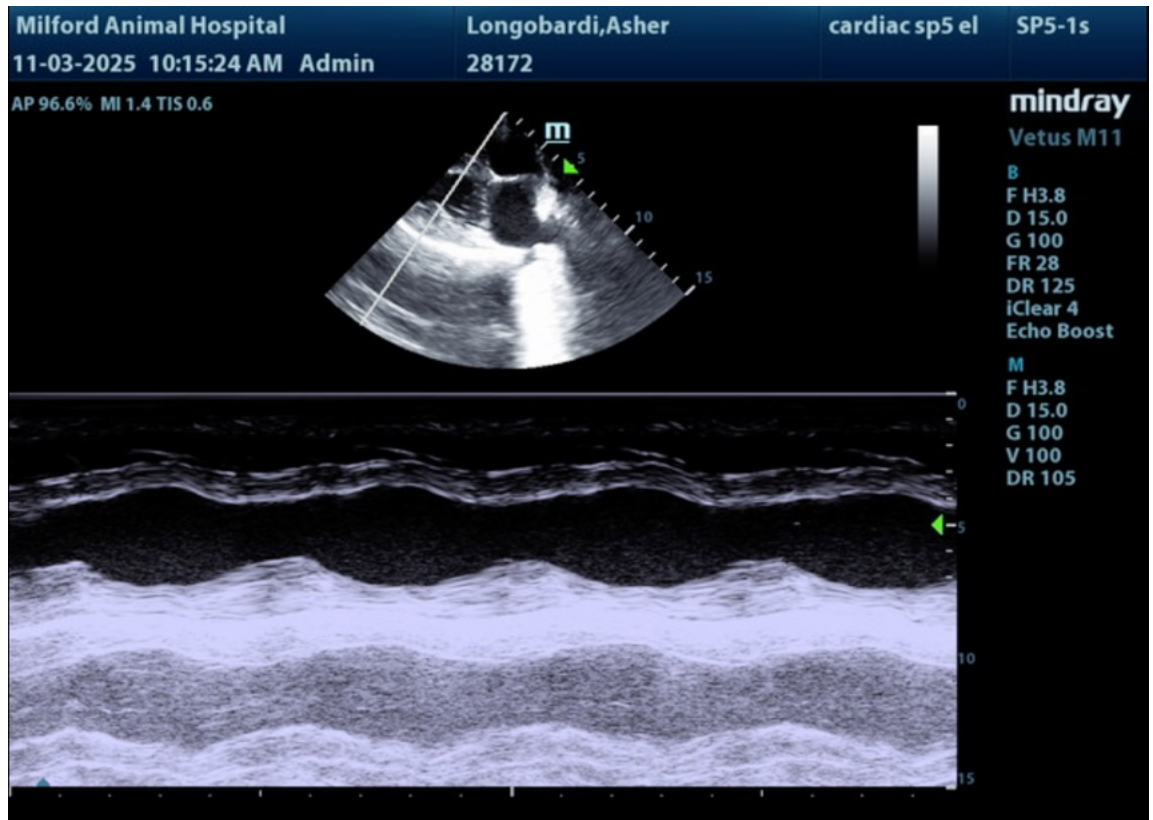
Dr. Grasso

INVOICE

68258

DATE

11/3/25





PATIENT

Asher Longobardi

SPECIES

Canine

BREED

Border Collie

SEX

Male

AGE

7 years

WEIGHT

4 lbs

INTERPRETED BY

Bradley Harris, DVM,
DACVECC, DACVIM
(cardiology)

IMAGING PERFORMED BY

Arielle Roldan CVT

HOSPITAL NAME

Milford AH

REFERRING VET

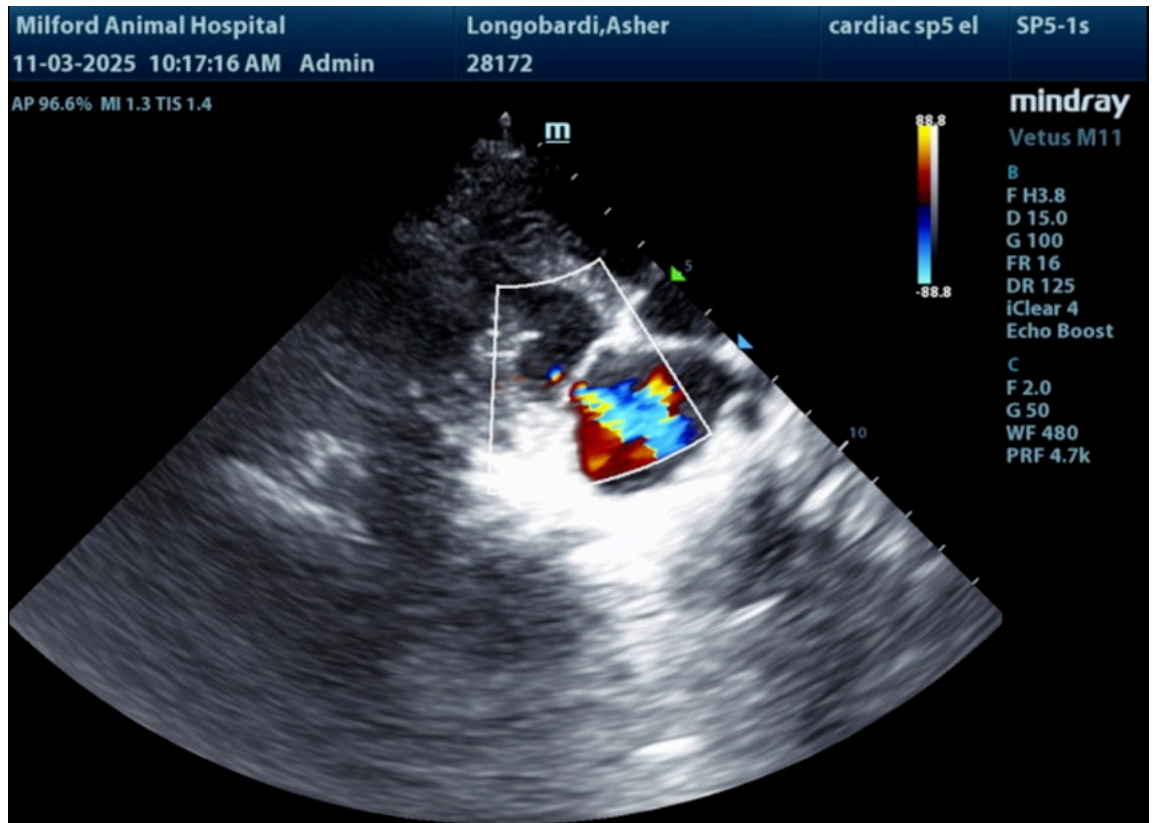
Dr. Grasso

INVOICE

68258

DATE

11/3/25





PATIENT

Asher Longobardi

SPECIES

Canine

BREED

Border Collie

SEX

Male

AGE

7 years

WEIGHT

4 lbs

INTERPRETED BY

Bradley Harris, DVM,
DACVECC, DACVIM
(cardiology)

IMAGING PERFORMED BY

Arielle Roldan CVT

HOSPITAL NAME

Milford AH

REFERRING VET

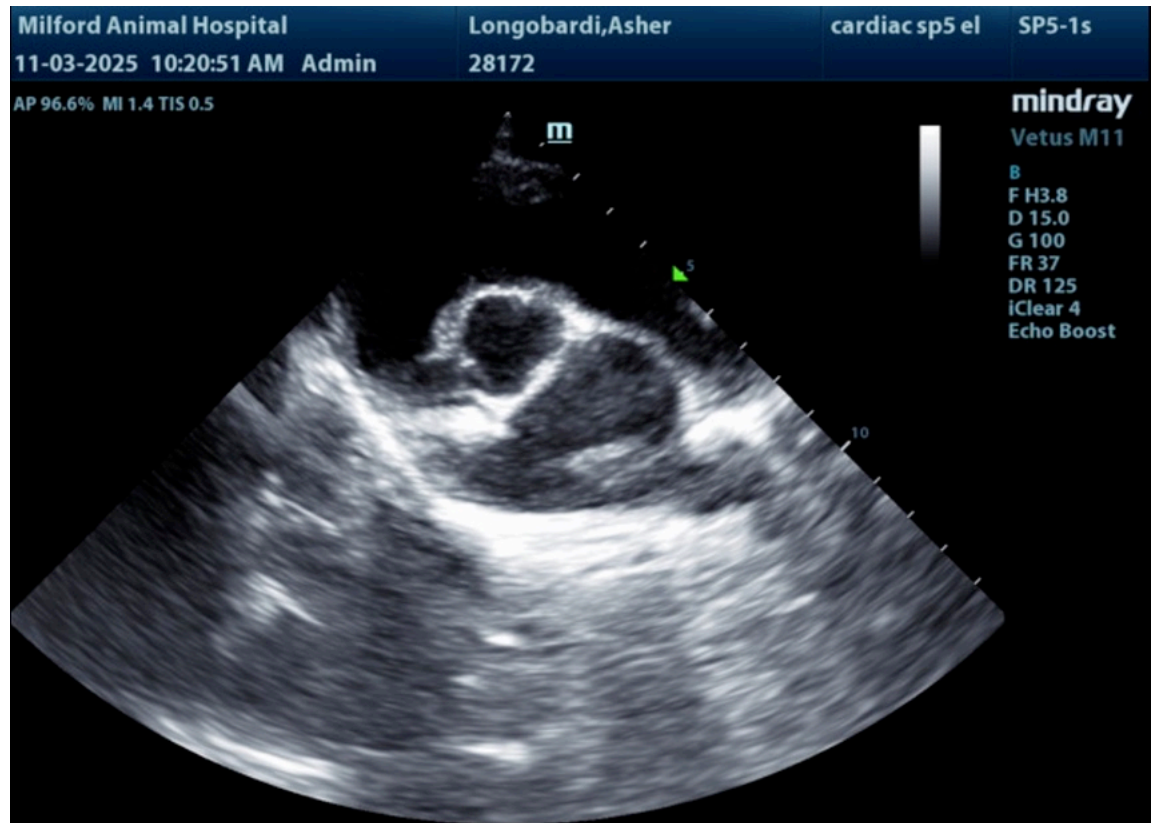
Dr. Grasso

INVOICE

68258

DATE

11/3/25



The information and recommendations provided are based on the images presented by the referring veterinarian/sonographer. No evaluation can be communicated regarding pathology that was not visible in the image/video clips provided.

Thank you for this referral. If the clinical or image interpretation does not parallel your findings or if I can be of any further assistance please contact me.

Bradley Harris, DVM, DACVECC, DACVIM (cardiology)

info@SonoPath.com