



PATIENT

Cuddles Chan

SPECIES

Feline

BREED

DSH

SEX

Neutered Male

AGE

13 Years

WEIGHT

7.3 kg

INTERPRETED BY

Brad Harris, DVM,
DACVECC, Residency
trained in cardiology

IMAGING PERFORMED BY

Dr. Gira

HOSPITAL NAME

Creekside Veterinary
Hospital

REFERRING VET

Dr. Singh

INVOICE

72199

DATE

11/29/25

PRESENTING CLINICAL SIGNS

Heart Murmur 4/6 chronic, no arrhythmia, no other clinical signs. Patient requires dental procedure
Abnormal PE/Chem/CBC/UA Results: Attached Normal Pro BNP and T4

ULTRASONOGRAPHIC EXAMINATION OF THE HEART

FELINE CARDIAC PARAMETERS	BODY WEIGHT (kg)	HR (BPM)	IVSd (cm)	LVIDd (cm)	LVWd (cm)	FS (%)	EF (%)
NORMAL PARAMETER	-----	150-240	0.3-0.6	1.0-2.1	0.25-0.6	35-67	80-100
PATIENT	7.3	120	0.45	1.55	0.47	33	99
FELINE CARDIAC PARAMETERS	LA/AO (M-mode)	LA/AO HEART BASE (Sisson)	LAD LA MAX 4 Chamber	LVOT VEL. (m/s)	RVOT VEL. (m/s)	IVRT (m/)	
NORMAL PARAMETER	<1.5	1.6	0.7-1.7	<1.6	<1.3	40-60	
PATIENT	1.2	1.32	1.57	0.9	0.6	NM	
Adapted from June Boon, Veterinary Echocardiography, 1998 Sisson D et al. JVIM 1991; 5: 232, Jacobs et al. Am J Vet Res 1985; 46:1705							

Cardiac Presentation

The left atrium is normal in dimension. There are no distinct left atrial thrombi/clots or spontaneous echo contrast appreciated. The left ventricle is normal in dimension as well as wall thickness, and no evidence of restriction. Left ventricular systolic function is normal, with adequate contractility. The right atrium and ventricle are subjectively normal in dimension and systolic function. The anterior and posterior mitral and tricuspid valve leaflets presented normal linear structure, extension in systole, and union in diastole without regurgitation. There is no evidence of systolic anterior mitral valve motion documented. The left ventricular outflow tract demonstrated normal laminar flow and subjective structural valvular integrity. The visible aorta is unremarkable. Pulmonary outflow tract assessment revealed normal valve structure, laminar flow, and appropriate diameter and distensibility. There is no evidence of pulmonary hypertension documented. There is no visible pericardial, pleural, or free peritoneal fluid noted.

ULTRASONOGRAPHIC FINDINGS

- These findings are consistent with an essentially normal echocardiogram. Any murmur auscultated will be considered functional in origin.

INTERPRETATION OF THE FINDINGS & FURTHER RECOMMENDATIONS

Given these findings, no cardiac therapy is recommended. There are no cardiac contraindications to corticosteroids or fluid therapy as indicated for further treatment. No specific recheck echocardiogram is recommended.



PATIENT

Cuddles Chan

SPECIES

Feline

BREED

DSH

SEX

Neutered Male

AGE

13 Years

WEIGHT

7.3 kg

INTERPRETED BY

Brad Harris, DVM,
DACVECC, Residency
trained in cardiology

**IMAGING
PERFORMED BY**

Dr. Gira

HOSPITAL NAME

Creekside Veterinary
Hospital

REFERRING VET

Dr. Singh

INVOICE

72199

DATE

11/29/25

Anesthesia considerations:

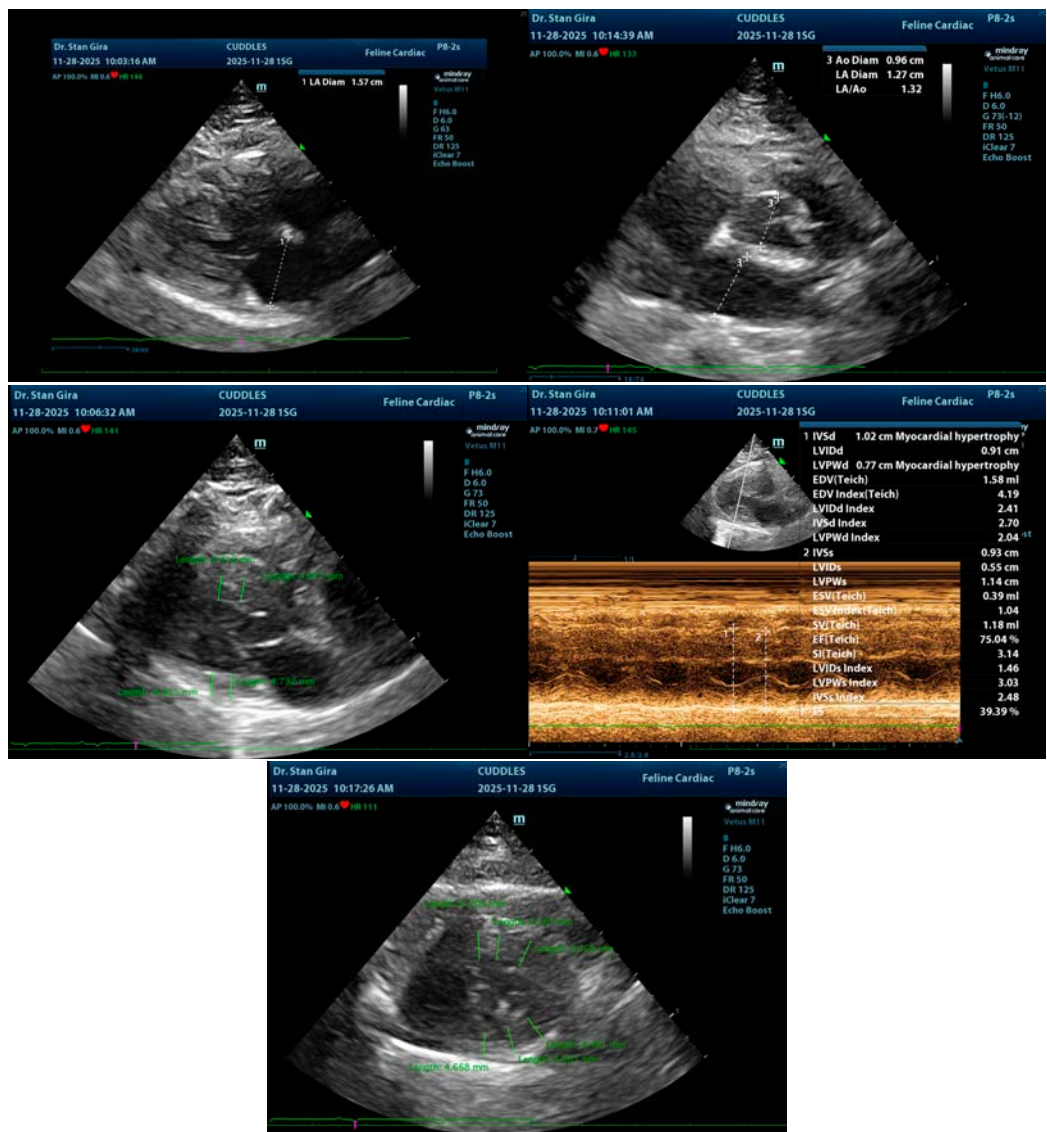
No special cardiac considerations are necessary

Diet:

No special considerations are necessary. Any high-quality food from Hills, Royal Canin, Science Diet, Eukanuba, Iams, or Purina is reasonable.

Activity:

No special considerations are necessary.





PATIENT

Cuddles Chan

SPECIES

Feline

BREED

DSH

SEX

Neutered Male

AGE

13 Years

WEIGHT

7.3 kg

INTERPRETED BY

Brad Harris, DVM,
DACVECC, Residency
trained in cardiology

IMAGING PERFORMED BY

Dr. Gira

HOSPITAL NAME

Creekside Veterinary
Hospital

REFERRING VET

Dr. Singh

INVOICE

72199

DATE

11/29/25

The information and recommendations provided are based on the images presented by the referring veterinarian/sonographer. No evaluation can be communicated regarding pathology that was not visible in the image/video clips provided.

Thank you for this referral. If the clinical or image interpretation does not parallel your findings or if I can be of any further assistance please contact me.

Brad Harris, DVM, DACVECC, Residency trained in cardiology

info@SonoPath.com