



**PATIENT**

Sharpie Rivera

**SPECIES**

Canine

**BREED**

Miniature Schnauzer

**SEX**

Spayed Female

**AGE**

10 Years

**WEIGHT**

21.2 pounds

**INTERPRETED BY**

Bradley Harris, DVM,  
DACVECC, DACVIM  
(cardiology)

**IMAGING PERFORMED BY**

Dr. Gabriel Ferrer  
DVM

**HOSPITAL NAME**

Pulse Pet Ultrasound  
Services

**REFERRING VET**

Dra. Edlyn Vazquez

**INVOICE**

12491

**DATE**

11/25/25

**PRESENTING CLINICAL SIGNS**

Presented as a referral for an echocardiogram to evaluate a heart murmur and anesthesia risk evaluation. Pt has a previous history of urolithiasis and upon recheck evaluation it was noticed that the bladder stone was larger and it was recommended surgical removal. Wanted to evaluate heart murmur prior to anesthesia.

PE: Grade 1-2/6 systolic HM Radiographs, Bloodwork and EKG attached for supporting document.

**ULTRASONOGRAPHIC EXAMINATION OF THE HEART**

CANINE CARDIAC PARAMETERS	BW	HR BPM	LAD 4 ch Long	RAD 4 ch Long	La/Ao Heart Base	LVIDd	LVIDs
NORMAL PARAMETER		50-100			<1.6		
PATIENT	9.64	80	3.04	2.30	1.19	2.83	1.87
CANINE CARDIAC PARAMETERS	FS	EPSS	PV V MAX (m/s)	AV V Max (m/sec)	MR Vmax	TR Vmax	RPA distensibility (normal >30%)
NORMAL PARAMETER	28-40	<0.6	0.7-1.6	0.7-1.7	4.5-5.5	< 2.7	
PATIENT	34	0.2	0.7	0.7	4.8	1.5	NM

**Cardiac Presentation**

The left atrium is normal in dimension. The left ventricle is normal in dimension, with normal systolic function. The right atrium and ventricle are subjectively normal in dimension and systolic function. The mitral valve is thickened and redundant consistent with myxomatous changes, and there is minimal prolapse. There is evidence of mild mitral regurgitation. The tricuspid valve leaflets are minimally thickened with mild tricuspid regurgitation and no evidence of pulmonary hypertension. The left ventricular outflow tract demonstrated normal laminar flow and the visible aorta is unremarkable. The right ventricular outflow tract assessment revealed normal laminar flow, and appropriate diameter and distensibility. There is no evidence of semilunar valve insufficiency. There is no visible pericardial, pleural, or free peritoneal fluid noted. The cardiac chambers, pericardial and visible extra-cardiac regions were free of masses, spontaneous echo contrast, or thrombi.

**ULTRASONOGRAPHIC FINDINGS**

- These findings are consistent with degenerative/myxomatous mitral valve disease with minimal to mild hemodynamic effects consistent with ACVIM Stage B1 disease. It is unlikely that any current morbidity is of cardiac origin.

**INTERPRETATION OF THE FINDINGS & FURTHER RECOMMENDATIONS**



**PATIENT**

Sharpie Rivera

**SPECIES**

Canine

**BREED**

Miniature Schnauzer

**SEX**

Spayed Female

**AGE**

10 Years

**WEIGHT**

21.2 pounds

**INTERPRETED BY**

Bradley Harris, DVM,  
DACVECC, DACVIM  
(cardiology)

**IMAGING PERFORMED BY**

Dr. Gabriel Ferrer  
DVM

**HOSPITAL NAME**

Pulse Pet Ultrasound  
Services

**REFERRING VET**

Dra. Edlyn Vazquez

**INVOICE**

12491

**DATE**

11/25/25

Given these findings, no cardiac therapy is recommended. There are no cardiac contraindications to anesthesia, fluid therapy, vasopressor therapy, or corticosteroids as indicated for further assessment and treatment. If not already performed, baseline thoracic radiographs and blood pressure are recommended. A recheck echocardiogram is recommended in 6 months.

**Anesthesia considerations:**

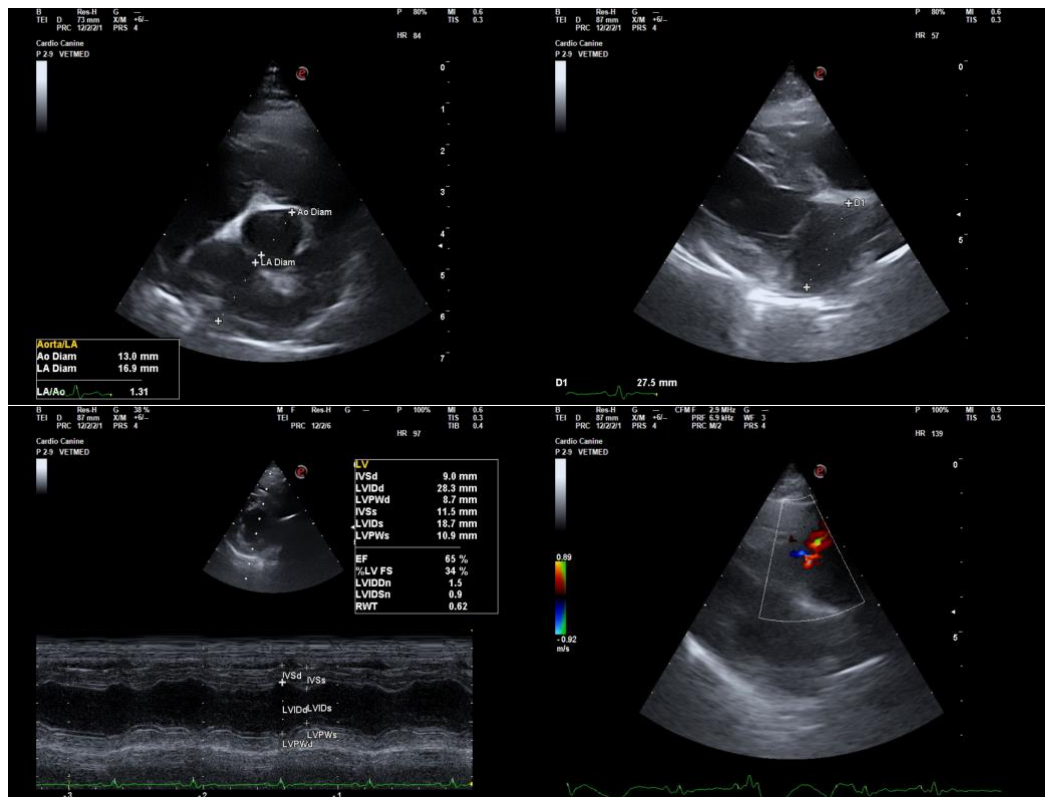
If anesthesia is necessary, alpha-2 agonists, ketamine, high dose acepromazine, and Telazol should be avoided. Fluid therapy during anesthesia should be considered at a conservative rate (e.g., 5 ml/kg/hour) if possible.

**Diet:**

A high-quality food from Hills, Royal Canin, Science Diet, Eukanuba, Iams, or Purina that is highly palatable with adequate protein and calories for maintaining optimal body condition is reasonable.

**Activity:**

No special considerations are necessary.





## PATIENT

Sharpie Rivera

## SPECIES

Canine

## BREED

Miniature Schnauzer

## SEX

Spayed Female

## AGE

10 Years

## WEIGHT

21.2 pounds

## INTERPRETED BY

Bradley Harris, DVM,  
DACVECC, DACVIM  
(cardiology)

## IMAGING PERFORMED BY

Dr. Gabriel Ferrer  
DVM

## HOSPITAL NAME

Pulse Pet Ultrasound  
Services

## REFERRING VET

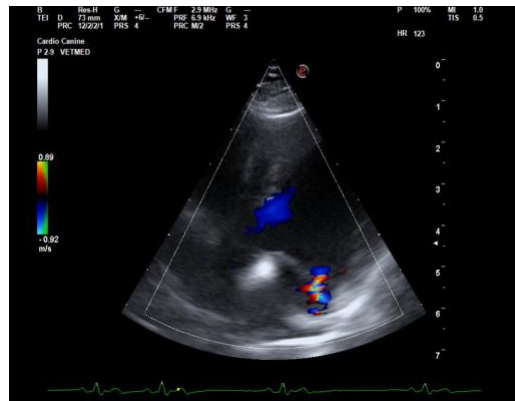
Dra. Edlyn Vazquez

## INVOICE

12491

## DATE

11/25/25



The information and recommendations provided are based on the images presented by the referring veterinarian/sonographer. No evaluation can be communicated regarding pathology that was not visible in the image/video clips provided.

Thank you for this referral. If the clinical or image interpretation does not parallel your findings or if I can be of any further assistance please contact me.

**Bradley Harris, DVM, DACVECC, DACVIM (cardiology)**

[info@SonoPath.com](mailto:info@SonoPath.com)