



PATIENT

Molly Wylie-Peterson

SPECIES

Feline

BREED

DSH

SEX

FS

AGE

13 years

WEIGHT

5.5 lbs

INTERPRETED BY

Bradley Harris, DVM,
DACVECC, DACVIM
(cardiology)

IMAGING PERFORMED BY

Yvonna Aranda

HOSPITAL NAME

Four Corners
Veterinary Clinic

REFERRING VET

Dr. Dull

INVOICE

10764

DATE

11/18/2025

PRESENTING CLINICAL SIGNS

Abnormal ProBNP.

Abnormal PE/Chem/CBC/UA Results: ABNORMAL Labwork Values Last CBC performed 10/3/2025 - elevated PLTs=845, elevated Plateletcrit=1.3, all else WNL Last Chem performed 10/3/2025 - improved SDMA=29, was 42 improved Crea=1.8, was 1.9 improved BUN=57, was 93 improved T4=1.3, was 6.9 10/3/2025 - Abnormal ProBNP 10/31/2025 - Quantitative ProBNP >1,500 (normal=0-100) For ECHO Only: Blood Pressure 184/125 (141), 190/128 (149), 187/126 (155), 182/119 (160), 187/127 (154) HR/RR/BP: HR=230bpm, RR=40 Is there a Heart Murmur? If so, please grade. no Current Medications Gabapentin 50mg PO BID, Felanorm 2.5mg PO BID, Royal Canin Renal Support, Porus One for Cats Radiographic Findings.

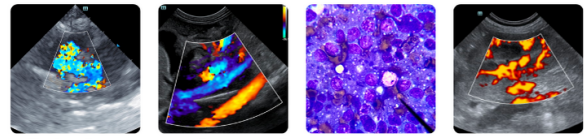
ULTRASONOGRAPHIC EXAMINATION OF THE HEART

FELINE CARDIAC PARAMETERS	BODY WEIGHT (kg)	HR (BPM)	IVSd (cm)	LVIDd (cm)	LVWd (cm)	FS (%)	EF (%)
NORMAL PARAMETER	-----	150-240	0.3-0.6	1.0-2.1	0.25-0.6	35-67	80-100
PATIENT	2.5 kg	200	0.48	1.14	0.43	57%	90%
FELINE CARDIAC PARAMETERS	LA/AO (M-mode)	LA/AO HEART BASE (Sisson)	LAD LA MAX 4 Chamber		LVOT VEL. (m/s)	RVOT VEL. (m/s)	IVRT (m/)
NORMAL PARAMETER	<1.5	1.6	0.7-1.7		<1.6	<1.3	40-60
PATIENT	NM	1.54	1.45		0.9	1.5	NM
Adapted from June Boon, Veterinary Echocardiography, 1998 Sisson D et al. JVIM 1991; 5: 232, Jacobs et al. Am J Vet Res 1985; 46:1705							

Cardiac Presentation

The left atrium is normal in dimension. There are no distinct left atrial thrombi/clots or spontaneous echo contrast appreciated. The left ventricle is normal in dimension as well as wall thickness, and no evidence of restriction. Left ventricular systolic function is normal, with adequate contractility based on fractional shortening and systolic left ventricular dimensions. The right atrium and ventricle are subjectively normal in dimension and systolic function. The anterior and posterior mitral and tricuspid valve leaflets presented normal linear structure, extension in systole, and union in diastole without regurgitation. There is no evidence of systolic anterior mitral valve motion documented. The left ventricular outflow tract demonstrated normal laminar flow and subjective structural valvular integrity. The visible aorta is unremarkable. Pulmonary outflow tract assessment revealed normal valve structure, laminar flow, and appropriate diameter and distensibility. There is no evidence of pulmonary hypertension documented. There is no visible pericardial, pleural, or free peritoneal fluid noted.

ECG:



PATIENT

Molly Wylie-Peterson

SPECIES

Feline

BREED

DSH

SEX

FS

AGE

13 years

WEIGHT

5.5 lbs

INTERPRETED BY

Bradley Harris, DVM,
DACVECC, DACVIM
(cardiology)

IMAGING PERFORMED BY

Yvonna Aranda

HOSPITAL NAME

Four Corners
Veterinary Clinic

REFERRING VET

Dr. Dull

INVOICE

10764

DATE

11/18/2025

There is a six-lead ECG available for review. The underlying rhythm is regular at an average rate of 210bpm. The rhythm appears to be sinus in origin (PQ 80ms) with narrow QRS complexes (<40ms). There is no atrial or ventricular ectopy and no conduction delay or block identified. This is most consistent with a normal sinus rhythm.

ULTRASONOGRAPHIC FINDINGS

- These findings are consistent with an essentially normal echocardiogram. The presence of an elevated BNP is often associated with underlying heart disease but can be seen in animals without heart disease. In addition, changes on chest X-rays can occur without significant underlying disease. The absence of any abnormalities on the echo excludes any meaningful cardiac disease at this time. Any murmur will be considered functional in origin at this time.

INTERPRETATION OF THE FINDINGS & FURTHER RECOMMENDATIONS

Given these findings, no cardiac therapy is recommended. There are no cardiac contraindications to corticosteroids or fluid therapy as indicated for further treatment. No specific recheck echocardiogram is recommended.

Anesthesia considerations:

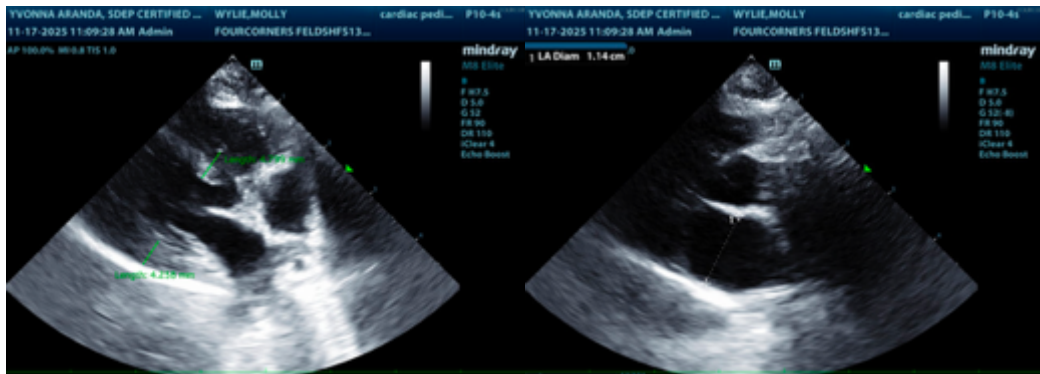
No special cardiac considerations are necessary

Diet:

No special considerations are necessary. Any high-quality food from Hills, Royal Canin, Science Diet, Eukanuba, Iams, or Purina is reasonable.

Activity:

No special considerations are necessary.





PATIENT

Molly Wylie-Peterson

SPECIES

Feline

BREED

DSH

SEX

FS

AGE

13 years

WEIGHT

5.5 lbs

INTERPRETED BY

Bradley Harris, DVM,
 DACVECC, DACVIM
 (cardiology)

IMAGING PERFORMED BY

Yvonna Aranda

HOSPITAL NAME

Four Corners
 Veterinary Clinic

REFERRING VET

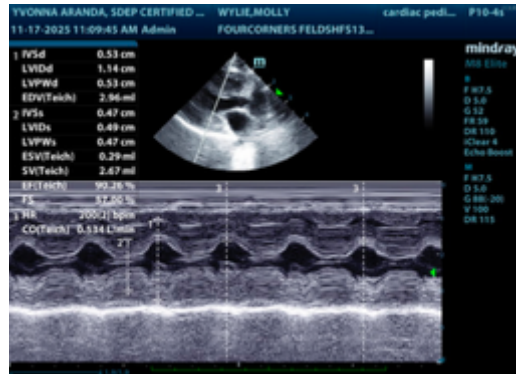
Dr. Dull

INVOICE

10764

DATE

11/18/2025



The information and recommendations provided are based on the images presented by the referring veterinarian/sonographer. No evaluation can be communicated regarding pathology that was not visible in the image/video clips provided.

Thank you for this referral. If the clinical or image interpretation does not parallel your findings or if I can be of any further assistance please contact me.

Bradley Harris, DVM, DACVECC, DACVIM (cardiology)

info@SonoPath.com