



PATIENT

Waverly Porchetta

SPECIES

Canine

BREED

Cavalier King Charles
Spaniel

SEX

Spayed Female

AGE

7 Years 9 Months

WEIGHT

23.4 pounds

INTERPRETED BY

Bradley Harris, DVM,
DACVECC, DACVIM
(cardiology)

IMAGING PERFORMED BY

Dr. Ken Leal

HOSPITAL NAME

Plainfield Animal
Hospital

REFERRING VET

Dr. Musum

INVOICE

13047

DATE

01/08/2026

PRESENTING CLINICAL SIGNS

New Heart murmur noted on 1/2/26 Grade II heart murmur Chest rads right sided diaphragmatic hemiparalysis Medications: gabapentin, apoquel, Nexgard Plus

Abnormal PE/Chem/CBC/UA Results: From May of 2025: AlkPhos = 434, Cholesterol = 362 Triglycerides = 372

ULTRASONOGRAPHIC EXAMINATION OF THE HEART

CANINE CARDIAC PARAMETERS	BW	HR BPM	LAD 4 ch Long	RAD 4 ch Long	La/Ao Heart Base	LVIDd	LVIDs
NORMAL PARAMETER		50-100			<1.6		
PATIENT	10.64	150	3.35	1.44	1.28	2.59	1.82
CANINE CARDIAC PARAMETERS	FS	EPSS	PV V MAX (m/s)	AV V Max (m/sec)	MR Vmax	TR Vmax	RPA distensibility (normal >30%)
NORMAL PARAMETER	28-40	<0.6	0.7-1.6	0.7-1.7	4.5-5.5	< 2.7	
PATIENT	30	0.5	0.8	1.0	5.6	NP	41

Cardiac Presentation

The left atrium is normal in dimension. The left ventricle is normal in dimension, with normal systolic function. The right atrium and ventricle are normal in dimension, with normal systolic function. The mitral valve is thickened and redundant consistent with myxomatous changes, and there is mild prolapse. There is evidence of mild to moderate mitral regurgitation. The tricuspid valve leaflets are subjectively normal with no tricuspid regurgitation and no evidence of pulmonary hypertension. The left ventricular outflow tract demonstrated normal laminar flow and the visible aorta is unremarkable. The right ventricular outflow tract assessment revealed normal laminar flow, and appropriate diameter and distensibility. There is no pulmonic and no aortic valve insufficiency identified. There is no visible pericardial, pleural, or free peritoneal fluid documented. No evidence of hepatic venous congestion is noted. The cardiac chambers, pericardial and visible extra-cardiac regions were free of masses, spontaneous echo contrast, or thrombi.

ULTRASONOGRAPHIC FINDINGS

- These findings are consistent with degenerative/myxomatous mitral valve disease with minimal to mild hemodynamic effects consistent with ACVIM Stage B1 disease. It is unlikely that any current morbidity is of cardiac origin.

INTERPRETATION OF THE FINDINGS & FURTHER RECOMMENDATIONS



PATIENT

Waverly Porchetta

SPECIES

Canine

BREED

Cavalier King Charles
 Spaniel

SEX

Spayed Female

AGE

7 Years 9 Months

WEIGHT

23.4 pounds

INTERPRETED BY

Bradley Harris, DVM,
 DACVECC, DACVIM
 (cardiology)

IMAGING PERFORMED BY

Dr. Ken Leal

HOSPITAL NAME

Plainfield Animal
 Hospital

REFERRING VET

Dr. Musum

INVOICE

13047

DATE

01/08/2026

Given these findings, no cardiac therapy is recommended. There are no cardiac contraindications to anesthesia, fluid therapy, vasopressor therapy, or corticosteroids as indicated for further assessment and treatment. If not already performed, baseline thoracic radiographs and blood pressure are recommended. A recheck echocardiogram is recommended in 6 months.

Anesthesia considerations:

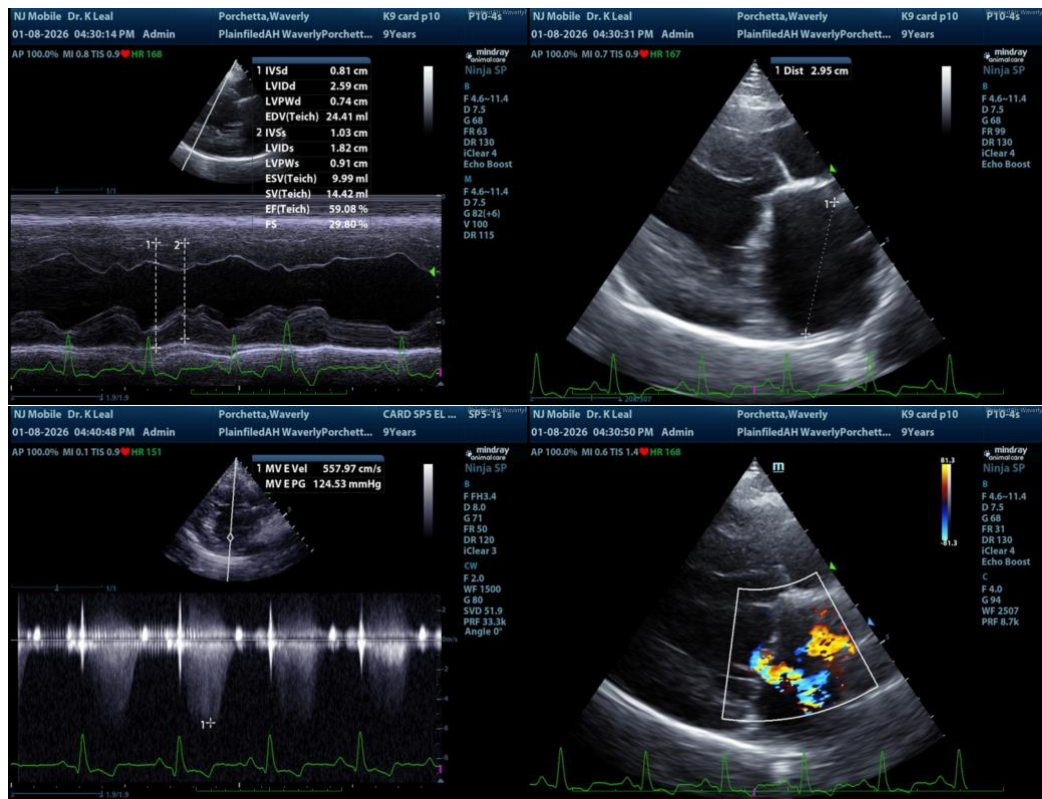
If anesthesia is necessary, alpha-2 agonists, ketamine, high dose acepromazine, and Telazol should be avoided. Fluid therapy during anesthesia should be considered at a conservative rate (e.g., 5 ml/kg/hour) if possible.

Diet:

A high-quality food from Hills, Royal Canin, Science Diet, Eukanuba, Iams, or Purina that is highly palatable with adequate protein and calories for maintaining optimal body condition is reasonable.

Activity:

No special considerations are necessary.





PATIENT

Waverly Porchetta

SPECIES

Canine

BREED

Cavalier King Charles
Spaniel

SEX

Spayed Female

AGE

7 Years 9 Months

WEIGHT

23.4 pounds

INTERPRETED BY

Bradley Harris, DVM,
DACVECC, DACVIM
(cardiology)

**IMAGING
PERFORMED BY**

Dr. Ken Leal

HOSPITAL NAME

Plainfield Animal
Hospital

REFERRING VET

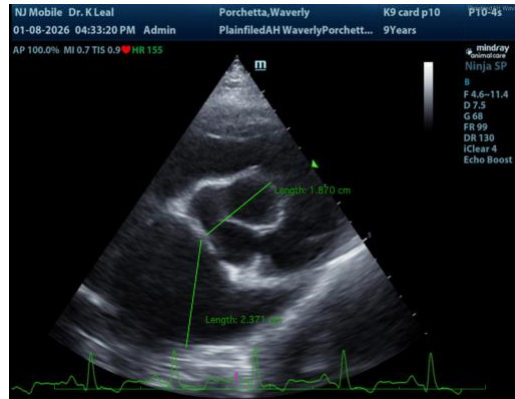
Dr. Musum

INVOICE

13047

DATE

01/08/2026



The information and recommendations provided are based on the images presented by the referring veterinarian/sonographer. No evaluation can be communicated regarding pathology that was not visible in the image/video clips provided.

Thank you for this referral. If the clinical or image interpretation does not parallel your findings or if I can be of any further assistance please contact me.

Bradley Harris, DVM, DACVECC, DACVIM (cardiology)

info@SonoPath.com