



PATIENT

Ninja Kitty Nardone

SPECIES

Feline

BREED

DSH

SEX

Spayed Female

AGE

15 Years

WEIGHT

4.9 kg

INTERPRETED BY

Bradley Harris, DVM,
DACVECC, DACVIM
(Cardiology)

IMAGING PERFORMED BY

Dr. Ethan Bloomer

HOSPITAL NAME

Echosound Veterinary
Mobile Imaging
Services

REFERRING VET

Dr. Binzer

INVOICE

13518

DATE

01/31/26

PRESENTING CLINICAL SIGNS

- This patient was recently found to have an elevated Cardiac proBNP in the 600s and suspect mild cardiomegaly on radiographs.
- The patient has no murmur but has a history of hyperthyroidism. Per staff, this has recently been over-controlled and the Methimazole dose was recently decreased.
- No notable clinical signs were reported.

Abnormal PE/Chem/CBC/UA Results: Elevated Cardiac proBNP in the 600s, mild cardiomegaly on radiographs

ULTRASONOGRAPHIC EXAMINATION OF THE HEART

| FELINE CARDIAC PARAMETERS | BODY WEIGHT (kg) | HR (BPM) | IVSd (cm) | LVIDd (cm) | LVWd (cm) | FS (%) | EF (%) |
|--|------------------|---------------------------|----------------------|------------|-----------------|-----------------|-----------|
| NORMAL PARAMETER | ----- | 150-240 | 0.3-0.6 | 1.0-2.1 | 0.25-0.6 | 35-67 | 80-100 |
| PATIENT | 4.9 | NM | 0.56 | 1.34 | 0.46 | 66 | 95 |
| FELINE CARDIAC PARAMETERS | LA/AO (M-mode) | LA/AO HEART BASE (Sisson) | LAD LA MAX 4 Chamber | | LVOT VEL. (m/s) | RVOT VEL. (m/s) | IVRT (m/) |
| NORMAL PARAMETER | <1.5 | 1.6 | 0.7-1.7 | | <1.6 | <1.3 | 40-60 |
| PATIENT | 1.51 | 1.27 | 1.33 | | NM | 1.2 | NM |
| Adapted from June Boon, Veterinary Echocardiography, 1998 Sisson D et al. JVIM 1991; 5: 232, Jacobs et al. Am J Vet Res 1985; 46:1705 | | | | | | | |

Cardiac Presentation

The left atrium is normal in dimension. There are no distinct left atrial thrombi/clots or spontaneous echo contrast appreciated. The left ventricle is normal in dimension as well as wall thickness, and no evidence of restriction. Left ventricular systolic function is normal, with adequate contractility based on fractional shortening and systolic left ventricular dimensions. The right atrium and ventricle are subjectively normal in dimension and systolic function. The anterior and posterior mitral and tricuspid valve leaflets presented normal linear structure, extension in systole, and union in diastole without regurgitation. There is no evidence of systolic anterior mitral valve motion documented. The left ventricular outflow tract demonstrated normal laminar flow and subjective structural valvular integrity. The visible aorta is unremarkable. Pulmonary outflow tract assessment revealed normal valve structure, laminar flow, and appropriate diameter and distensibility. There is no evidence of pulmonary hypertension documented. There is no visible pericardial, pleural, or free peritoneal fluid noted.

ULTRASONOGRAPHIC FINDINGS



PATIENT

Ninja Kitty Nardone

SPECIES

Feline

BREED

DSH

SEX

Spayed Female

AGE

15 Years

WEIGHT

4.9 kg

INTERPRETED BY

Bradley Harris, DVM,
DACVECC, DACVIM
(Cardiology)

IMAGING PERFORMED BY

Dr. Ethan Bloomer

HOSPITAL NAME

Echosound Veterinary
Mobile Imaging
Services

REFERRING VET

Dr. Binzer

INVOICE

13518

DATE

01/31/26

- These findings are consistent with an essentially normal echocardiogram. The presence of an elevated BNP is often associated with underlying heart disease but can be seen in animals without heart disease. In addition, changes on chest X-rays can occur without significant underlying disease. The absence of any abnormalities on the echo excludes any meaningful cardiac disease at this time. Any murmur will be considered functional in origin at this time.

INTERPRETATION OF THE FINDINGS & FURTHER RECOMMENDATIONS

Given these findings, no cardiac therapy is recommended. There are no cardiac contraindications to corticosteroids or fluid therapy as indicated for further treatment. No specific recheck echocardiogram is recommended.

Anesthesia considerations:

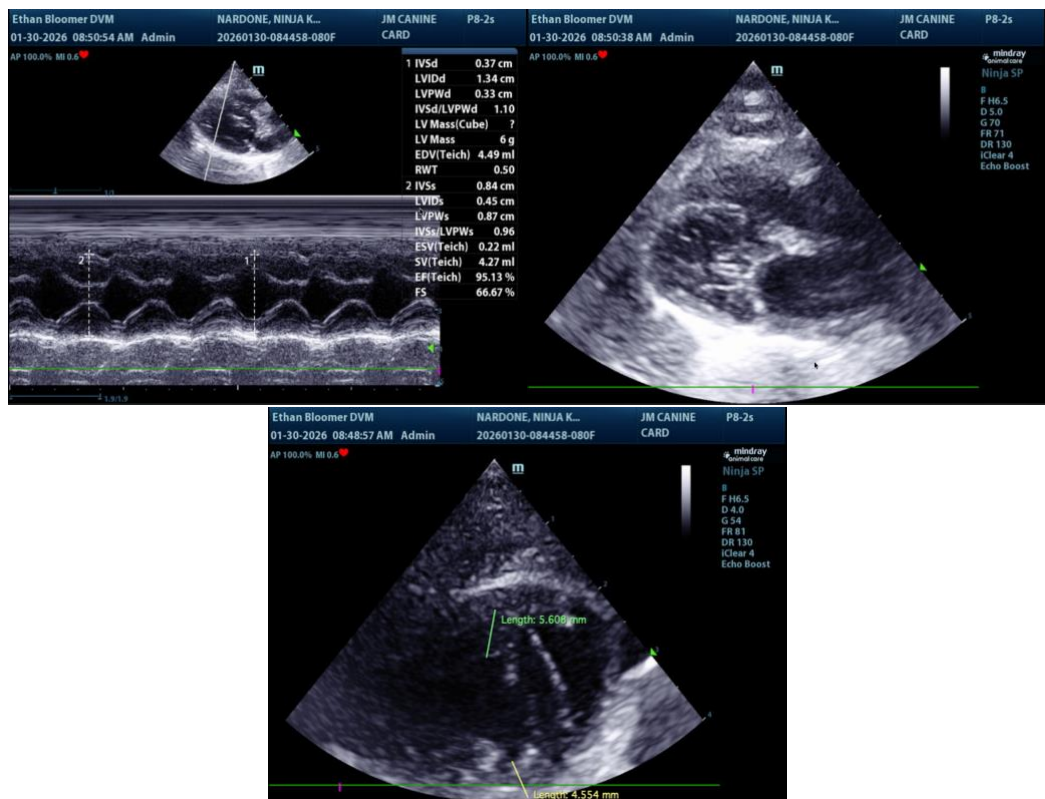
No special cardiac considerations are necessary

Diet:

No special considerations are necessary. Any high-quality food from Hills, Royal Canin, Science Diet, Eukanuba, Iams, or Purina is reasonable.

Activity:

No special considerations are necessary.



The information and recommendations provided are based on the images presented by the referring



PATIENT

Ninja Kitty Nardone

SPECIES

Feline

BREED

DSH

SEX

Spayed Female

AGE

15 Years

WEIGHT

4.9 kg

INTERPRETED BY

Bradley Harris, DVM,
DACVECC, DACVIM
(Cardiology)

IMAGING PERFORMED BY

Dr. Ethan Bloomer

HOSPITAL NAME

Echosound Veterinary
Mobile Imaging
Services

REFERRING VET

Dr. Binzer

INVOICE

13518

DATE

01/31/26

veterinarian/sonographer. No evaluation can be communicated regarding pathology that was not visible in the image/video clips provided.

Thank you for this referral. If the clinical or image interpretation does not parallel your findings or if I can be of any further assistance please contact me.

Bradley Harris, DVM, DACVECC, DACVIM (Cardiology)

info@SonoPath.com