



PATIENT

Jett Fonalik

SPECIES

Canine

BREED

Doberman

SEX

Male

AGE

4 years 8 months

WEIGHT

38 kg

INTERPRETED BY

Bradley Harris, DVM,
DACVECC, DACVIM
(cardiology)

IMAGING PERFORMED BY

Dr. Mariusz
Chmielinski

HOSPITAL NAME

Apex Veterinary
Services Ltd.

REFERRING VET

Lake Bonavista AC/Dr.
Erin O'Brien

INVOICE

11223

DATE

1/30/2026

PRESENTING CLINICAL SIGNS

- Preanesthetic work up - Historical low grade heart murmur. no other concerns.

Abnormal PE/Chem/CBC/UA Results: Vital Signs: Temperature [Celsius]:38.0, Heart Rate/min (HR):104, HR: Pulse Ratio: 1:1, Respiratory Rate/ min: 26, Respiratory Effort: 0, Mucus Membranes/ CRT: pink, moist/ CRT< 2 sec ,Mentation: BAR ,Hydration: Adequate , BCS (scale 1 to 5): 3.5/5, Grade 1/6 systolic heart murmur.

ULTRASONOGRAPHIC EXAMINATION OF THE HEART

CANINE CARDIAC PARAMETERS	BW	HR BPM	LAD 4 ch Long	RAD 4 ch Long	La/Ao Heart Base	LVIDd	LVIDs
NORMAL PARAMETER		50-100			<1.6		
PATIENT	38 kg	NM	4.33	3.33	1.11	4.22	2.90
CANINE CARDIAC PARAMETERS	FS	EPSS	PV V MAX (m/s)	AV V Max (m/sec)	MR Vmax	TR Vmax	RPA distensibility (normal >30%)
NORMAL PARAMETER	28-40	<0.6	0.7-1.6	0.7-1.7	4.5-5.5	< 2.7	
PATIENT	31	0.1	1.1	1.7	NM	NM	NM

Cardiac Presentation

The left atrium is normal in dimension. The left ventricle is normal in dimension, with normal systolic function. The right atrium and ventricle are normal in dimension, with normal systolic function. The anterior and posterior mitral valve leaflets are appropriately thin with adequate apposition, intact chordae, and no prolapse. There is no significant mitral regurgitation identified. The tricuspid valve leaflets are appropriately thin with adequate apposition, intact chordae, no significant tricuspid regurgitation and no evidence of pulmonary hypertension. The left ventricular outflow tract demonstrated normal laminar flow and the visible aorta is unremarkable. The right ventricular outflow tract assessment revealed normal laminar flow, and appropriate diameter and distensibility. There is Mild pulmonic and no aortic valve insufficiency identified. There is no visible pericardial, pleural, or free peritoneal fluid documented. No evidence of hepatic venous congestion is noted. The cardiac chambers, pericardial and visible extra-cardiac regions were free of masses, spontaneous echo contrast, or thrombi.

ULTRASONOGRAPHIC FINDINGS

- These findings are consistent with an essentially normal echocardiogram. Any murmur will be considered functional in origin. No cardiac cause of the morbidity is identified.

INTERPRETATION OF THE FINDINGS & FURTHER RECOMMENDATIONS



PATIENT

Jett Fonalik

Given these findings, no cardiac therapy is recommended. There are no cardiac contraindications to fluid therapy or corticosteroid therapy, as indicated for further assessment and treatment. No specific cardiac recheck is recommended unless a murmur or clinical signs of heart disease develop.

SPECIES

Canine

Anesthesia considerations:

No special considerations are necessary.

BREED

Doberman

Diet:

No special considerations are necessary. Any high-quality food from Hills, Royal Canin, Science Diet, Eukanuba, Iams, or Purina is reasonable.

SEX

Male

Activity:

No special considerations are necessary.

AGE

4 years 8 months

WEIGHT

38 kg

INTERPRETED BY

Bradley Harris, DVM,
DACVECC, DACVIM
(cardiology)

IMAGING PERFORMED BY

Dr. Mariusz
Chmielinski

HOSPITAL NAME

Apex Veterinary
Services Ltd.

REFERRING VET

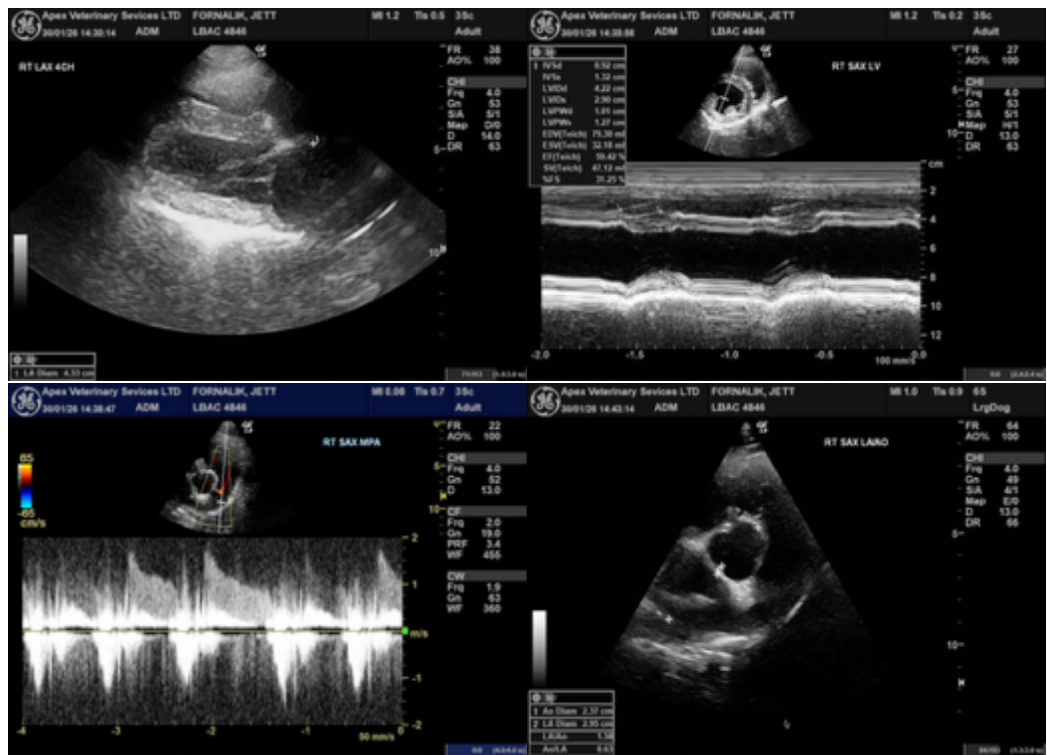
Lake Bonavista AC/Dr.
Erin O'Brien

INVOICE

11223

DATE

1/30/2026



The information and recommendations provided are based on the images presented by the referring veterinarian/sonographer. No evaluation can be communicated regarding pathology that was not visible in the image/video clips provided.

Thank you for this referral. If the clinical or image interpretation does not parallel your findings or if I can be of any further assistance please contact me.

Bradley Harris, DVM, DACVECC, DACVIM (cardiology)

info@SonoPath.com