



**PATIENT**

Pigeon Sautter

**SPECIES**

Feline

**BREED**

Devon Rex

**SEX**

Neutered Male

**AGE**

16 Years

**WEIGHT**

5.2 lbs

**INTERPRETED BY**

Brad Harris, DVM,  
DACVECC, DACVIM  
(cardiology)

**IMAGING PERFORMED BY**

Meghan Morse, LVT,  
CVT

**HOSPITAL NAME**

Bergen County  
Veterinary Center

**REFERRING VET**

Dr. Santo

**INVOICE**

73664

**DATE**

3/13/26

**PRESENTING CLINICAL SIGNS**

Bleeding of UNK origin, suspect rodent ulcer. Progressive non regenerative anemia. Current meds: Prednisolone 5mg (had one dose)

Abnormal PE/Chem/CBC/UA Results: 1/28/26: Creat 0.4, Glob 5.2, HCT 33 3/11/26: HCT 21, Pt/ptt WNL, snap proBNP normal 3/12/26: PCV 18, TP 6.2

**ULTRASONOGRAPHIC EXAMINATION OF THE ABDOMEN**

**Urinary System**

The urinary bladder, trigone, and pelvic urethra are unremarkable with normal wall thicknesses and normal tone. The ureters were not visualized, which is a normal finding. The bladder contains a moderate to severe amount of suspended echogenic mobile debris within otherwise anechoic urine. The ureteral papillae appear normal.

The kidneys are normal in size. Cortices are hyperechoic with a loss of corticomedullary distinction. Normal cortex to medulla ratio. No pyelectasis or pelvic dilation. Renal capsules are minimally irregular bilaterally. Left kidney measured 3.91 cm. Right kidney measured 4.16 cm.

**Adrenal Glands**

Both adrenal glands are visualized and have normal shape, size, position and echogenicity for this breed. The phrenic vasculature, glandular echogenicity and detail were unremarkable. Capsule, cortex, and medullary definition were normal for this age patient. Left measures 0.46 cm. Right measures 0.50 cm.

**Spleen**

The spleen measures 0.54 cm at the hilus. It is smooth with homogeneous parenchyma and hyperechoic to liver and renal cortical parenchyma. The capsule is without noticeable irregularity or deformation. The splenic vasculature is normal without signs of congestion, spontaneous echo contrast, or thrombosis. No evidence of acute or chronic inflammatory, neoplastic, or infarct are documented.

**Liver**

The liver is enlarged with a diffusely heterogeneous or mottled parenchymal pattern. There are mixed hyper- and hypoechoic ill-defined nodular to mass-like changes within the parenchyma that do not readily distort the otherwise smooth hepatic capsule. The gallbladder appears normal.

**Gastrointestinal**

The stomach and intestines are free of stasis and peristaltic activity, with no significant dilation noted. There is normal wall thickness and acceptable curvilinear mural detail. The pyloric-duodenal junction and ileocecolic junction are patent, and the colon contains normal shadowing feces. There is no evidence of shadowing obstructive material or overt infiltrative disease noted. No associated abnormal lymphatic activity is documented.

**Pancreas**

The pancreas is hypoechoic with irregular margins and mixed hyper- and hypoechoic nodular changes.



**PATIENT**

Pigeon Sautter

**SPECIES**

Feline

**BREED**

Devon Rex

**SEX**

Neutered Male

**AGE**

16 Years

**WEIGHT**

5.2 lbs

**INTERPRETED BY**

Brad Harris, DVM,  
DACVECC, DACVIM  
(cardiology)

**IMAGING PERFORMED BY**

Meghan Morse, LVT,  
CVT

**HOSPITAL NAME**

Bergen County  
Veterinary Center

**REFERRING VET**

Dr. Santo

**INVOICE**

73664

**DATE**

3/13/26

**Free Abdomen**

No overt lymphadenopathy or peritoneal effusion was present.

**ULTRASONOGRAPHIC FINDINGS**

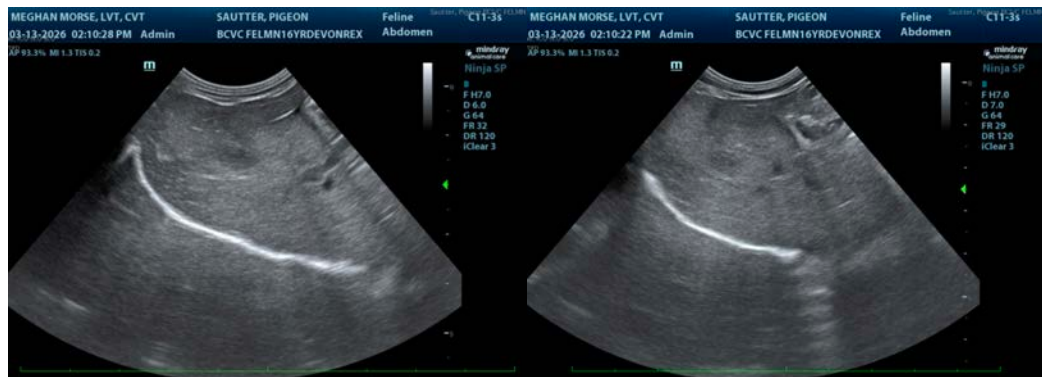
- The urinary bladder contains echogenic, suspended debris contrasted with anechoic urine. This is often related to urinary tract infection but may represent exfoliated debris or sterile inflammation.
- The kidneys are relatively normal in size and structure, and cortex:medulla ratio (cortex 1/3 of medulla) is essentially maintained. There is age-related loss of the normal smooth capsular contour and C/M junction definition. The cortices are largely uniform in texture with mild hyperechogenicity expected for this patient's age. There is no evidence of pelvic dilation present.
- The diffuse heterogeneous liver with ill-defined nodules and mass effects likely represents infiltrative neoplastic disease such as round cell neoplasia. A chronic active hepatitis or cholangiohepatitis cannot be definitively excluded.
- The prominent, hypoechoic pancreas with an irregular contour and mixed ill-defined hyper and hypoechoic changes is most consistent with pancreatic remodeling and nodular hyperplasia. This may be secondary to active or acute-on chronic inflammatory disease or pancreatitis.

**INTERPRETATION OF THE FINDINGS & FURTHER RECOMMENDATIONS**

Urinalysis and, if indicated based on urinalysis results, urine culture is recommended. If protein is present in an otherwise quiet sediment, protein quantification with a urine protein to creatinine ration is recommended.

Fine needle aspirates of the liver with cytology are recommended. A coagulation profile and platelet estimate prior to sampling are indicated to ensure the absence of coagulopathy. Occasionally some tissues are poorly exfoliative, or cytology is non-specific, in which case biopsy with histopathology may be required for a definitive diagnosis.

A spec fPLI is recommended to further evaluate the pancreas for active inflammation or pancreatitis.





**PATIENT**

Pigeon Sautter

**SPECIES**

Feline

**BREED**

Devon Rex

**SEX**

Neutered Male

**AGE**

16 Years

**WEIGHT**

5.2 lbs

**INTERPRETED BY**

Brad Harris, DVM,  
DACVECC, DACVIM  
(cardiology)

**IMAGING PERFORMED BY**

Meghan Morse, LVT,  
CVT

**HOSPITAL NAME**

Bergen County  
Veterinary Center

**REFERRING VET**

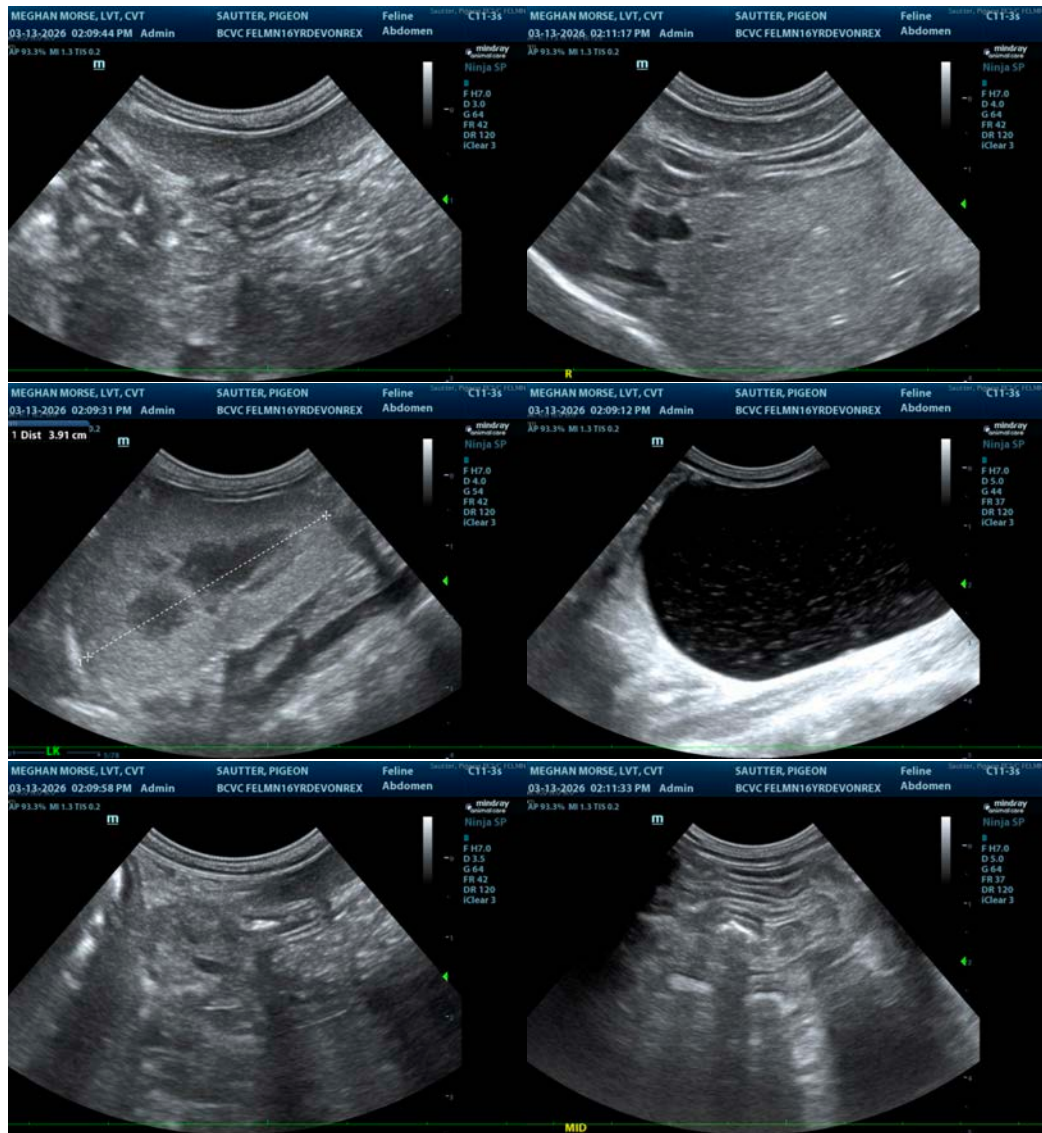
Dr. Santo

**INVOICE**

73664

**DATE**

3/13/26



The information and recommendations provided are based on the images presented by the referring veterinarian/sonographer. No evaluation can be communicated regarding pathology that was not visible in the image/video clips provided.

Thank you for this referral. If the clinical or image interpretation does not parallel your findings or if I can be of any further assistance please contact me.

**Brad Harris, DVM, DACVECC, DACVIM (cardiology)**

[info@SonoPath.com](mailto:info@SonoPath.com)