



PATIENT

Nutmeg Zecca

SPECIES

Feline

BREED

DSH

SEX

MN

AGE

6 months

WEIGHT

7 lbs

INTERPRETED BY

Bradley Harris, DVM,
DACVECC, DACVIM
(cardiology)

IMAGING PERFORMED BY

Kerri Becker

HOSPITAL NAME

Marsh AH

REFERRING VET

Dr. Armani

INVOICE

10890

DATE

12/8/2025

PRESENTING CLINICAL SIGNS

Newly adopted a month ago- no murmur auscultated- now on recheck - note cardiac murmur grade 3. Elevated pro bnp.

Abnormal PE/Chem/CBC/UA Results: Pro bnp-324.

ULTRASONOGRAPHIC EXAMINATION OF THE HEART

FELINE CARDIAC PARAMETERS	BODY WEIGHT (kg)	HR (BPM)	IVSd (cm)	LVIDd (cm)	LVWd (cm)	FS (%)	EF (%)
NORMAL PARAMETER	-----	150-240	0.3-0.6	1.0-2.1	0.25-0.6	35-67	80-100
PATIENT	3.18 kg	NM	0.43	1.66	0.52	54%	NM
FELINE CARDIAC PARAMETERS	LA/AO (M-mode)	LA/AO HEART BASE (Sisson)	LAD LA MAX 4 Chamber		LVOT VEL. (m/s)	RVOT VEL. (m/s)	IVRT (m/)
NORMAL PARAMETER	<1.5	1.6	0.7-1.7		<1.6	<1.3	40-60
PATIENT	1.11	1.18	1.46		NM	0.9	NM
Adapted from June Boon, Veterinary Echocardiography, 1998 Sisson D et al. JVIM 1991; 5: 232, Jacobs et al. Am J Vet Res 1985; 46:1705							

Cardiac Presentation

The left atrium is normal in dimension. There are no distinct left atrial thrombi/clots or spontaneous echo contrast appreciated. The left ventricle is normal in dimension as well as wall thickness, and no evidence of restriction. Left ventricular systolic function is normal, with adequate contractility based on fractional shortening and systolic left ventricular dimensions. The right atrium and ventricle are subjectively normal in dimension and systolic function. There is evidence of systolic anterior motion of the mitral valve with mild to moderate mitral regurgitation. The tricuspid valve leaflets presented normal linear structure, extension in systole, and union in diastole without regurgitation. The left ventricular outflow tract demonstrated turbulent flow and subjective structural valvular integrity. The visible aorta is unremarkable. Pulmonary outflow tract assessment revealed normal valve structure, laminar flow, and appropriate diameter and distensibility. There is no evidence of semilunar valve insufficiency or pulmonary hypertension documented. There is no visible pericardial, pleural, or free peritoneal fluid noted.

ULTRASONOGRAPHIC EXAMINATION OF THE ABDOMEN

Urinary System

The urinary bladder, trigone, and pelvic urethra are unremarkable with normal wall thicknesses and normal tone. The ureters were not visualized, which is a normal finding. There are no uroliths or



PATIENT

Nutmeg Zecca

SPECIES

Feline

BREED

DSH

SEX

MN

AGE

6 months

WEIGHT

7 lbs

INTERPRETED BY

Bradley Harris, DVM,
DACVECC, DACVIM
(cardiology)

IMAGING PERFORMED BY

Kerri Becker

HOSPITAL NAME

Marsh AH

REFERRING VET

Dr. Armani

INVOICE

10890

DATE

12/8/2025

sediment noted, and anechoic urine is present. The ureteral papillae appear normal. There is no evidence of inflammatory, infiltrative, or neoplastic disease.

The kidneys are normal in size and structure, with appropriate corticomedullary definition and cortex to medulla ratio. The cortices are uniform in texture with normal echogenic relationship to liver and spleen. The medullary structure differed distinctly from the cortex and no evidence of pyelectasis is present. The capsules are uniform without significant irregularities noted. Left kidney measures 3.75 cm, and the right kidney measures 3.64 cm.

Adrenal Glands

Both adrenal glands are visualized and have normal shape, size, position and echogenicity for this breed. The phrenic vasculature, glandular echogenicity and detail were unremarkable. Capsule, cortex, and medullary definition were normal for this age patient. Left adrenal measures 0.4 cm, and the right adrenal measures 0.3 cm.

Spleen

The spleen is smooth with homogeneous parenchyma and hyperechoic to liver and renal cortical parenchyma. The capsule is without noticeable irregularity or deformation. The splenic vasculature is normal without signs of congestion, spontaneous echo contrast, or thrombosis. No evidence of acute or chronic inflammatory, neoplastic, or infarct are documented. The spleen measures 0.84 cm at the hilus.

Liver

The liver is subjectively normal liver size, contour, and structure. Parenchymal echogenicity is naturally coarse and hypoechoic to the spleen. Vasculature is within normal limits with no evidence of congestion. The gallbladder has thin walls which contain anechoic bile. There is no evidence of intra- or extra-hepatic biliary dilation. The cystic and common bile ducts were normal. No hepatic lymphadenopathy is documented. There is no overt structural evidence of inflammatory, infiltrative or regenerative pathology evident.

Gastrointestinal

The stomach contains a moderate amount of echogenic shadowing contents that likely represents normal ingesta, however, this should be correlated with most recent meal. There's no overt pyloric outflow obstruction. The small intestine is also multifocally distended with echogenic contents consistent with normal ingesta. The gastrointestinal walls are normal in thickness with maintenance of normal wall layering. The colon contains normal shadowing feces.

Pancreas

The base and limbs of the pancreas are isoechoic to surrounding omental fat. The pancreatic duct and capsular contour are normal. There is no overt evidence of active inflammatory or neoplastic disease.

Free Abdomen

There are several prominent mesenteric and jejunal lymph nodes with normal length to width ratio, and isoechoic parenchyma. There's no free fluid noted.

ULTRASONOGRAPHIC FINDINGS



PATIENT

Nutmeg Zecca

SPECIES

Feline

BREED

DSH

SEX

MN

AGE

6 months

WEIGHT

7 lbs

INTERPRETED BY

Bradley Harris, DVM,
 DACVECC, DACVIM
 (cardiology)

IMAGING PERFORMED BY

Kerri Becker

HOSPITAL NAME

Marsh AH

REFERRING VET

Dr. Armani

INVOICE

10890

DATE

12/8/2025

- These findings are consistent with dynamic subaortic stenosis, as there is SAM present, but no convincing hypertrophy is identified. It is unlikely that any of the clinical/radiographic signs are related to underlying heart disease.
- Normal gastrointestinal ingesta is suspected, however, foreign material can't be definitively excluded. Correlate with recent meal.
- The slightly prominent mesenteric and jejunal lymph nodes display no loss of parenchymal detail or change in echogenicity. This is most consistent with reactive lymphadenitis or lymphatic hyperplasia.

INTERPRETATION OF THE FINDINGS & FURTHER RECOMMENDATIONS

Given the absence of any underlying heart disease, no cardiac therapy will be recommended. In addition, there are no cardiac objections to fluid therapy or steroid use. Owing to the presence of an outflow tract obstruction, a follow up echo is recommended in another 6-12 months to make sure no progression has occurred.

Anesthesia considerations:

If anesthesia is necessary, then alpha-2 agonists, ketamine, high dose acepromazine, and Telazol should be avoided. Fluid therapy during anesthesia should be considered at a reduced rate (e.g., 5 ml/kg/hour) if possible (i.e., if not hypotensive). A shorter anesthetic duration will reduce the risk of complications. Pre-oxygenation is advised. Premedication with an opioid (i.e., butorphanol, hydromorphone, oxymorphone) with or without a benzodiazepine is generally the safest protocol. An induction agent such as Propofol, alfaxalone can be used to effect. Maintenance of anesthesia with isoflurane or sevoflurane is reasonable.

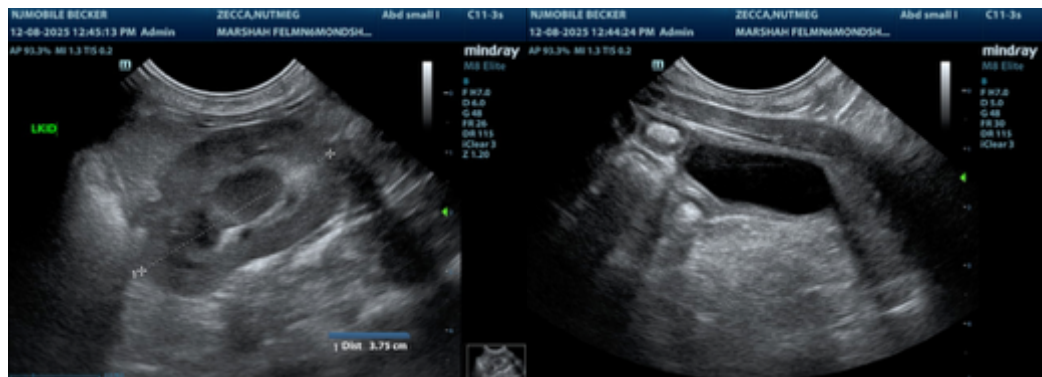Diet:

No special considerations are necessary. Any high-quality food from Hills, Royal Canin, Science Diet, Eukanuba, Iams, or Purina is reasonable.

Activity:

No special considerations are necessary.

If there is concern for ingestion of gastrointestinal foreign material, consider fasting and repeat imaging after 12-24 hour fast.





PATIENT

Nutmeg Zecca

SPECIES

Feline

BREED

DSH

SEX

MIN

AGE

6 months

WEIGHT

7 lbs

INTERPRETED BY

Bradley Harris, DVM,
 DACVECC, DACVIM
 (cardiology)

IMAGING PERFORMED BY

Kerri Becker

HOSPITAL NAME

Marsh AH

REFERRING VET

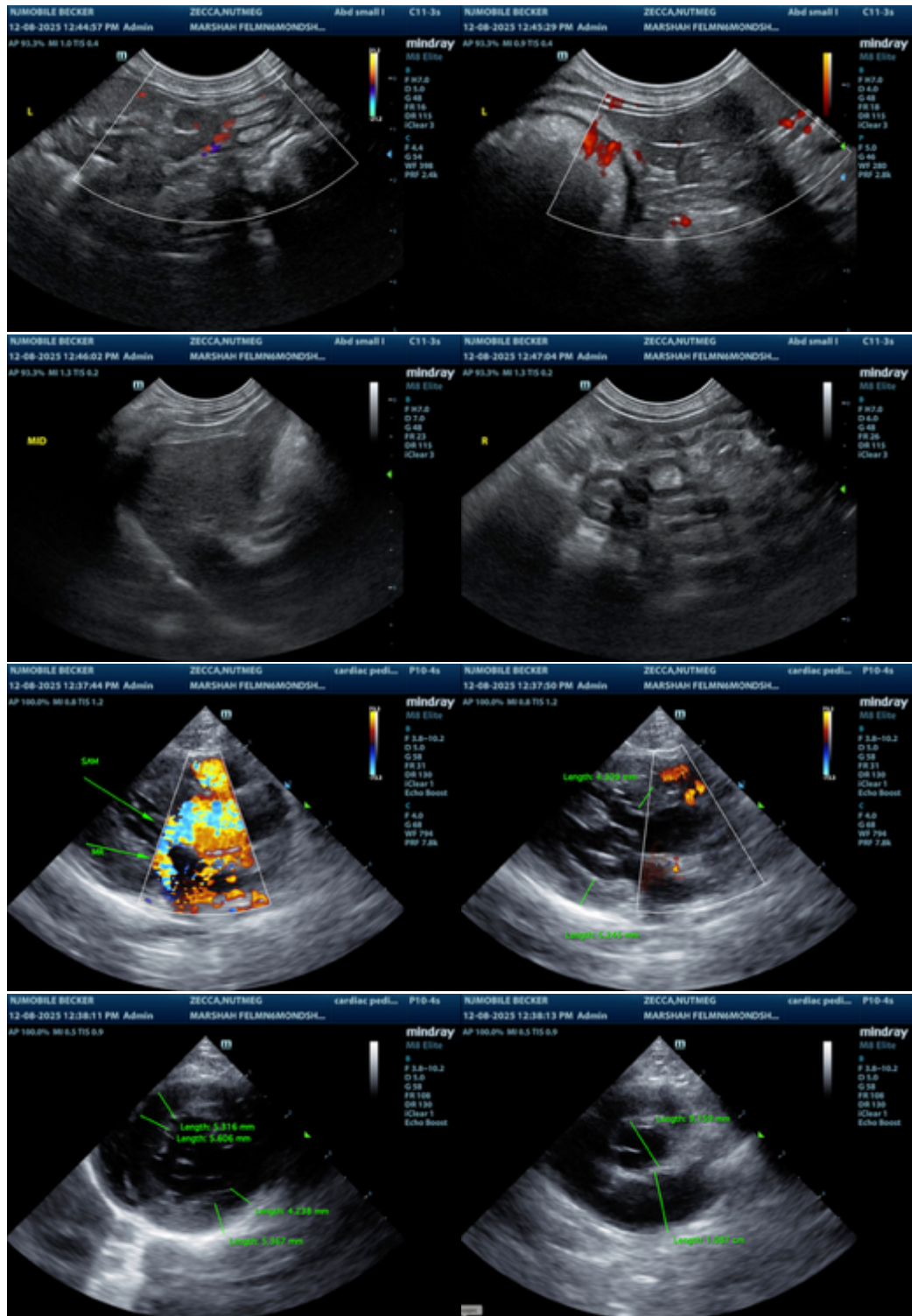
Dr. Armani

INVOICE

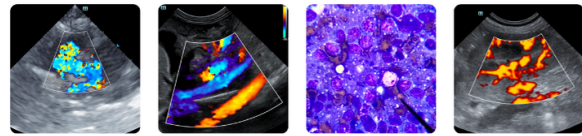
10890

DATE

12/8/2025



The information and recommendations provided are based on the images presented by the referring veterinarian/sonographer. No evaluation can be communicated regarding pathology that was not



PATIENT

Nutmeg Zecca

SPECIES

Feline

BREED

DSH

SEX

MN

AGE

6 months

WEIGHT

7 lbs

INTERPRETED BY

Bradley Harris, DVM,
DACVECC, DACVIM
(cardiology)

**IMAGING
PERFORMED BY**

Kerri Becker

HOSPITAL NAME

Marsh AH

REFERRING VET

Dr. Armani

INVOICE

10890

DATE

12/8/2025

visible in the image/video clips provided.

Thank you for this referral. If the clinical or image interpretation does not parallel your findings or if I can be of any further assistance please contact me.

Bradley Harris, DVM, DACVECC, DACVIM (cardiology)

info@SonoPath.com