



## PATIENT

Daisy Petcella

## SPECIES

Feline

## BREED

DSH

## SEX

Spayed Female

## AGE

1 Year

## WEIGHT

4.3 kg

## INTERPRETED BY

Brad Harris, DVM,  
DACVECC, DACVIM  
(cardiology)

## IMAGING PERFORMED BY

Renee Trionfetti, VMD

## HOSPITAL NAME

Blue Pearl Wyomissing

## REFERRING VET

Blue Pearl Wyomissing

## INVOICE

72855

## DATE

12/29/25

## PRESENTING CLINICAL SIGNS

AUS to further evaluate severe septic shock of unknown origin. Hypoglycemic (BG 25 --> 35 after Dextrose bolus), hypotensive, lateral, hypothermic, 8-10% dehydrated. Azotemic, severe neutropenia, panleukopenia, hyperphosphatemia, severe metabolic acidosis and hyperlactatemia, hypoalbuminemic. Now febrile. Reported to have started vomiting (green liquid) 1-2 days ago and 12/28 in the AM developed septic shock. Reported to have been on Prednisolone recently (unknown why, poss for recent fleas). Hosp management: LRS, 5% dextrose supplementation weaned to 2.5%, unasyn, baytril, Norepinephrine CRI, cerenia - Parvo/panluek: negative - FeLV/FIV Neg x2

Abnormal PE/Chem/CBC/UA Results: 12/28-12/29: CBC: Hct 58.7 -> 40.8%, WBC 0.39k ->0.8, Neut 0.06k ->0.17, PLT 90k ->77 L, Lymph0.55 L, Eos 0.03L PCV/TS: 58/9-> 42%/5 Chem: Cr 2.4 ->1.0, BUN 58.1, Glu 148, Phos >15-> 3.3, Tbili 1.7 ->2.1H, GLob 3.9, Alb 1.8L, ALT 119 H EPOC: pH 6.917 ->7.02->7.34, Bicarb 14.5->16, iCal 1.21, Cl 112, Cr 4.12->1.3, BUN 47->18, Glu 69, K 7.1->3.5, Na 146->144, Lac 15.81->3.95 Rads: Rt mid lung lobe alveolar pattern - recumbency related atelectasis, collapse 2nd to bronchial mucus plugging or less likely infectious pna. Non-obs tiny mineral foci in stomach. GIT changes include mod gastric distension, mild SI distension, fluid & gas in the colon (impending diarrhea) are more consistent w/ GE than obstruction. Mild inguinal lymphadenopathy is likely reactive, less likely multicentric/metastatic.

## ULTRASONOGRAPHIC EXAMINATION OF THE ABDOMEN

### Urinary System

The urinary bladder, trigone, and pelvic urethra are unremarkable with normal wall thicknesses and normal tone. The ureters were not visualized, which is a normal finding. There is a mild amount of suspended mobile echogenic debris. The ureteral papillae appear normal. There is no evidence of inflammatory, infiltrative, or neoplastic disease.

The kidneys are normal in size and structure, with appropriate corticomedullary definition and cortex to medulla ratio. The cortices are uniform in texture with normal echogenic relationship to liver and spleen. The medullary structure differed distinctly from the cortex and no evidence of pyelectasis is present. The capsules are uniform without significant irregularities noted. Left measures 4.26 cm. Right measures 4.21 cm.

### Adrenal Glands

Both adrenal glands are visualized and have normal shape, size, position and echogenicity for this breed. The phrenic vasculature, glandular echogenicity and detail were unremarkable. Capsule, cortex, and medullary definition were normal for this age patient. Left measures 0.47 cm. Right measures 0.48 cm.

### Spleen

The spleen measures 0.75 cm at the hilus. It is smooth with homogeneous parenchyma and hyperechoic to liver and renal cortical parenchyma. The capsule is without noticeable irregularity or deformation. The splenic vasculature is normal without signs of congestion, spontaneous echo contrast, or thrombosis. No evidence of acute or chronic inflammatory, neoplastic, or infarct are documented.

### Liver

The liver is subjectively normal liver size, contour, and structure. Parenchymal echogenicity is naturally coarse and hypoechoic to the spleen. Vasculature is within normal limits with no evidence of congestion.



## PATIENT

Daisy Petcella

## SPECIES

Feline

## BREED

DSH

## SEX

Spayed Female

## AGE

1 Year

## WEIGHT

4.3 kg

## INTERPRETED BY

Brad Harris, DVM,  
DACVECC, DACVIM  
(cardiology)

## IMAGING PERFORMED BY

Renee Trionfetti, VMD

## HOSPITAL NAME

Blue Pearl Wyomissing

## REFERRING VET

Blue Pearl Wyomissing

## INVOICE

72855

## DATE

12/29/25

The gallbladder has thin walls which contain anechoic bile. There is no evidence of intra- or extra-hepatic biliary dilation. The cystic and common bile ducts were normal. No hepatic lymphadenopathy is documented. There is no overt structural evidence of inflammatory, infiltrative or regenerative pathology evident.

### ***Gastrointestinal***

The stomach is moderately to severely distended with echogenic contents. There is a mild amount of apparently shadowing contents within the fundus. The pylorus appears patent. There is no overt evidence of pyloric outflow obstruction. The small intestine is diffusely distended with echogenic fluid that has a mild to-fro motion, most consistent with ileus. There is no evidence of small intestinal shadowing material or a mechanical obstruction. However, given the degree of dilation, this cannot be completely excluded. The ileoceocolic junction is patent, and the colon also contains echogenic diarrhea feces.

### ***Pancreas***

The pancreas is severely enlarged with irregular margins and a hypoechoic parenchyma with mixed hyper- and hypoechoic nodular changes. The pancreatic duct is mildly to moderately dilated, and there is moderate to severe hyperechoic mesentery or omental fat consistent with steatitis. There are mildly prominent mesenteric lymph nodes with a normal length to width ratio and isoechoic parenchyma. There is no overt free peritoneal effusion noted.

### **ULTRASONOGRAPHIC FINDINGS**

- The urinary bladder contains echogenic, suspended debris contrasted with anechoic urine. This is often related to urinary tract infection but may represent exfoliated debris or sterile inflammation.
- There are areas of minor gastrointestinal luminal fluid noted with echogenic contents and a to-fro motion consistent with ileus. There was no evidence of an obstructive pattern, and normal wall thickness and layering is retained throughout the gastrointestinal tract. This is a consistent response to irritation or inflammation. Gastroenteritis or pancreatitis should be considered.
- The prominent, hypoechoic pancreas with an irregular contour and mixed ill-defined hyper and hypoechoic changes is most consistent with pancreatic remodeling and nodular hyperplasia. This may be secondary to active or acute-on chronic inflammatory disease or pancreatitis.
- The slightly prominent mesenteric lymph nodes display no loss of parenchymal detail or change in echogenicity. This is most consistent with reactive lymphadenitis or lymphatic hyperplasia.
- While there is no mechanical small intestinal obstruction suspected based on this study, it cannot be completely excluded, given the degree of small intestinal dilation and shadowing contents within the stomach.

### **INTERPRETATION OF THE FINDINGS & FURTHER RECOMMENDATIONS**

Continued supportive care for suspected pancreatitis with secondary functional ileus is recommended at this time. Serial imaging and close clinical monitoring of the patient is necessary, as occult small intestinal mechanical obstruction can't be definitively excluded.



**PATIENT**

Daisy Petcella

**SPECIES**

Feline

**BREED**

DSH

**SEX**

Spayed Female

**AGE**

1 Year

**WEIGHT**

4.3 kg

**INTERPRETED BY**

Brad Harris, DVM,  
DACVECC, DACVIM  
(cardiology)

**IMAGING PERFORMED BY**

Renee Trionfetti, VMD

**HOSPITAL NAME**

Blue Pearl Wyomissing

**REFERRING VET**

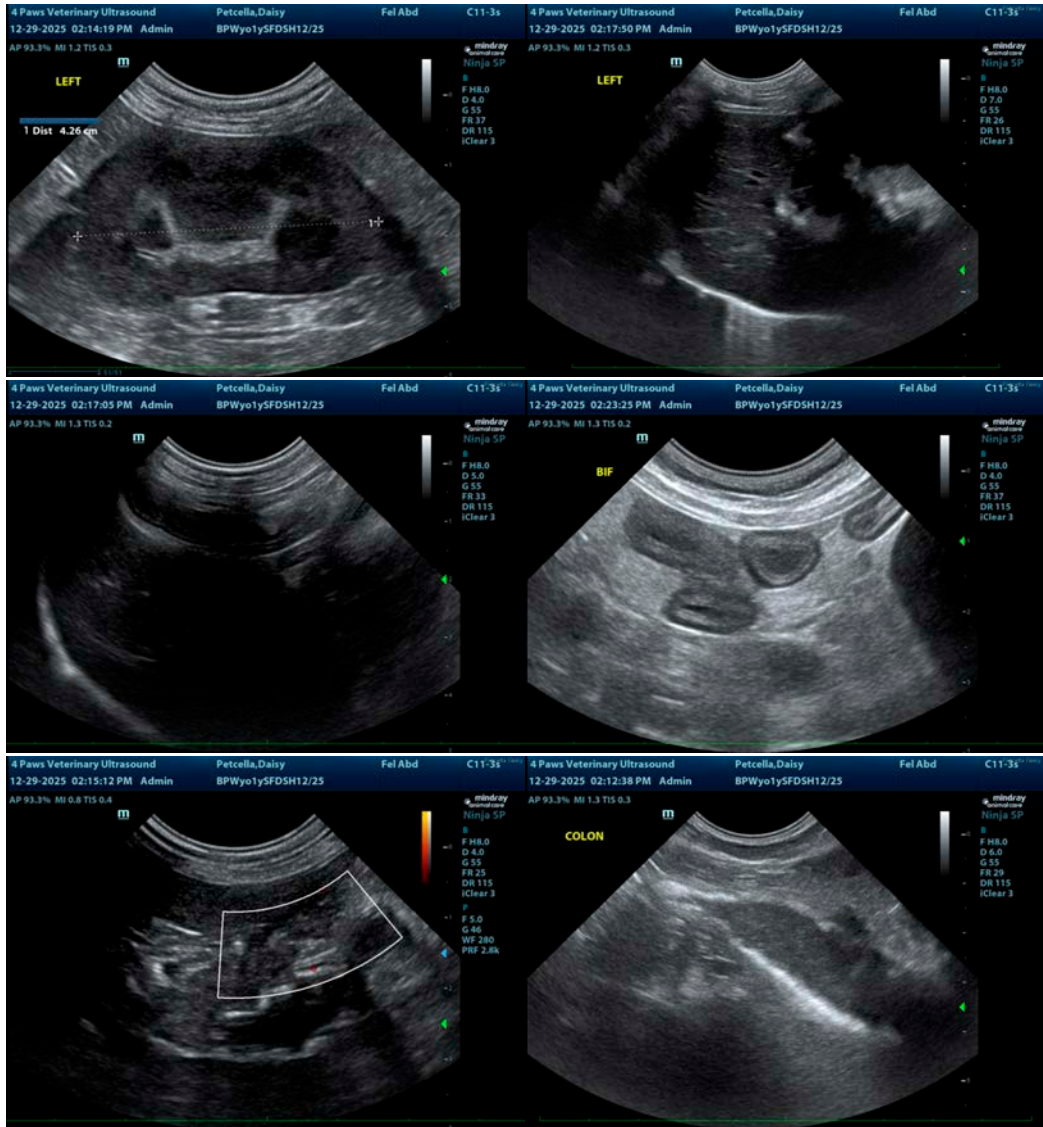Blue Pearl Wyomissing

**INVOICE**

72855

**DATE**

12/29/25





## PATIENT

Daisy Petcella

## SPECIES

Feline

## BREED

DSH

## SEX

Spayed Female

## AGE

1 Year

## WEIGHT

4.3 kg

## INTERPRETED BY

Brad Harris, DVM,  
DACVECC, DACVIM  
(cardiology)

## IMAGING PERFORMED BY

Renee Trionfetti, VMD

## HOSPITAL NAME

Blue Pearl Wyomissing

## REFERRING VET

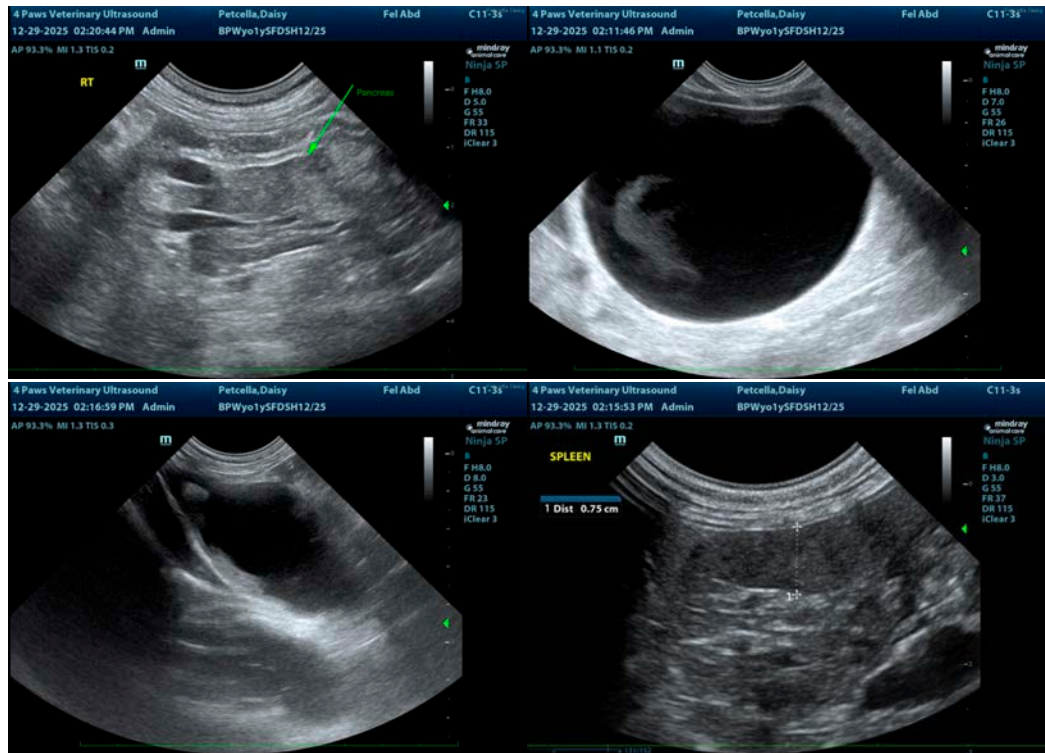
Blue Pearl Wyomissing

## INVOICE

72855

## DATE

12/29/25



The information and recommendations provided are based on the images presented by the referring veterinarian/sonographer. No evaluation can be communicated regarding pathology that was not visible in the image/video clips provided.

Thank you for this referral. If the clinical or image interpretation does not parallel your findings or if I can be of any further assistance please contact me.

**Brad Harris, DVM, DACVECC, DACVIM (cardiology)**

[info@SonoPath.com](mailto:info@SonoPath.com)