



## PATIENT

Tula Cami

## SPECIES

Feline

## BREED

DSH

## SEX

Spayed Female

## AGE

14 Years

## WEIGHT

7.7 lbs

## INTERPRETED BY

Brad Harris, DVM,  
DACVECC, DACVIM  
(cardiology)

## IMAGING PERFORMED BY

Dr. Gabriella Iannuzzi

## HOSPITAL NAME

Greater Staten Island  
Veterinary Service

## REFERRING VET

Dr. Gabriella Iannuzzi

## INVOICE

72559

## DATE

12/14/25

## PRESENTING CLINICAL SIGNS

Tula is a 14 yr FS DSH that presented to GSIVS on 12/13/25 for further evaluation of anorexia for the last few days O state P has been anorexic for the last 3 days and very lethargic- only sleeping, no interest in food or water NO v/d/c/s O have not witnessed Tula go to the litterbox Indoor only, NOT utd on vaccines

Abnormal PE/Chem/CBC/UA Results: PE: QAR - nervous, dehydrated, 4/9 BCS, SNP abdomen aside from enlarged bladder, hypertrichosis on abdomen Diagnostics: 12/14/25 Pancreatic lipase: 2.6 (0-4.4) BP @ 8 am: 98 mmHg BP post IVF bolus: 120 mmHg PCV/TP: 43%, 6.6 g/dL Brief ultrasound: subjectively thickened muscularis diffusely, mesenteric LN enlargement, hyperechoic cranial mesentery, unable to visualize spleen Full AUS: 12/13/25 CBC (initial - clotted): Retic 88.9 (3-50), nRBCs suspected, PLT 9 (151-600) Chemistry: within normal limits except Crea 2.0 mg/dL (0.8-2.4) and BUN 33 (16-36) CBC (2nd): Retic 55.3 (3-50), nRBCs suspected USG: >1.050 Urinalysis: USG 1.057, protein 1+, pH 6.5

## ULTRASONOGRAPHIC EXAMINATION OF THE ABDOMEN

### Urinary System

The urinary bladder, trigone, and pelvic urethra are unremarkable with normal wall thicknesses and normal tone. The ureters were not visualized, which is a normal finding. The bladder is adequately distended with anechoic urine and a mild amount of suspended echogenic debris. The ureteral papillae appear normal. There is no evidence of inflammatory, infiltrative, or neoplastic disease.

The kidneys are normal in size. The cortices are hyperechoic with a loss of corticomedullary distinction. The cortex to medulla ratio appears appropriate with no significant pyelectasia or pelvic dilation. The renal capsules are mildly irregular bilaterally. Left kidney measures 3.43 cm. Right kidney measures 2.96 cm.

### Adrenal Glands

The adrenal glands are not definitively visualized.

### Spleen

The spleen is not definitively visualized.

### Liver

The liver is subjectively normal liver size, contour, and structure. Parenchymal echogenicity is naturally coarse and hypoechoic to the spleen. Vasculature is within normal limits with no evidence of congestion. The gallbladder has thin walls which contain anechoic bile. There is no evidence of intra- or extra-hepatic biliary dilation. The cystic and common bile ducts were normal. No hepatic lymphadenopathy is documented. There is no overt structural evidence of inflammatory, infiltrative or regenerative pathology evident.

### Gastrointestinal

The stomach appears mildly distended with mildly echogenic fluid. The gastrointestinal walls are normal in wall thickness. The gastric mucosa is slightly irregular, and the pylorus and pyloroduodenal junction are patent and free of evidence of pyloric outflow obstruction. The small intestine has a diffusely



## PATIENT

Tula Cami

## SPECIES

Feline

## BREED

DSH

## SEX

Spayed Female

## AGE

14 Years

## WEIGHT

7.7 lbs

## INTERPRETED BY

Brad Harris, DVM,  
DACVECC, DACVIM  
(cardiology)

## IMAGING PERFORMED BY

Dr. Gabriella Iannuzzi

## HOSPITAL NAME

Greater Staten Island  
Veterinary Service

## REFERRING VET

Dr. Gabriella Iannuzzi

## INVOICE

72559

## DATE

12/14/25

prominent and irregular submucosal layer with a prominent and slightly thickened muscularis layer that distorts the normal 1:3 muscularis to mucosal ratio. There is no significant small intestinal dilation or shadowing material that would be concerning for a mechanical obstruction. The colon contains normal shadowing feces.

### **Pancreas**

The visible pancreas is isoechoic to surrounding omental fat. The pancreatic duct and capsular contour are normal. There is no overt evidence of active inflammatory or neoplastic disease.

### **Free Abdomen**

There are several prominent mesenteric lymph nodes with a normal length to width ratio and isoechoic parenchymal detail. There is regional hyperechoic mesentery or omental fat. No significant free peritoneal effusion noted.

## **ULTRASONOGRAPHIC FINDINGS**

- The urinary bladder contains echogenic, suspended debris contrasted with anechoic urine. This is often related to urinary tract infection but may represent exfoliated debris or sterile inflammation.
- The kidneys are relatively normal in size and structure, and cortex:medulla ratio (cortex 1/3 of medulla) is essentially maintained. There is age-related loss of the normal smooth capsular contour and C/M junction definition. The cortices are largely uniform in texture with mild hyperechogenicity expected for this patient's age. There is no evidence of pelvic dilation present.
- The intestinal submucosa is slightly irregular, thickened and hyperechoic suggestive of low grade, chronic disease. There is mild uniform prominence of the gastric mucosa as well as areas of "ropey" small intestinal wall with slight disruption of the normal 1:3 muscularis/mucosal ratio. This is most consistent with chronic enteropathy. No concerning lymphadenopathy or evidence of mechanical obstruction is present. Chronic inflammatory bowel disease is likely with a low possibility of an early neoplastic event such as lymphoma.
- The slightly prominent mesenteric lymph nodes display no loss of parenchymal detail or change in echogenicity. This is most consistent with reactive lymphadenitis or lymphatic hyperplasia.

## **INTERPRETATION OF THE FINDINGS & FURTHER RECOMMENDATIONS**

A urinalysis and urine culture via cystocentesis are recommended to evaluate the urinary tract changes for potential urinary tract infection.

A gastrointestinal panel (TLI, PLI, B12, folate) via Texas A&M gastrointestinal laboratory is indicated to further evaluate for potential chronic enteropathy. Ultimately, gastrointestinal biopsies may be required for a definitive diagnosis.



## PATIENT

Tula Cami

## SPECIES

Feline

## BREED

DSH

## SEX

Spayed Female

## AGE

14 Years

## WEIGHT

7.7 lbs

## INTERPRETED BY

Brad Harris, DVM,  
DACVECC, DACVIM  
(cardiology)

## IMAGING PERFORMED BY

Dr. Gabriella Iannuzzi

## HOSPITAL NAME

Greater Staten Island  
Veterinary Service

## REFERRING VET

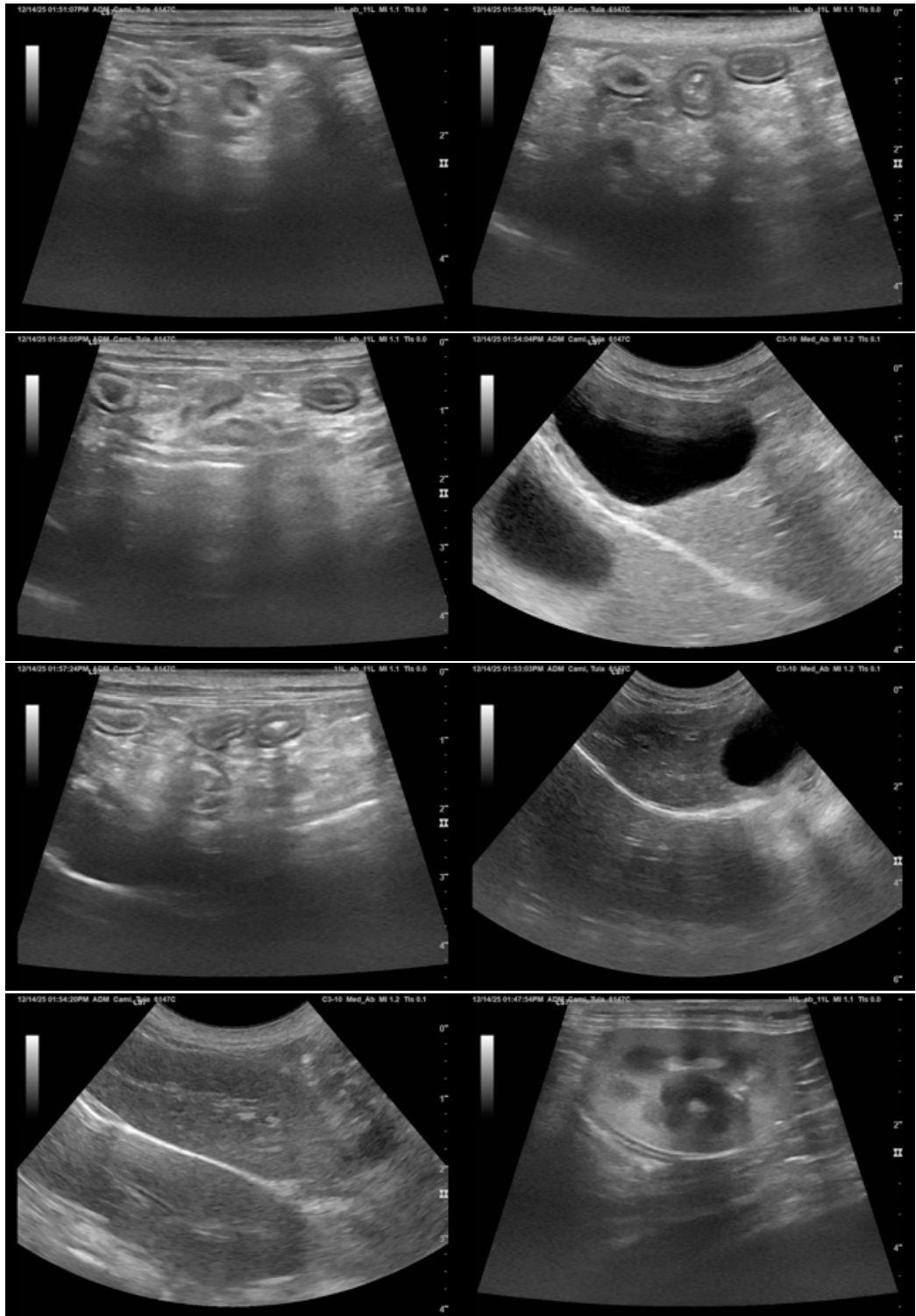
Dr. Gabriella Iannuzzi

## INVOICE

72559

## DATE

12/14/25





## PATIENT

Tula Cami

## SPECIES

Feline

## BREED

DSH

## SEX

Spayed Female

## AGE

14 Years

## WEIGHT

7.7 lbs

## INTERPRETED BY

Brad Harris, DVM,  
DACVECC, DACVIM  
(cardiology)

## IMAGING PERFORMED BY

Dr. Gabriella Iannuzzi

## HOSPITAL NAME

Greater Staten Island  
Veterinary Service

## REFERRING VET

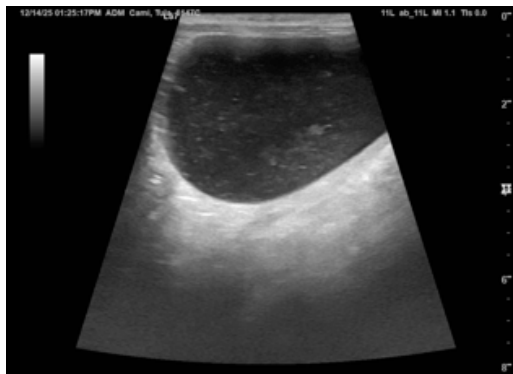
Dr. Gabriella Iannuzzi

## INVOICE

72559

## DATE

12/14/25



The information and recommendations provided are based on the images presented by the referring veterinarian/sonographer. No evaluation can be communicated regarding pathology that was not visible in the image/video clips provided.

Thank you for this referral. If the clinical or image interpretation does not parallel your findings or if I can be of any further assistance please contact me.

**Brad Harris, DVM, DACVECC, DACVIM (cardiology)**

[info@SonoPath.com](mailto:info@SonoPath.com)