



PATIENT

Milo Torrelli

SPECIES

Canine

BREED

Boston Terrier

SEX

Neutered Male

AGE

13 Years

WEIGHT

24.66 lbs

INTERPRETED BY

Brad Harris, DVM,
DACVECC, DACVIM
(cardiology)

IMAGING PERFORMED BY

Dr. Gabriella Iannuzzi

HOSPITAL NAME

Greater Staten Island
Veterinary Service

REFERRING VET

Dr. Gabriella Iannuzzi

INVOICE

72558

DATE

12/14/25

PRESENTING CLINICAL SIGNS

Milo is a 14 yr MC Boston Terrier that presented to GSIVS on 12/13/25 for further evaluation of hyporexia for 2 days Hyporexic for 2 days- only interested in some carrots and pineapple did vomit once yesterday after eating pineapple urinating defecating normally no coughing or sneezing Hx of bladder stones - cystotomy and neuter at RBVH several years ago

Abnormal PE/Chem/CBC/UA Results: PE: 4/6 HM, tired to bite on TL palpation - also uncomfortable on neck palpation, absent L hind CP, 7-8% dehydration yesterday today about 5% Polycythemia on BW 12/14/25 Brief ultrasound: enlarged bladder CBC: RBC 10.17 (5.65-8.87), HCT 70.8 % (37.3-61.7), Hgb 23.2 (13.1-20.5), nRBCs suspected Chemistry: Glu 78 (70-143), Chol 107 (110-320) PCV/TP: 59 %, 6.2 g/dL BG @ 8:30 am: 69 mg/dL - Corrected BG: 69 mg/dL + [(1.6-59%)-81.3] = 82.1 mg/dL PCV/TP: 59 %, 5.6 g/dL BP: 136 mmHg Pancreatic lipase: 293 (0-200) 12/13/25 CBC (prelim CBC): RBC 10.95 M/uL (H), HCT 77.2 % (H), HGB 25.1 g/dL (H), NEU 12.05 K/uL (H) Chemistry: ALT 149 (10-125) - BUN, PHOS, ALKP, GGT, Tbil, CHOL did not run due to hemoconcentration iSTAT: HCT 70%, Hb 23.8 g/dL- otherwise WNL BP: 90 mmHg PCV/TP: 69%, 7.2 g/dL

ULTRASONOGRAPHIC EXAMINATION OF THE ABDOMEN

Urinary System

The urinary bladder is adequately distended with anechoic urine. The apical portion of the bladder mucosa has several polypoid changes with otherwise normal wall thickness and layering. The trigonal region is patent and free of evident obstruction. The proximal urethra is patent and unremarkable. There are no uroliths or sediment identified. The ureteral papillae appear normal.

The kidneys are normal in size. The cortices are hyperechoic with a loss of normal corticomedullary distinction. There are numerous renal cortical cystic changes noted bilaterally, and the cortex to medullary ratio is appropriate with no evidence of pyelectasis or pelvic dilation. The renal capsules are irregular bilaterally. Left kidney measures 5.0 cm. Right kidney measures 6.02 cm.

Adrenal Glands

Both adrenal glands are visualized and have normal shape, size, position and echogenicity for this breed. The phrenic vasculature, glandular echogenicity and detail were unremarkable. Capsule, cortex, and medullary definition were normal for this age patient. Left measures 2.11 cm x 1.25 cm. It is distorted with a large mass effect at the caudal pole with heterogeneous parenchyma and lack of normal adrenal structure. There is evidence for capsular escape. However, no overt evidence of vascular invasion is identified. The right adrenal gland is normal. It measures 0.72 cm x 2.16 c.

Spleen

The spleen measures 0.94 cm at the hilus. It is smooth with homogeneous parenchyma and hyperechoic to liver and renal cortical parenchyma. The capsule is without noticeable irregularity or deformation. The splenic vasculature is normal without signs of congestion, spontaneous echo contrast, or thrombosis. No evidence of acute or chronic inflammatory, neoplastic, or infarct are documented.

Liver

The liver is subjectively enlarged and diffusely hyperechoic with numerous ill-defined hypoechoic nodules throughout that do not discretely distort the smooth and slightly rounded hepatic capsule. Vasculature is within normal limits with no evidence of congestion. The gallbladder contains a mild



PATIENT

Milo Torrelli

SPECIES

Canine

BREED

Boston Terrier

SEX

Neutered Male

AGE

13 Years

WEIGHT

24.66 lbs

INTERPRETED BY

Brad Harris, DVM,
DACVECC, DACVIM
(cardiology)

IMAGING PERFORMED BY

Dr. Gabriella Iannuzzi

HOSPITAL NAME

Greater Staten Island
Veterinary Service

REFERRING VET

Dr. Gabriella Iannuzzi

INVOICE

72558

DATE

12/14/25

amount of suspended echogenic debris and dependent sediment. There is no evidence of intra- or extra-hepatic biliary dilation. The cystic and common bile ducts were normal.

Gastrointestinal

The stomach is non-distended with overall normal wall thickness and layering. The region of the pylorus has a slightly thickened and prominent muscularis layer, but the remainder of the stomach and gastrointestinal tract wall appear within normal limits. The pyloroduodenal junction is patent and there is no evidence of pyloric outflow obstruction. There is no shadowing foreign material or concern for gastrointestinal obstruction. The colon contains normal shadowing feces.

Pancreas

The base and limbs of the pancreas are isoechoic to surrounding omental fat. The pancreatic duct and capsular contour are normal. There is no overt evidence of active inflammatory or neoplastic disease.

Free Abdomen

No overt lymphadenopathy or peritoneal effusion was present.

ULTRASONOGRAPHIC FINDINGS

- Chronic Cystitis - Urinary bladder wall changes are most consistent with chronic cystitis. Infiltrative neoplasia cannot be ruled out but is considered less likely given the location and diffuse nature of the changes.
- There is increased renal cortical echogenicity and thickening with a mildly irregular capsular contour. Multifocal cystic cortical changes are noted. This is secondary cystic formation consistent with chronic age related degeneration and remodeling. There is no evidence of abscessation or suspicion of neoplasia.
- The large, heterogeneous left adrenal mass may represent infiltrative neoplastic disease such as functional adenoma or pheochromocytoma. There is no evidence of vascular invasion identified.
- The diffuse hepatic changes are non-specific and could be consistent with vacuolar hepatopathy, nodular hyperplasia, inflammatory, immune-mediated, metabolic, or endocrine disease. Infiltrative neoplasia or acute hepatitis cannot be ruled out.
- The gallbladder contains echogenic, suspended and dependent unorganized debris. This is not yet to the level of an organized mucocele, however early/developing mucocele cannot be ruled out. This dependent sediment is often an incidental finding or may be associated with concurrent endocrine disease such as hyperadrenocorticism or diabetes mellitus.
- The thickened region of the pylorus may represent pyloric hypertrophy. However, this appears non-obstructive at this time, and its connection to the underlying clinical signs is unclear.

INTERPRETATION OF THE FINDINGS & FURTHER RECOMMENDATIONS

A urinalysis and urine culture via cystocentesis are recommended to evaluate the urinary tract changes for potential urinary tract infection.



PATIENT

Milo Torrelli

SPECIES

Canine

BREED

Boston Terrier

SEX

Neutered Male

AGE

13 Years

WEIGHT

24.66 lbs

INTERPRETED BY

Brad Harris, DVM,
DACVECC, DACVIM
(cardiology)

IMAGING PERFORMED BY

Dr. Gabriella Iannuzzi

HOSPITAL NAME

Greater Staten Island
Veterinary Service

REFERRING VET

Dr. Gabriella Iannuzzi

INVOICE

72558

DATE

12/14/25

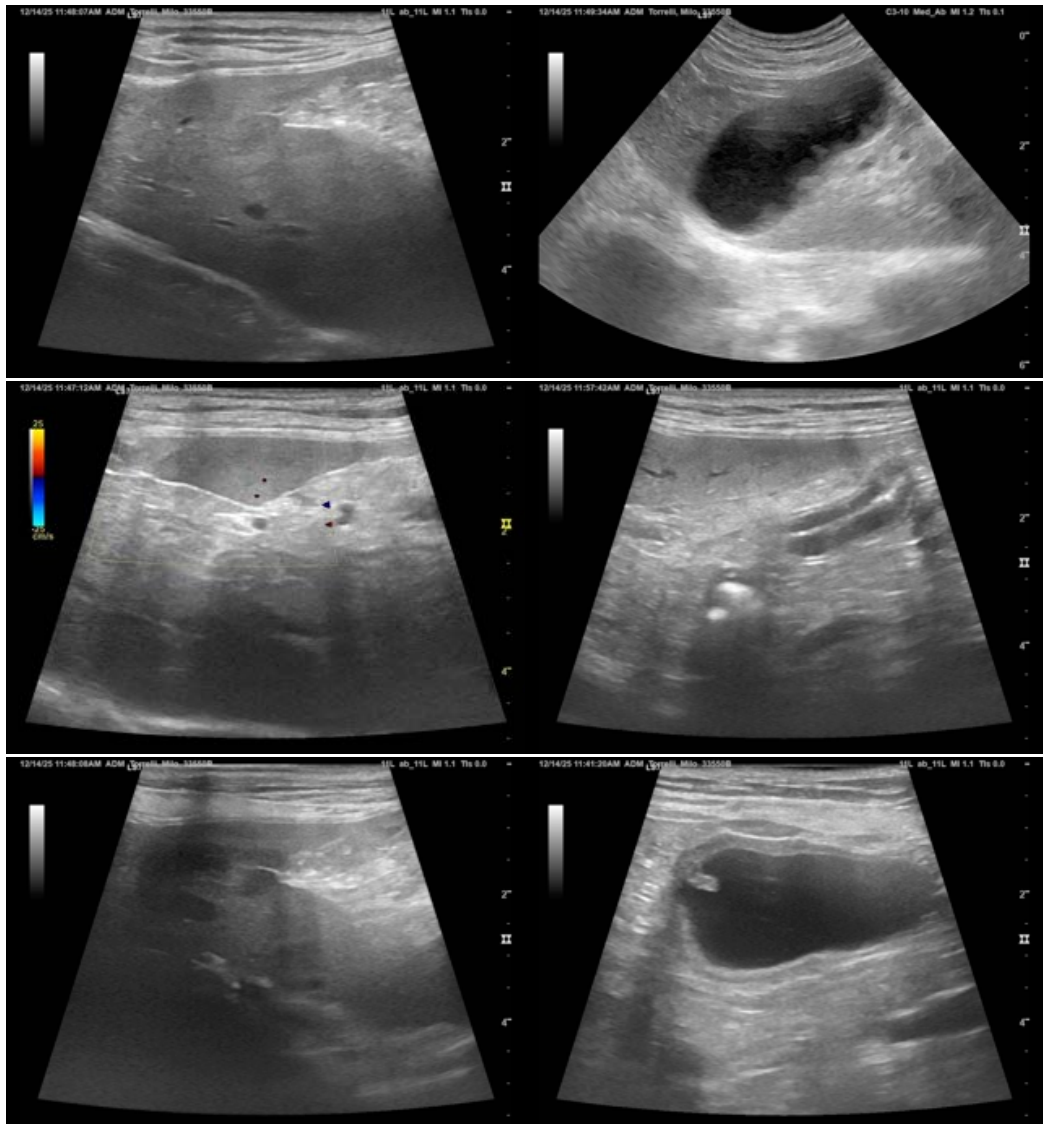
An ACTH stimulation test and low dose dexamethasone suppression test are indicated to evaluate for potential hyperadrenocorticism.

A urine normetanephrine panel is recommended to further evaluate for potential pheochromocytoma.

Fine needle aspirates of the liver with cytology are recommended. A coagulation profile and platelet estimate prior to sampling are indicated to ensure the absence of coagulopathy. Occasionally some tissues are poorly exfoliative, or cytology is non-specific, in which case biopsy with histopathology may be required for a definitive diagnosis.

A gastrointestinal panel (TLI, PLI, B12, folate) via Texas A&M gastrointestinal laboratory is indicated to further evaluate for potential chronic enteropathy. Ultimately, gastrointestinal biopsies may be required for a definitive diagnosis.

A cPLI is recommended to further evaluate the pancreas for occult inflammation or pancreatitis.





PATIENT

Milo Torrelli

SPECIES

Canine

BREED

Boston Terrier

SEX

Neutered Male

AGE

13 Years

WEIGHT

24.66 lbs

INTERPRETED BY

Brad Harris, DVM,
DACVECC, DACVIM
(cardiology)

IMAGING PERFORMED BY

Dr. Gabriella Iannuzzi

HOSPITAL NAME

Greater Staten Island
Veterinary Service

REFERRING VET

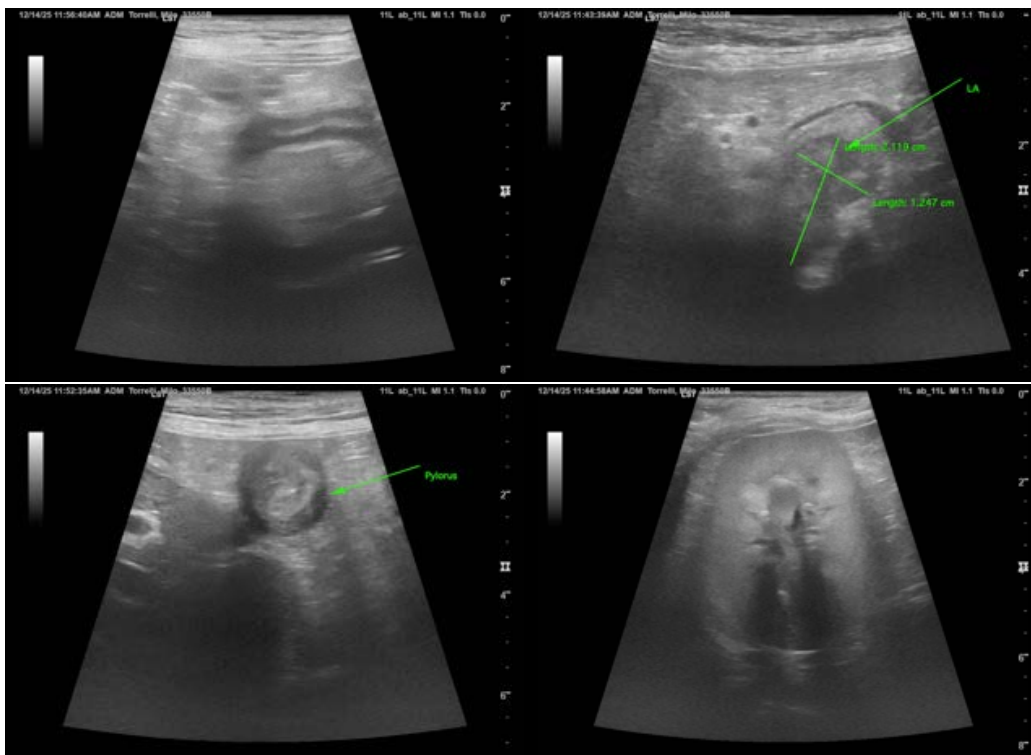
Dr. Gabriella Iannuzzi

INVOICE

72558

DATE

12/14/25



The information and recommendations provided are based on the images presented by the referring veterinarian/sonographer. No evaluation can be communicated regarding pathology that was not visible in the image/video clips provided.

Thank you for this referral. If the clinical or image interpretation does not parallel your findings or if I can be of any further assistance please contact me.

Brad Harris, DVM, DACVECC, DACVIM (cardiology)

info@SonoPath.com