



**PATIENT PRESENTING CLINICAL SIGNS**

**PATIENT** Tom Summers  
 Ongoing issues since 4/2025 starting with some weight loss and now progressed to decreased appetite. O noticed that Tom has been more lethargic and more vocal and crying more lately. Was given Convenia 11/12/25 and Depo Medrol 10/31/25.

**SPECIES**

**SPECIES** Feline  
 Abnormal PE/Chem/CBC/UA Results: Please see attached previous and most recent radiographs and lab results

**BREED**

**ULTRASONOGRAPHIC EXAMINATION OF THE ABDOMEN**

**DMH**

**Urinary System**

**SEX**

The urinary bladder contains a mild amount of suspended echogenic debris and anechoic urine. The bladder, trigone, and pelvic urethra are unremarkable with normal wall thicknesses and normal tone. The ureters were not visualized, which is a normal finding. The ureteral papillae appear normal. There is no evidence of inflammatory, infiltrative, or neoplastic disease.

**SEX** Neutered Male

**AGE**

The kidneys are normal in size and structure. The cortices are hyperechoic with a loss of normal corticomedullary definition. The cortex to medulla ratio appears normal with no pyelectasis or pelvic dilation. The renal capsules are minimally irregular bilaterally. The left kidney measures 4.25 cm. The right kidney measures 3.49 cm.

**AGE** 7 Years

**WEIGHT**

**Adrenal Glands**

**WEIGHT** 4.1 kg

Both adrenal glands are visualized and have normal shape, size, position and echogenicity for this breed. The phrenic vasculature, glandular echogenicity and detail were unremarkable. Capsule, cortex, and medullary definition were normal for this age patient. The left adrenal gland measures 0.55 cm. The right adrenal gland measures 0.30 cm.

**INTERPRETED BY**

Bradley Harris, DVM,  
 DACVECC, DACVIM  
 (cardiology)

**Spleen**

**IMAGING PERFORMED BY**

Crystal Hill

The spleen is prominent and thickened with a diffusely hypoechoic parenchyma. The capsule is smooth without significant irregularity or deformation. The splenic vasculature is normal without signs of congestion, spontaneous echo contrast, or thrombosis. There are no overt mass effects noted within the spleen. The spleen measures 1.39 cm at the hilus.

**HOSPITAL NAME**

Erin Folk AH

**Liver**

**REFERRING VET**

Dr. Soliman

The liver is subjectively normal liver size, contour, and structure. Parenchymal echogenicity is naturally coarse and hypoechoic to the spleen. Vasculature is within normal limits with no evidence of congestion. The gallbladder has thin walls which contain anechoic bile. There is no evidence of intra- or extra-hepatic biliary dilation. The cystic and common bile ducts were normal. No hepatic lymphadenopathy is documented. There is no overt structural evidence of inflammatory, infiltrative or regenerative pathology evident.

**INVOICE**

12296

**Gastrointestinal**

**DATE**

11/17/25

The stomach is nondistended and the pyloric outflow tract is patent without evidence of obstruction. The gastrointestinal wall is diffusely mildly thickened with a prominent muscularis layer that distorts the normal 1:3 muscularis to mucosal ratio. The small intestine is also nondistended with no shadowing foreign material or evidence of mechanical obstruction. The colon contains normal shadowing feces.



**PATIENT**

Tom Summers

**SPECIES**

Feline

**BREED**

DMH

**SEX**

Neutered Male

**AGE**

7 Years

**WEIGHT**

4.1 kg

**INTERPRETED BY**

Bradley Harris, DVM,  
 DACVECC, DACVIM  
 (cardiology)

**IMAGING PERFORMED BY**

Crystal Hill

**HOSPITAL NAME**

Erin Folk AH

**REFERRING VET**

Dr. Soliman

**INVOICE**

12296

**DATE**

11/17/25

**Pancreas**

The pancreas is irregular and prominent with slightly hypoechoic parenchymal echotexture. The abdominal mesentery is diffusely hyperechoic and irregular.

**Free Abdomen**

There are multiple mesenteric lymph nodes that are enlarged and have distorted length: width ratios with irregular contour. Normal parenchymal detail is not readily discernable, and the parenchyma is hypoechoic. There is a mass effect in the caudal abdomen near the urinary bladder that is suspected to be lymphatic in origin based on location, however, other etiology such as mesentery cannot be definitively ruled out. There is scant volume of free anechoic fluid noted.

**ULTRASONOGRAPHIC FINDINGS**

- The urinary bladder contains echogenic, suspended debris contrasted with anechoic urine. This is often related to urinary tract infection but may represent exfoliated debris or sterile inflammation.
- The kidneys are relatively normal in size and structure, and cortex:medulla ratio (cortex 1/3 of medulla) is essentially maintained. There is age-related loss of the normal smooth capsular contour and C/M junction definition. The cortices are largely uniform in texture with mild hyperechogenicity expected for this patient's age. There is no evidence of pelvic dilation present.
- The enlarged hypoechoic spleen coupled with other changes within the abdomen is concerning for infiltrative disease such as round cell neoplasia. This may also represent benign change such as reactive splenitis or lymphoid hyperplasia, however, this is considered less likely given concurrent abnormalities within the abdomen.
- The slightly thickened muscularis layer of the gastrointestinal tract is concerning for potential infiltrative disease. Inflammatory bowel disease or other chronic enteropathies are considered possibilities, however, infiltrative round cell neoplasia cannot be definitively ruled out.
- Changes to the pancreas likely represent a secondary inflammation or pancreatitis given the concurrent inflammation within the abdomen, however, infiltrative neoplastic disease must also be considered.
- The mesenteric lymph nodes presented abnormal length to width ratio with distorted, swollen, irregular contour. Parenchymal detail was indiscernible. This is most consistent with lymphoproliferative disease such as lymphoma/round cell neoplasia, metastatic disease, or an aggressive inflammatory process. FNA, cytology and culture are warranted.

**INTERPRETATION OF THE FINDINGS & FURTHER RECOMMENDATIONS**

A urinalysis and urine culture via cystocentesis are recommended to evaluate the urinary tract changes for potential urinary tract infection. Fine needle aspirates of the spleen and caudal abdominal mass/lymph node with cytology are recommended. A coagulation profile and platelet estimate prior to sampling are indicated to ensure the absence of coagulopathy. Occasionally some tissues are poorly exfoliative, or cytology is non-specific, in which case biopsy with histopathology may be required for a definitive diagnosis.



**PATIENT**

Tom Summers

**SPECIES**

Feline

**BREED**

DMH

**SEX**

Neutered Male

**AGE**

7 Years

**WEIGHT**

4.1 kg

**INTERPRETED BY**

Bradley Harris, DVM,  
 DACVECC, DACVIM  
 (cardiology)

**IMAGING PERFORMED BY**

Crystal Hill

**HOSPITAL NAME**

Erin Folk AH

**REFERRING VET**

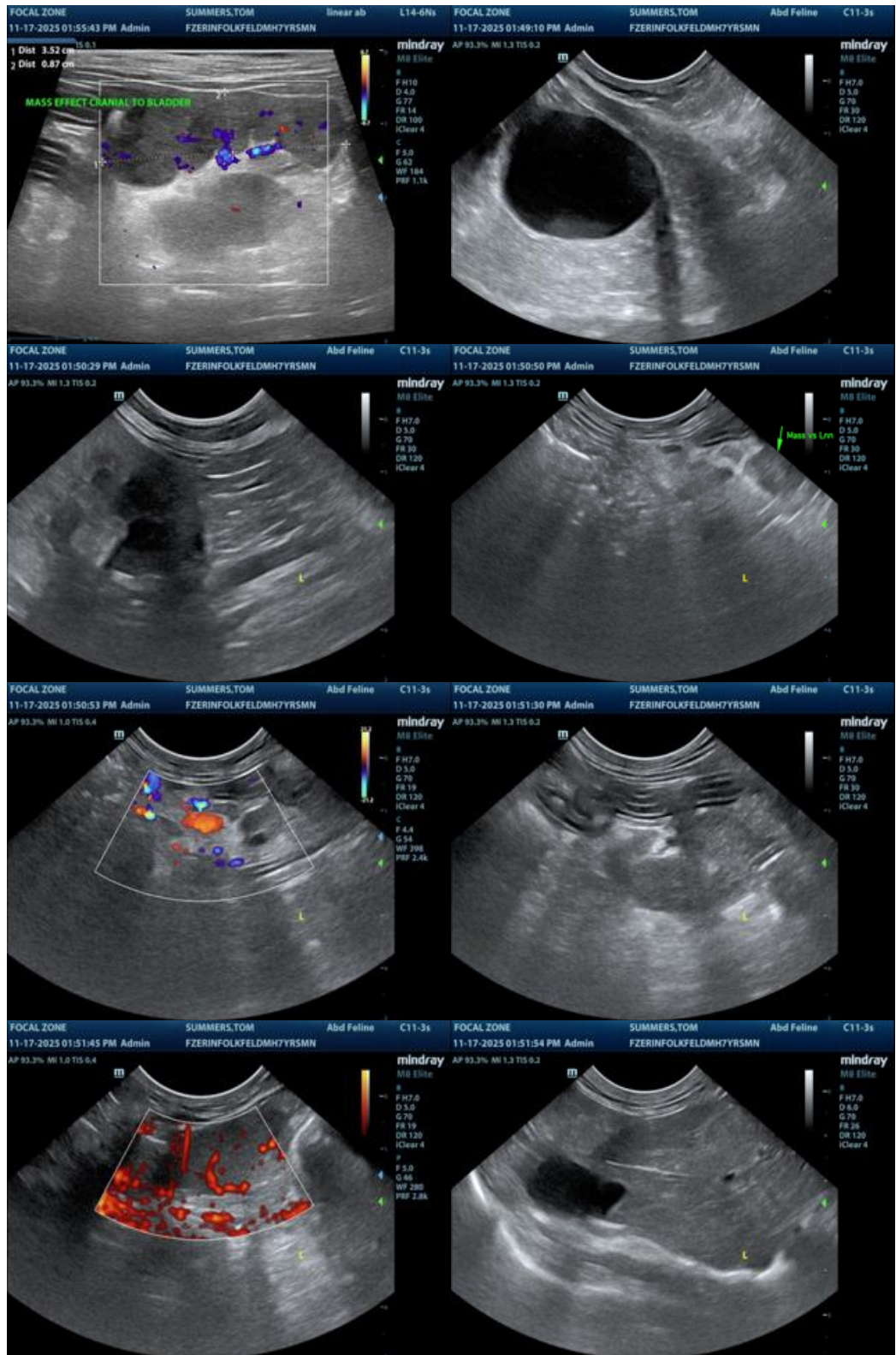
Dr. Soliman

**INVOICE**

12296

**DATE**

11/17/25





**PATIENT**

Tom Summers

**SPECIES**

Feline

**BREED**

DMH

**SEX**

Neutered Male

**AGE**

7 Years

**WEIGHT**

4.1 kg

**INTERPRETED BY**

Bradley Harris, DVM,  
 DACVECC, DACVIM  
 (cardiology)

**IMAGING PERFORMED BY**

Crystal Hill

**HOSPITAL NAME**

Erin Folk AH

**REFERRING VET**

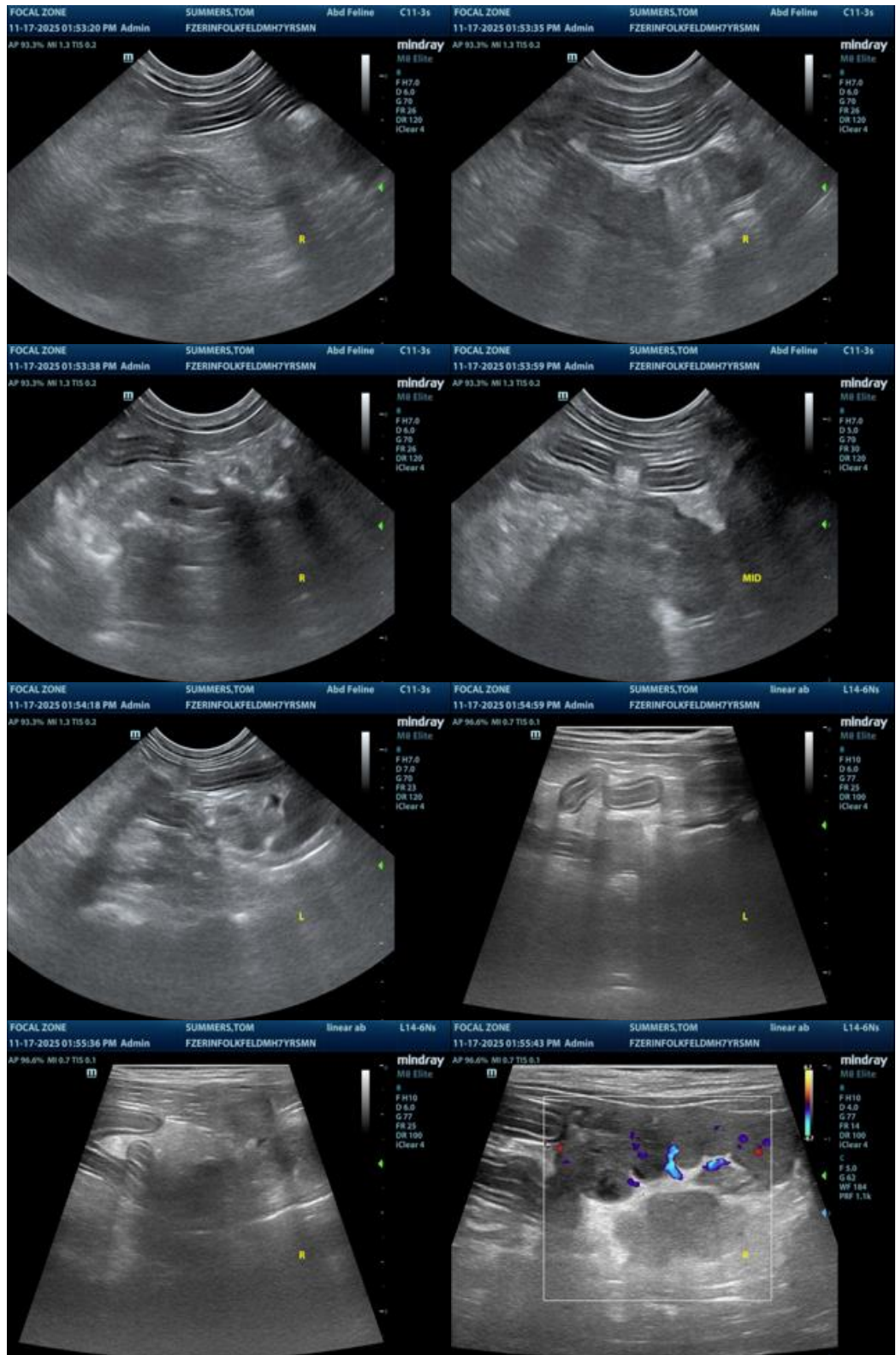
Dr. Soliman

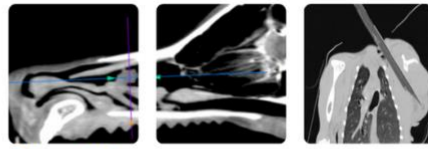
**INVOICE**

12296

**DATE**

11/17/25





**PATIENT**

Tom Summers

**SPECIES**

Feline

**BREED**

DMH

**SEX**

Neutered Male

**AGE**

7 Years

**WEIGHT**

4.1 kg

**INTERPRETED BY**

Bradley Harris, DVM,  
DACVECC, DACVIM  
(cardiology)

**IMAGING  
PERFORMED BY**

Crystal Hill

**HOSPITAL NAME**

Erin Folk AH

**REFERRING VET**

Dr. Soliman

**INVOICE**

12296

**DATE**

11/17/25

The information and recommendations provided are based on the images presented by the referring veterinarian/sonographer. No evaluation can be communicated regarding pathology that was not visible in the image/video clips provided.

Thank you for this referral. If the clinical or image interpretation does not parallel your findings or if I can be of any further assistance please contact me.

**Bradley Harris, DVM, DACVECC, DACVIM (cardiology)**

[info@SonoPath.com](mailto:info@SonoPath.com)