



PATIENT

Cody Reinhart

SPECIES

Canine

BREED

Husky

SEX

Neutered Male

AGE

12 Years

WEIGHT

36.5 kg

INTERPRETED BY

Brad Harris, DVM,
DACVECC, DACVIM
(cardiology)

IMAGING PERFORMED BY

Kelly Reschny

HOSPITAL NAME

Grand River Veterinary
Hospital

REFERRING VET

Dr. Day

INVOICE

72981

DATE

1/6/26

PRESENTING CLINICAL SIGNS

Diagnosis Lipomas likely Panting - worried about heart, pulmonary hypertension? (hx of heartworm disease) Weight loss - heart dz, neoplasia, other? See emailed medical DAP Current Medications Metacam & Simparica Trio

Abnormal PE/Chem/CBC/UA Results: Labs and rads attached.

ULTRASONOGRAPHIC EXAMINATION OF THE HEART & ABDOMEN

| CANINE CARDIAC PARAMETERS | BW | HR BPM | LAD 4 ch Long | RAD 4 ch Long | La/Ao Heart Base | LVIDd | LVIDs |
|---------------------------|-------|--------|----------------|------------------|------------------|---------|----------------------------------|
| NORMAL PARAMETER | | 50-100 | | | <1.6 | | |
| PATIENT | 16.59 | 100 | 3.99 | 2.37 | 1.09 | 3.48 | 2.23 |
| CANINE CARDIAC PARAMETERS | FS | EPSS | PV V MAX (m/s) | AV V Max (m/sec) | MR Vmax | TR Vmax | RPA distensibility (normal >30%) |
| NORMAL PARAMETER | 28-40 | <0.6 | 0.7-1.6 | 0.7-1.7 | 4.5-5.5 | < 2.7 | |
| PATIENT | 36 | 0.5 | 0.7 | 1.0 | 5.7 | 1.3 | NM |

Cardiac Presentation

The left atrium is normal in dimension. The left ventricle is normal in dimension, with normal systolic function. The right atrium and ventricle are normal in dimension, with normal systolic function. The mitral valve is thickened and redundant consistent with myxomatous changes, and there is minimal prolapse. There is evidence of mild mitral regurgitation. The tricuspid valve leaflets are minimally thickened with mild tricuspid regurgitation and no evidence of pulmonary hypertension. The left ventricular outflow tract demonstrated normal laminar flow and the visible aorta is unremarkable. The right ventricular outflow tract assessment revealed normal laminar flow, and appropriate diameter and distensibility. There is no pulmonic and no aortic valve insufficiency identified. There is no visible pericardial, pleural, or free peritoneal fluid documented. No evidence of hepatic venous congestion is noted. The cardiac chambers, pericardial and visible extra-cardiac regions were free of masses, spontaneous echo contrast, or thrombi.

Urinary System

The urinary bladder, trigone, and pelvic urethra are unremarkable with normal wall thicknesses and normal tone. The ureters were not visualized, which is a normal finding. There are no uroliths or sediment noted, and anechoic urine is present. The ureteral papillae appear normal. There is no evidence of inflammatory, infiltrative, or neoplastic disease.



PATIENT

Cody Reinhart

The kidneys are normal in size. The cortices are hyperechoic with a slight decrease in corticomedullary definition. Cortex to medulla ratio is normal. No pyelectasis or pelvic dilation. The renal capsules are mildly irregular bilaterally. Left kidney measures 6.26 cm. Right kidney measures 7.75 cm.

SPECIES

Canine

Adrenal Glands

Both adrenal glands are visualized and have normal shape, size, position and echogenicity for this breed. The phrenic vasculature, glandular echogenicity and detail were unremarkable. Capsule, cortex, and medullary definition were normal for this age patient. Left measures 0.54 cm x 2.35 cm. Right measures 0.57 cm x 2.28 cm.

BREED

Husky

Spleen

SEX

Neutered Male

The spleen measures 2.15 cm at the hilus. It is smooth with homogeneous parenchyma and hyperechoic to liver and renal cortical parenchyma. The capsule is without noticeable irregularity or deformation. The splenic vasculature is normal without signs of congestion, spontaneous echo contrast, or thrombosis. No evidence of acute or chronic inflammatory, neoplastic, or infarct are documented.

AGE

12 Years

Liver

WEIGHT

36.5 kg

The liver is subjectively normal liver size, contour, and structure. Parenchymal echogenicity is naturally coarse and hypoechoic to the spleen. Vasculature is within normal limits with no evidence of congestion. The gallbladder has thin walls and contains a mild amount of suspended echogenic debris and dependent sediment. It otherwise contains normal anechoic bile. There is no evidence of intra- or extra-hepatic biliary dilation. The cystic and common bile ducts were normal.

INTERPRETED BY

Brad Harris, DVM,
 DACVECC, DACVIM
 (cardiology)

Gastrointestinal

The stomach and intestines are free of stasis and peristaltic activity, with no significant dilation noted. There is normal wall thickness and acceptable curvilinear mural detail. The pyloric-duodenal junction and ileocecolic junction are patent, and the colon contains normal shadowing feces. There is no evidence of shadowing obstructive material or overt infiltrative disease noted. No associated abnormal lymphatic activity is documented.

IMAGING PERFORMED BY

Kelly Reschny

Pancreas

HOSPITAL NAME

Grand River Veterinary
 Hospital

The base and limbs of the pancreas are isoechoic to surrounding omental fat. The pancreatic duct and capsular contour are normal. There is no overt evidence of active inflammatory or neoplastic disease.

REFERRING VET

Dr. Day

Free Abdomen

No overt lymphadenopathy or peritoneal effusion was present.

INVOICE

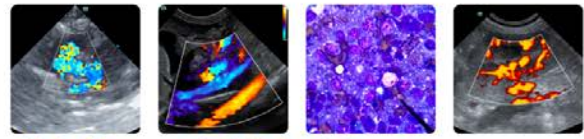
72981

ULTRASONOGRAPHIC FINDINGS

- The cardiac findings are consistent with degenerative/myxomatous mitral valve disease with minimal to mild hemodynamic effects consistent with ACVIM Stage B1 disease. It is unlikely that any current morbidity is of cardiac origin.
- The kidneys are relatively normal in size and structure, and cortex:medulla ratio (cortex 1/3 of medulla) is essentially maintained. There is age-related loss of the normal smooth capsular contour and C/M junction definition. The cortices are largely uniform in texture with mild hyperechogenicity expected for this patient's age. There is no evidence of pelvic dilation

DATE

1/6/26



PATIENT

Cody Reinhart

SPECIES

Canine

BREED

Husky

SEX

Neutered Male

AGE

12 Years

WEIGHT

36.5 kg

INTERPRETED BY

Brad Harris, DVM,
 DACVECC, DACVIM
 (cardiology)

IMAGING PERFORMED BY

Kelly Reschny

HOSPITAL NAME

Grand River Veterinary
 Hospital

REFERRING VET

Dr. Day

INVOICE

72981

DATE

1/6/26

present.

- The gallbladder contains echogenic, suspended and dependent unorganized debris. This is not yet to the level of an organized mucocele, however early/developing mucocele cannot be ruled out. This dependent sediment is often an incidental finding or may be associated with concurrent endocrine disease such as hyperadrenocorticism or diabetes mellitus.

INTERPRETATION OF THE FINDINGS & FURTHER RECOMMENDATIONS

There is no overt underlying etiology for the reported clinical signs noted on this study. If there are additional signs consistent with hyperadrenocorticism, consider an ACTH stimulation test and low dose dexamethasone suppression test to evaluate for potential hyperadrenocorticism.

A gastrointestinal panel (TLI, PLI, B12, folate) via Texas A&M gastrointestinal laboratory is indicated to further evaluate for potential chronic enteropathy. Ultimately, gastrointestinal biopsies may be required for a definitive diagnosis.

Cardiac Recommendations:

Given these findings, no cardiac therapy is recommended. There are no cardiac contraindications to anesthesia, fluid therapy, vasopressor therapy, or corticosteroids as indicated for further assessment and treatment. If not already performed, baseline thoracic radiographs and blood pressure are recommended. A recheck echocardiogram is recommended in 6 months.

Anesthesia considerations:

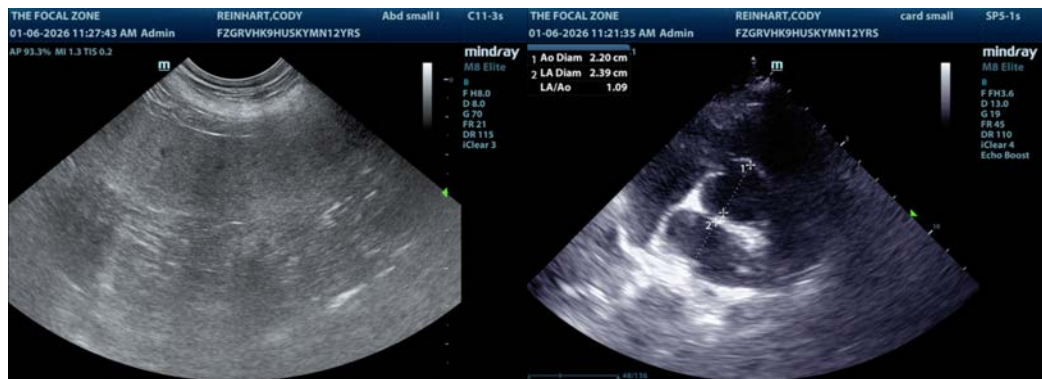
If anesthesia is necessary, alpha-2 agonists, ketamine, high dose acepromazine, and Telazol should be avoided. Fluid therapy during anesthesia should be considered at a conservative rate (e.g., 5 ml/kg/hour) if possible.

Diet:

A high-quality food from Hills, Royal Canin, Science Diet, Eukanuba, Iams, or Purina that is highly palatable with adequate protein and calories for maintaining optimal body condition is reasonable.

Activity:

No special considerations are necessary.





PATIENT

Cody Reinhart

SPECIES

Canine

BREED

Husky

SEX

Neutered Male

AGE

12 Years

WEIGHT

36.5 kg

INTERPRETED BY

Brad Harris, DVM,
 DACVECC, DACVIM
 (cardiology)

IMAGING PERFORMED BY

Kelly Reschny

HOSPITAL NAME

Grand River Veterinary
 Hospital

REFERRING VET

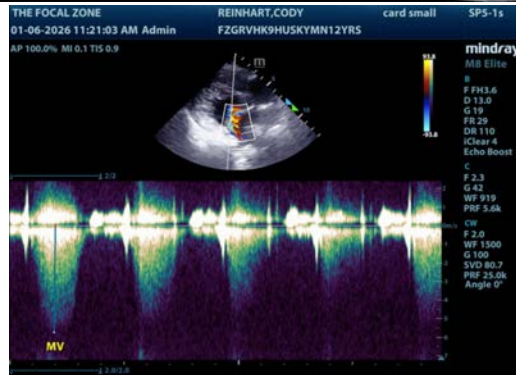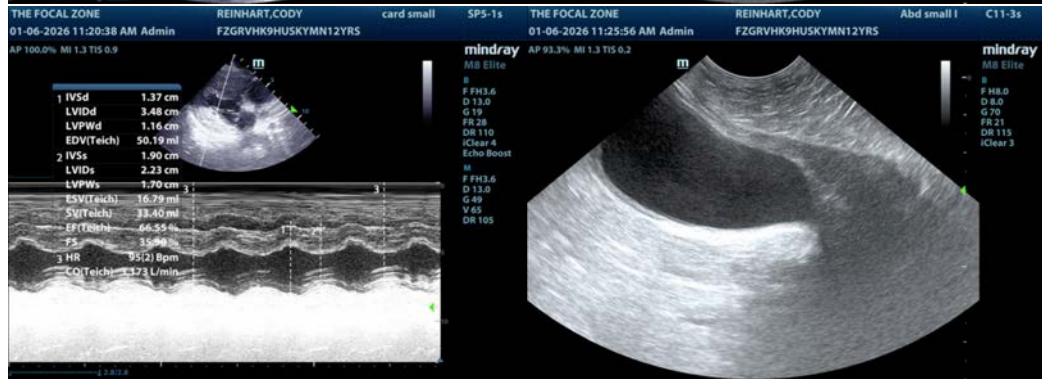
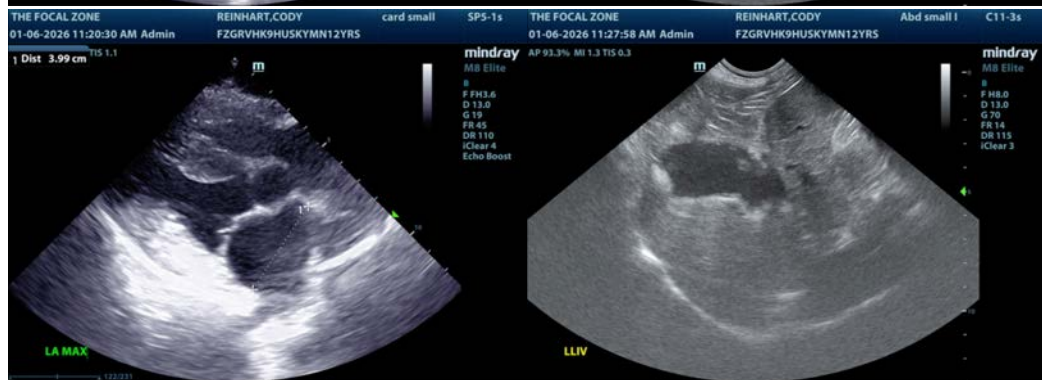
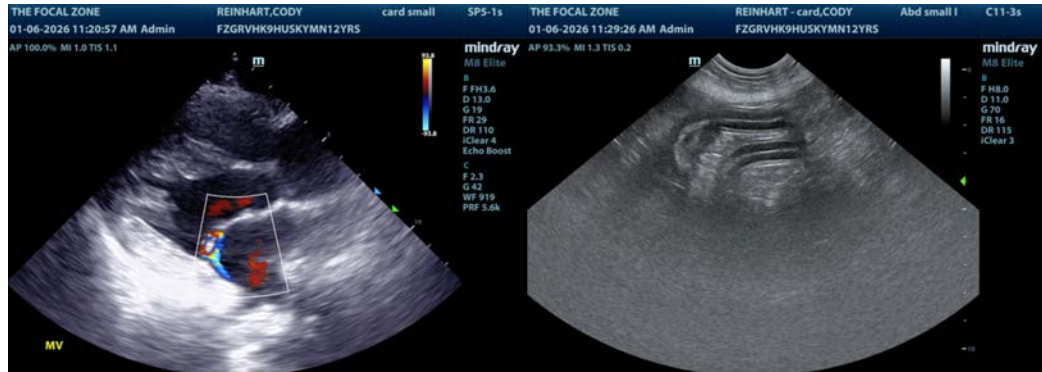
Dr. Day

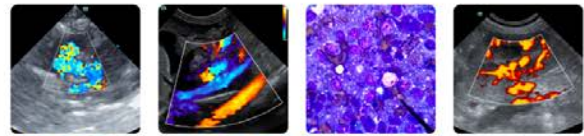
INVOICE

72981

DATE

1/6/26





PATIENT

Cody Reinhart

SPECIES

Canine

BREED

Husky

SEX

Neutered Male

AGE

12 Years

WEIGHT

36.5 kg

INTERPRETED BY

Brad Harris, DVM,
DACVECC, DACVIM
(cardiology)

**IMAGING
PERFORMED BY**

Kelly Reschny

HOSPITAL NAME

Grand River Veterinary
Hospital

REFERRING VET

Dr. Day

INVOICE

72981

DATE

1/6/26

The information and recommendations provided are based on the images presented by the referring veterinarian/sonographer. No evaluation can be communicated regarding pathology that was not visible in the image/video clips provided.

Thank you for this referral. If the clinical or image interpretation does not parallel your findings or if I can be of any further assistance please contact me.

Brad Harris, DVM, DACVECC, DACVIM (cardiology)

info@SonoPath.com